




Recurrent Case of a Rare and Devastating Entity: Harlequin Ichthyosis

 Ayşegül ALKILIÇ^a,
 Özgür KAN^b,
 Elif Nazlı ÇETİNDAG AYDIN^c

^aDepartment of Obstetrics and Gynecology, TOBB University Faculty of Medicine, Ankara, TURKEY

^bDepartment of Obstetrics and Gynecology, Hitit University Faculty of Medicine, Çorum, TURKEY

^cClinic of Obstetrics and Gynecology, Yenimahalle Training and Research Hospital, Ankara, TURKEY

Received: 27.07.2018

Received in revised form: 30.11.2018

Accepted: 30.11.2018

Available online: 27.12.2018

Correspondence:

Ayşegül ALKILIÇ
 TOBB University Faculty of Medicine,
 Department of Obstetrics and Gynecology,
 Ankara, TURKEY
 aysegulalkilic@yahoo.com

ABSTRACT Harlequin ichthyosis (HI) is a rare and severe form of congenital ichthyosis caused by truncating mutations in the ABCA12 gene. Although it has many distinctive signs on perinatal sonography such as short limbs, wide gaping mouth, joint contractures, edema of the hands and feet and cloudy amniotic fluids, it usually can not be diagnosed until birth. Herein, we report a case of recurrent HI, which remained undiagnosed until labor at 38 weeks of gestational age. A multiparous woman presented to hospital at 38th weeks of gestation. There were no personal or family history. Vaginal delivery was performed and a 3300 gram baby was delivered. The body of the neonate was covered with thick, armor like skin, have generalized edema and erythematous fissures, scanty hair, everted eyelids with exposed swollen conjunctiva, open mouth were noted at the first examination. Newborn was diagnosed to be having Harlequin ichthyosis and was given to neonatal intensive care unit (NICU) for supportive care and additional examination. Genetic counseling is important and should be recommended to affected families. With the growing technology electron microscopes, invasive prenatal diagnostic tools and 3D sonography may reveal suggestive features of the disease. In addition, new treatment regimens, experienced and competent NICU facilities may increase survival rates.

Keywords: Harlequin type ichthyosis; ichthyosis

Harlequin ichthyosis (HI) is a rare and severe form of congenital ichthyosis caused by truncating mutations in the ABCA12 gene.¹ Mutation of this gene causes defective intracellular lipid deposition within the stratum corneum layer and extreme hyperkeratosis.² Although it has many distinctive signs on perinatal sonography such as short limbs, wide gaping mouth, joint contractures, edema of the hands and feet and cloudy amniotic fluids, it usually can not be diagnosed until birth. Herein, we report a case of recurrent HI, which remained undiagnosed until labor at 38 weeks of gestational age.

CASE REPORT

A 26-year-old multiparous woman presented to hospital emergency department with regular contractions and labor pains at 38th weeks of gestation according to her last menstrual period. She had previously one pregnancy with history of harlequin ichthyosis and lost her baby in the first month after delivery due to dehydration and infection. In this pregnancy, patient did not accept prenatal diagnostic tools to early detection

due to religious concerns. There were no personal or family history of any chronic illness or teratogenic exposure and the couple was noncon-sanguineous.

Vaginal delivery was performed and a 3300 gram, 50 cm female baby was delivered. The body of the neonate was covered with thick, armor like skin, have generalized edema and erythematous fissures, scanty hair, everted eyelids with exposed swollen conjunctiva, open mouth were noted at the first examination (Figure 1). The limbs were in flexion position and mobility of neonate was restricted. Her hands and feet were edematous with contracted digits. Newborn was diagnosed to be having Harlequin ichthyosis and was given to neonatal intensive care unit for supportive care and additional examination.

Informed consent was obtained from the patient before enrollment in the study.

DISCUSSION

Harlequin ichthyosis (HI) is an extremely rare and devastating dermatological condition with an estimated incidence of 1 in 300.000 births.³ It is the most severe type of inherited ichthyosis and arises secondarily to mutations in the ABCA12 gene.⁴ Lack of ABCA12 function leads to disruption of lamellar granule lipid transport in keratinizing keratinocytes of the upper epidermis.⁵ Owing to these gene defect and impairment of the skin barrier, affected newborns have thickened, generalized dry skin, scaling and hyperkeratosis. Major phenotypic signs of harlequin ichthyosis includes facial dysmorphism, eclabium, fish-like open mouth,

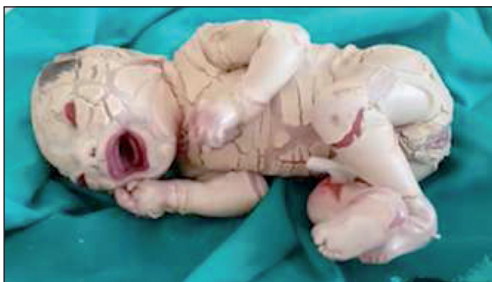

FIGURE 1: 3300 gram, 50 cm female baby with Harlequin baby; 5 minutes after vaginal delivery.

ectropion, restricted fetal movement with stiff limbs in a semiflexed position, limb abnormalities with hypoplastic fingers, short phalanges, clubfoot, shriveled hands and armor-like skin.

Prenatal diagnosis with chorionic villus sampling (CVS) and amniotic fluid cells analysis are advised in women with previous history of ichthyosis. After defining the causative gene defect, skin biopsy is not currently recommended for prenatal diagnosis.² Antenatal USG, especially 3D sonography is another modality of prenatal diagnosis but late phenotypic expression of the disease poses a challenge for timely detection and further management.⁶ In addition, preimplantation genetic diagnosis (PGD) is a feasible option especially in recurrent cases to select unaffected embryos accurately.⁷

Newborns with HI should be followed up in neonatal intensive care units. Appropriate intravenous fluid replacement, frequently moistening the skin, close monitoring and creating a sterile environment to avoid infections are the key points in treatment. Neonates are frequently lost in the first days of life because of severe fluid loss, disruption of heat balance and sepsis.⁸ In addition to palliative treatment, early systemic retinoid treatment has been shown to decrease mortality rates in patients with HI due to facilitating desquamation of the membranes.^{9,10} With adding retinoids to regular supportive therapy, long-term survival rates sharply increased.¹¹

In conclusion, genetic counseling is important and should be recommended to affected families. With the growing technology electron microscopes, invasive prenatal diagnostic tools and 3D sonography may reveal suggestive features of the disease. In addition, new treatment regimens, experienced and competent NICU facilities may increase survival rates.

Source of Finance

During this study, no financial or spiritual support was received neither from any pharmaceutical company that has a direct connection with the research subject, nor from a company that provides or produces medical instruments and materials which may negatively affect the evaluation process of this study.

Conflict of Interest

No conflicts of interest between the authors and / or family members of the scientific and medical committee members or members of the potential conflicts of interest, counseling, expertise, working conditions, share holding and similar situations in any firm.

Authorship Contributions

Idea/Concept: Ayşegül Alkılıç; **Design:** Ayşegül Alkılıç; **Control/Supervision:** Özgür Kan; **Data Collection and/or Processing:** Elif Nazlı Çetindağ Aydın; **Analysis and/or Interpretation:** Ayşegül Alkılıç; **Literature Review:** Ayşegül Alkılıç, Özgür Kan; **Writing the Article:** Ayşegül Alkılıç, Özgür Kan; **Critical Review:** Elif Nazlı Çetindağ Aydın; **References and Fundings:** Elif Nazlı Çetindağ Aydın, Özgür Kan; **Materials:** Elif Nazlı Çetindağ Aydın, Ayşegül Alkılıç.

REFERENCES

- Pet MA, Gupta D, Tse RW. Harlequin ichthyosis: a surgical perspective. *Pediatr Dermatol.* 2016;33(5):e327-32. [[Crossref](#)] [[PubMed](#)]
- Ahmed H, O'Toole EA. Recent advances in the genetics and management of harlequin ichthyosis. *Pediatr Dermatol.* 2014;31(5):539-46. [[Crossref](#)] [[PubMed](#)]
- Judge MR, McKean WH, Munro CS. Disorders of keratinization. In: Burns T, Breathnach SM, Cox N, Griffiths CE, eds. *Rook's Textbook of Dermatology.* 7th ed. Massachusetts: Wiley-Blackwell; 2004. p.34.23-34.25.
- Hovnanian A. Harlequin Ichthyosis unmasked: a defect of lipid transport. *J Clin Invest.* 2005;115(7):1708-10. [[Crossref](#)] [[PubMed](#)] [[PMC](#)]
- Akiyama M, Sugiyama-Nakagiri Y, Sakai K, McMillan JR, Goto M, Arita K, et al. Mutations in lipid transporter ABCA12 in harlequin ichthyosis and functional recovery by corrective gene transfer. *J Clin Invest.* 2005;115(7):1777-84. [[Crossref](#)] [[PubMed](#)] [[PMC](#)]
- Basgul AY, Kavak ZN, Guducu N, Durukan B, Isci H. Prenatal diagnosis of congenital harlequin ichthyosis with 2D, 3D, and 4D ultrasonography. *Clin Exp Obstet Gynecol.* 2011;38(3):283-5.
- Shimizu H, Suzumori K. Prenatal diagnosis as a test for genodermatoses: its past, present and future. *J Dermatol Sci.* 1999;19(1):1-8. [[Crossref](#)]
- Akiyama M. The pathogenesis of severe congenital ichthyosis of the neonate. *J Dermatol Sci.* 1999;21(2):96-104. [[Crossref](#)]
- Akiyama M, Sakai K, Sugiyama-Nakagiri Y, Yamanaka Y, McMillan JR, Sawamura D, et al. Compound heterozygous mutations including a de novo missense mutation in ABCA12 led to a case of harlequin ichthyosis with moderate clinical severity. *J Invest Dermatol.* 2006;126(7):1518-23. [[Crossref](#)] [[PubMed](#)]
- Takeichi T, Sugiura K, Matsuda K, Kono M, Akiyama M. Novel ABCA12 splice site deletion mutation and ABCA12 mRNA analysis of pulled hair samples in harlequin ichthyosis. *J Dermatol Sci.* 2013;69(3):259-61. [[Crossref](#)] [[PubMed](#)]
- Rajpopat S, Moss C, Mellerio J, Vahlquist A, Gånemo A, Hellstrom-Pigg M, et al. Harlequin ichthyosis: a review of clinical and molecular findings in 45 cases. *Arch Dermatol.* 2011;147(6):681-6. [[Crossref](#)] [[PubMed](#)]