

## CASE REPORT

DOI: 10.5336/caserep.2024-101428

# Computed Tomography Findings of Amyloid Goiter in a Patient with Familial Mediterranean Fever

Vefa ÇAKMAK<sup>a</sup>, Duygu HEREK<sup>a</sup>, Pınar ÇAKMAK<sup>a</sup><sup>a</sup>Pamukkale University Faculty of Medicine, Department of Radiology, Denizli, Türkiye

**ABSTRACT** Amyloid goiter is a rare clinical aspect and is detected as amyloid accumulation in the thyroid gland, fat cell infiltration and enlargement of the gland. It is a benign disease with findings consistent with diffuse lipomatosis of the thyroid gland on radiological imaging. It can be seen especially in patients with secondary amyloidosis such as familial mediterranean fever (FMF) with kidney involvement. In this case report, we aimed to present computed tomography images of a 53-year-old patient with amyloid goiter with a history of renal transplantation and FMF. The enlarged thyroid gland has symptoms of tracheal and esophageal compression, and imaging is performed to rule out malignant processes due to its progressive growth. Amyloid goiter and thyrolipomatosis are intertwined diagnoses, and the presence of amyloidosis histopathologically supports the diagnosis of amyloid goiter.

**Keywords:** Amyloid goiter; computed tomography; thyrolipomatosis; familial Mediterranean fever

Thyrolipomatosis is a benign condition called diffuse fat infiltration of the thyroid gland on computed tomography (CT).<sup>1</sup> Benign lesions containing fat in the thyroid gland are amyloid goiter, adenomatous nodule, lymphocytic thyroiditis, while papillary and follicles may contain fat in carcinoma. Thyrolipoma is classified as a variant subtype of follicular adenoma and is one of the fat-containing lesions of the thyroid.<sup>2,3</sup> Amyloid goiter, on the other hand, is the accumulation of fat-amyloid in the gland parenchyma and an increase in size in the gland.<sup>4</sup> In amyloid goiter, compression symptoms may occur due to the enlargement of the thyroid gland due to amyloid accumulation. Due to diffuse fat infiltration, ultrasound shows an increase in diffuse echogenicity with the growth of the thyroid gland and the same as adipose tissue.<sup>5</sup> Amyloid goiter is usually detected as diffuse fat infiltration in the thyroid gland on CT or magnetic resonance image (MRI) performed for differential diagnosis.<sup>4,6</sup> In this case report, we aimed to

discuss the CT findings and amyloid goiter of a patient with renal transplantation and a history of familial Mediterranean fever (FMF).

## CASE REPORT

A 53-year-old male patient with FMF and renal transplant history was admitted to nephrology department of our hospital. The hematology service for treatment and staging due to acute myeloid leukemia (AML). It was learned that the patient complained of difficulty swallowing and had undergone renal transplantation from a living donor 19 years ago due to amyloid-related glomerulonephritis in her family history. On physical examination, a diffuse soft mass was palpated in the thyroid locality, and no lymphadenopathy was detected. Laboratory examination revealed thyroid-stimulating hormone 0.411 mU/L (0.27-4.2), FT4 1.6 ng/dL (0.97-1.65) and FT3 2.65 µg/mL (2.59-4.26), excluding hematologic abnormalities.

**Correspondence:** Vefa ÇAKMAK

Pamukkale University Faculty of Medicine, Department of Radiology, Denizli, Türkiye

**E-mail:** vefacakm1408@gmail.com

Peer review under responsibility of Türkiye Klinikleri Journal of Case Reports.

**Received:** 15 Jan 2024

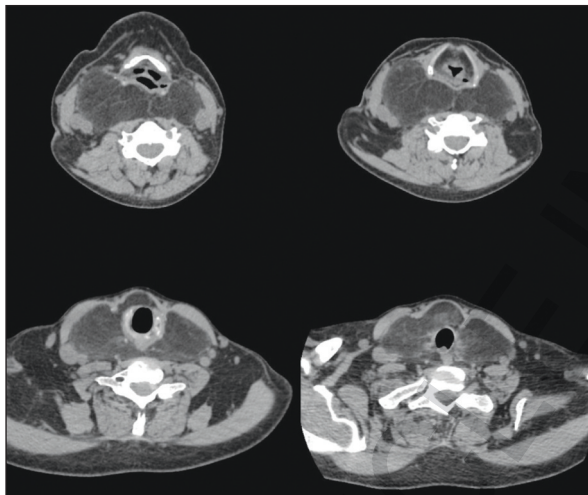
**Accepted:** 09 Jul 2024

**Available online:** 12 Aug 2024

2147-9291 / Copyright © 2024 by Türkiye Klinikleri. This is an open access article under the CC BY-NC-ND license (<http://creativecommons.org/licenses/by-nc-nd/4.0/>).



Thyroid antibodies were found to be negative. Neck ultrasonography revealed an abnormal increase in thyroid gland size, retrosternal extension and enlarged thyroid parenchyma echogenicity. There was no nodule in the thyroid parenchyma or pathologically enlarged lymph nodes in the neck. Diffuse fat infiltration was observed in the entire thyroid gland in non-contrast neck CT obtained after ultrasound findings, and a massive increase in thyroid gland size was observed (Figure 1). Thyroid gland parenchyma density was measured  $\sim -65$  Hounsfield unit (HU). The enlarged thyroid gland extends to the retrosternal area in the inferior gland and to the retropharyngeal area at the level of the oropharynx in the superior (Figure 2). It also led to repulsion of the hypopharyngeal-

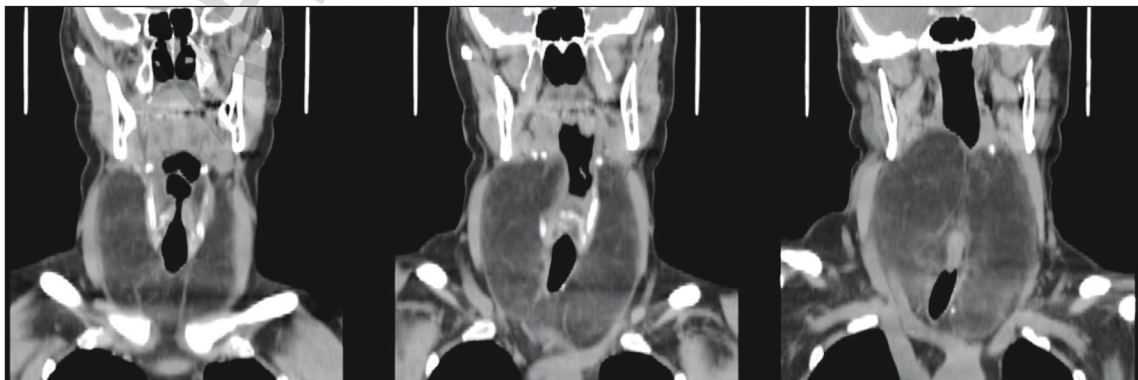

**FIGURE 1:** On non-contrast axial computed tomography images, an enlarged thyroid gland with diffuse adipose tissue infiltration extending to the posterosuperior of the oropharynx and the retrosternal space. Thyroid gland parenchymal density was measured at a mean of -65 Hounsfield unit.

parapharyngeal structures of the thyroid gland. Imaging-guided fine needle thyroid aspiration biopsy was performed after the necessary antisepsis conditions were met. Pathological examination revealed follicle structures surrounding colloid material with dense adipose tissue infiltration. The patient died after chemotherapy for hematologic malignancy (Hematological malignancy was diagnosed  $\sim 10$  months after imaging findings), sepsis and Type 1 respiratory failure during intensive care unit admission. The patient's informed consent was obtained before writing the case report manuscript.

## DISCUSSION

Amyloid goiter is rare, and when the cases in the literature are examined, it has been reported that there is no gender dominance and that it is in a wide age range.<sup>3,4</sup> Fat infiltration of the thyroid is progressive and may present with symptoms such as dyspnea and dysphagia due to compression symptoms. Apart from the clinical complaints related to the application of our case, there was a complaint of difficulty in swallowing due to the compression of the enlarged thyroid gland. Due to the increase in size, malignant processes of the thyroid and lymphoma are included in the differential diagnosis, and therefore imaging is performed. On ultrasonographic examination, thyroid gland echogenicity is usually diffuse hyperechoic.<sup>6</sup> On CT examination, the link to all parenchymal fat infiltration is observed as low HU values ( $-10$  -  $-50$  HU) and an increase in gland size. In MRI examination, the thyroid gland is observed to be enlarged and with the same signal intensity as adipose tissue in all



**FIGURE 2:** An enlarged thyroid gland with diffuse adipose tissue infiltration extending to the posterosuperior of the oropharynx and retrosternal space on coronal reformate computed tomography images.

sequences.<sup>3</sup> In our case, ultrasonographic examination revealed an increase in thyroid parenchymal echo and an increase in size. In our case, pressure findings were observed on CT except for the infiltrated thyroid gland with enlarged fat, especially explaining the complaint of difficulty in swallowing. Thyroid function tests were normal in 75.6% of these patients.<sup>6</sup> In our case, thyroid function tests were found to be normal. In amyloid goiter, loss of normal parenchymal architecture, fat cell infiltration, decrease in the number of follicles and amyloid accumulation are detected in immunohistochemical examination.<sup>7,8</sup> In our patient with a history of FMF and amyloid-related kidney disease, immunohistochemical examination was not performed, and colloid materials containing dense fat infiltration were detected as a result of fine needle thyroid aspiration biopsy. One theory in its pathophysiology has been reported as metaplasia of stromal fibroblasts and transformation into fat cells due to hypoxia due to amyloid accumulation.<sup>7</sup> Lau et al. it has been reported that mutation of mitochondrial protein succinate dehydrogenase subunit B may be in the pathophysiology of thyroid lipomatosis.<sup>9,10</sup> Amyloid accumulation occurs as a result of long-term chronic inflammatory diseases, more rarely neoplastic diseases. The presence of amyloid goiter has been reported in 0.27% of FMF patients.<sup>7</sup> In the study of López-Muñoz et al., they reported that some of the patients with amyloid goiter had renal transplantation, while all of them had amyloid-related kidney disease.<sup>4</sup> In published cases, in patients with amyloid goiter and thyrolipomatosis, the thyroid gland reaches 500-700 grams, surgery is recommended for pathological diagnosis and treatment. Similar to the ideas of López-Muñoz et al., we think that the findings of thyrolipomatosis and amyloid goiter overlap with each other.

This case report had some limitations. The first was the evaluation of fine needle aspiration biopsy preparations in a pathology center outside our hospi-

tal and no amyloid staining was performed in this center. Therefore, we were only able to access the report of the pathological evaluation. The detection of fat lobules in the pathology report supported the diagnosis of amyloid goiter in our imaging findings. Second, apart from the patient's FMF diagnosis, the patient was diagnosed with AML ~10 months after the imaging findings and died as a result of lung infection after the initial treatment. Some neoplasms and chemotherapies can cause amyloidosis.

Amyloid goiter and thyrolipomatosis are intertwined diagnoses, and the presence of comorbid diseases resulting in amyloid accumulation in these patients and the pathological demonstration of amyloid accumulation other than fat accumulation in the thyroid parenchyma will increase the diagnosis of amyloid goiter.

#### **Source of Finance**

*During this study, no financial or spiritual support was received neither from any pharmaceutical company that has a direct connection with the research subject, nor from a company that provides or produces medical instruments and materials which may negatively affect the evaluation process of this study.*

#### **Conflict of Interest**

*No conflicts of interest between the authors and / or family members of the scientific and medical committee members or members of the potential conflicts of interest, counseling, expertise, working conditions, share holding and similar situations in any firm.*

#### **Authorship Contributions**

**Idea/Concept:** Vefa Çakmak, Duygu Herek, Pınar Çakmak; **Design:** Vefa Çakmak, Duygu Herek, Pınar Çakmak; **Control/Supervision:** Vefa Çakmak; **Data Collection and/or Processing:** Vefa Çakmak, Duygu Herek, Pınar Çakmak; **Analysis and/or Interpretation:** Duygu Herek, Pınar Çakmak; **Literature Review:** Vefa Çakmak, Duygu Herek, Pınar Çakmak; **Writing the Article:** Vefa Çakmak; **Critical Review:** Duygu Herek, Pınar Çakmak; **References and Fundings:** Vefa Çakmak, Duygu Herek, Pınar Çakmak; **Materials:** Vefa Çakmak.

---

## REFERENCES

1. Demirpolat G, Guney B, Savas R, Tuncay G, Alper H, Sener RN. Radiologic and cytologic findings in a case of thyrolipoma. *AJNR Am J Neuroradiol.* 2002;23(10):1640-1. PMID: 12427614; PMCID: PMC8185822.
2. Ishida M, Kashu I, Morisaki T, Takenobu M, Moritani S, Uemura Y, et al. Thyrolipomatosis: A case report with review of the literature. *Mol Clin Oncol.* 2017;6(6):893-5. PMID: 28588784; PMCID: PMC5451857.
3. Bell S, Sosa GA, Del Valle Jaen A, Russo Picasso MF. Thyroid lipomatosis in a 36-year-old patient with rheumatoid arthritis and a kidney transplant. *Endocrinol Diabetes Metab Case Rep.* 2016;2016:160007. PMID: 27252862; PMCID: PMC4870724.
4. López-Muñoz B, Greco Bermúdez L, Marín-Jiménez D, Sánchez de la Fuente MF, Capparelli AF, Mascarell Martínez I, et al. An unusual amyloid goiter in a 48-year-old woman with rheumatoid arthritis, secondary amyloidosis and renal failure. *Case Rep Endocrinol.* 2019;2019:4291486. PMID: 31956449; PMCID: PMC6949677.
5. Yuen HY, Wong KT, Ahuja AT. Sonography of diffuse thyroid disease. *Australas J Ultrasound Med.* 2016;19(1):13-29. PMID: 34760439; PMCID: PMC8409448.
6. Bakan S, Kandemirli SG, Akbas S, Cingoz M, Ozcan Guzelbey B, Kantarci F, et al. Amyloid goiter: a diagnosis to consider in diffuse fatty infiltration of the thyroid. *J Ultrasound Med.* 2017;36(5):1045-9. PMID: 28258641.
7. Schröder S, Böcker W. Lipomatous lesions of the thyroid gland: a review. *Appl Pathol.* 1985;3(3):140-9. PMID: 3842076.
8. Arslan A, Aliç B, Uzunlar AK, Büyükbayram H, Sarı I. Diffuse lipomatosis of thyroid gland. *Auris Nasus Larynx.* 1999;26(2):213-5. PMID: 10214903.
9. Lau E, Freitas P, Costa J, Batista R, Máximo V, Coelho R, et al. Loss of mitochondrial SDHB expression: what is its role in diffuse thyroid lipomatosis? *Horm Metab Res.* 2015;47(3):165-7. PMID: 25679879.
10. Loh TL, Latis S, Ali RB, Patel H. Insular carcinoma arising on a background of follicular carcinoma, thyrolipomatosis and amyloid goitre. *BMJ Case Rep.* 2017;2017:bcr2017219747. PMID: 28576912; PMCID: PMC5534650.

ARTICLE IN PREP