

# The Cryopreserved Arterial Homograft Usage in Peripheral Arterial Diseases Having High Infection Risk (Case Report)

## YÜKSEK İNFEKSİYON RİSKLİ PERİFERİK ARTER HASTALIKLARINDA KRİYOPREZERVE HOMOĞREFT ARTER KULLANIMI (VAKA TAKDİMİ)

İsa DURMAZ\*, Yüksel ATAY\*, Hakan POSACIOĞLU\*, Fatih İSLAMOĞLU\*, Tahir YAĞDI\*, Mustafa ÇIKIRIKÇIOĞLU\*, Osman SARIBÜLBÜL\*, Suat BUKET\*, Mustafa ÖZBARAN\*

\* Dept. of Cardiovascular Surgery, Medical School of Ege University, İzmir, TURKEY

### Summary

*Surgical revascularization in patients with infected prosthetic arterial grafts and vascular injuries associated with a high risk of infection, is always an important problem for vascular surgeons. A few variety of treatment choices have been suggested to manage these problems. Usage of synthetic graft materials, which are common, mostly fail in these situations. If there isn't a chance to use autografts, arterial homografts can be a unique alternative in management of these patients.*

*Successful revascularization of 2 patients by using cryopreserved homografts were evaluated in this study. One of these patients presented with infected prosthetic Y graft and the other with iliac artery injury, having a high risk of peritonitis.*

*As a conclusion, surgical revascularization with cryopreserved arterial homografts in carefully selected patients, especially with infected prosthetic grafts and arterial trauma which has a high potential of infection, is a very good alternative method of therapy and decreases the mortality and morbidity rates of such patients.*

Key Words: Cryopreservation, Arterial homograft, Infection

T Klin J Med Res 1999, 17:23-28

The treatment of patients who have vascular injury with a considerable risk of infection and infected prosthetic arterial grafts is still an overwhelming problem in vascular surgery. Various treatment modalities regarding this matter had been developed, but many of them failed (1,2). The most

Received: Jan. 15, 1999

Correspondence: İsa DURMAZ  
Dept. of Cardiovascular Surgery  
Medical School of Ege University,  
35100 Bornova, İzmir, TURKEY

T Klin J Med Res 1999, 17

### Özet

*Enfekte damar grefti olan hastalarda ya da enfekte vasküler yaralanmalarda revaskülarizasyon, damar cerrahları için önemli bir problemdir. Bu problemin çözümü için önerilen birkaç tedavi seçeneği mevcuttur. Bunlardan birisi olan sentetik vasküler greft kullanımı enfeksiyon nedeniyle çoğunlukla başarısızlıkla sonuçlanmaktadır. Ototogreft kullanımının mümkün olmadığı durumlarda ise arterial homografler cerraha bir alternatif oluşturmaktadırlar.*

*Bu makalede kriyoprezerve arteriyel homografler ile etkili revaskülarizasyon uygulanan 2 olgu sunulmaktadır. Bu hastalardan biri enfekte prostetik arter grefti, diğeri ise enfekte iliac arter yaralanması nedeniyle öpere edilmiştir.*

*Sonuç olarak seçilmiş uygun olgularda, özellikle enfekte vasküler greft ya da enfeksiyon riski yüksek vasküler yaralanmalarda, kriyoprezerve homograft doku kullanımı iyi bir alternatif oluşturmakta; mortalite ve morbiditeyi azaltmaktadır.*

Anahtar Kelimeler: Kriyoprezervasyon, Arteriyel homograft, Enfeksiyon

T Kİ in Araştırma 1999, 17:23-28

prevailed method among them is the removing of the infected prosthetic graft and the extraanatomical replacement with a new prosthetic graft (1,3). Extraanatomic grafting, however, has some disadvantages, such as low patency rates, the high probability of infection development in the new graft and the considerable mortality and amputation rates indicated in recent literature.

The employment of homograft prosthetic materials is as old as the history of vascular surgery. The arterial homograft usage in vascular surgery was first recommended by Gross and Dubost (2, 4-

7). Despite the early willingness, the employment of homo graft arterial materials was abandoned for a very long time, because of some deficiencies and defaults in preparation of former grafts, the lack of knowledge regarding proper storage, the low patency rates and commercially available artificial prosthetic materials having more durability and feasibility in storage and usage (2). Also, complications such as spontaneous rupture, thrombosis and late aneurysm formation caused a delay and hesitation in the usage of homografts, for a long time (1,2,8). Szilagy and coworkers had reported the impossibility of homograft usage in arterial reconstructions (9). However, the appearance of some serious complications, especially, infections in practice and failure of synthetic materials in treatment of patients having vascular injury with high infection risk brought a recent interest to homograft prosthetic materials (1,2,9). Advanced experiences gained in homograft aortic valve replacements indicated that the cryopreserved valves had various advantages and higher resistance to infections. Cryopreserved homograft vascular prosthetic materials are also employed for some cases recently.

### Patients and Methods

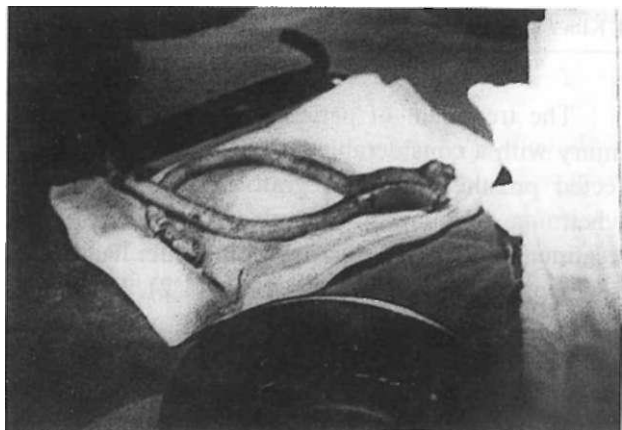
#### Case 1

64-year-old male patient diagnosed as Leriche Syndrome had undergone an aorta-bifemoral bypass operation using a dacron Y graft, in our clinic in 1986. Following a very long complication free period, induration and purulent discharge were appeared on femoral incision lines, 6 months ago. The patient was hospitalized with diagnosis of infected prosthetic graft plus pseudoaneurysm and appropriate antibiotic treatment was carried out with Vancomycine 4x500 mg/day intravenously according to the result of cultured specimen yielding *Staphylococcus aureus* as causative microorganism. Bilaterally weak lower extremity distal pulses, and bleeding at left femoral incision line and good general status were detected in physical examination at administration. Replacement of the old synthetic graft with a cryopreserved homograft arterial one was decided.

Operative approach was made through prior abdominal and femoral incision lines. The infrarenal abdominal aorta and bilateral common

femoral arteries were explored. The graft infection with discharge of purulent materials was detected and the anastomosis between the femoral arteries and graft had separated. A bifurcated aortoiliac homograft which was 14 x 8 mm in diameter and 15 cm in length and two carotid artery homografts which were 8 mm in diameter and 8 cm in length were used for revascularization. All homografts had been prepared previously and stored with cryopreservation technique. Due to inadequate length of homograft iliac arteries, two pieces of carotid arteries were combined with iliac arteries via end to end anastomosis, thereby a new conduit graft in sufficient length was obtained (Picture 1). Subsequent to removal of infected dacron graft, prepared conduit homograft was anastomosed end to side with 3-0 monofilament sutures for proximal, 4-0 and 5-0 monofilament sutures for left and right femoral anastomosis respectively (Figure 1). Vancomycine powder was poured on graft in both abdominal and femoral regions. Following the closure of the posterior peritoneum had been completed, an abdominal drainage tube was placed and incision lines were secured via separate sutures. The distal pulses of both lower extremities were palpable after the operation.

Operative follow up was uneventful. All blood cultures after surgery was negative. There was no discharge through the incision lines. The patient was discharged with complete recovery on postoperative 14th day, after he had taken antibiotic therapy for two weeks period.



Picture 1. Preparation of cryopreserved Y- shaped conduit homograft with a bifurcated aortoiliac homograft and two pieces of carotid artery homograft.

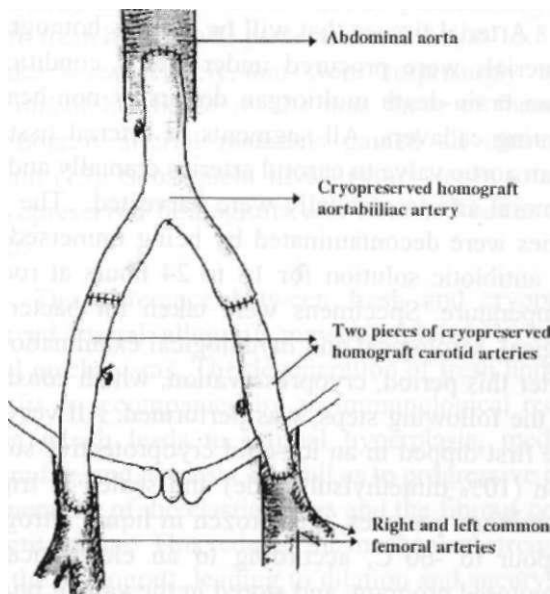
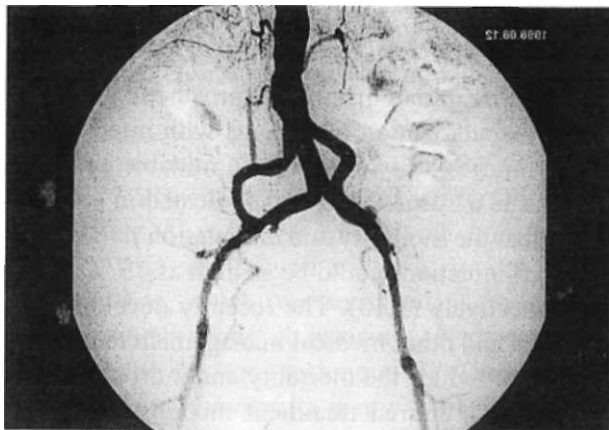


Figure 1. Schematic diagram shows the aortobifemoral bypass with cryopreserved Y- shaped conduit homograft.



Picture 2. The bifurcated conduit homograft was patent in the postoperative control angiography of the first patient.

On postoperative 8th month follow-up examination, pulses of lower extremities were detected as palpable. There was not any stenosis or another defect regarding the graft or suture lines on control angiographic evaluation (Picture 2).

### Case 2

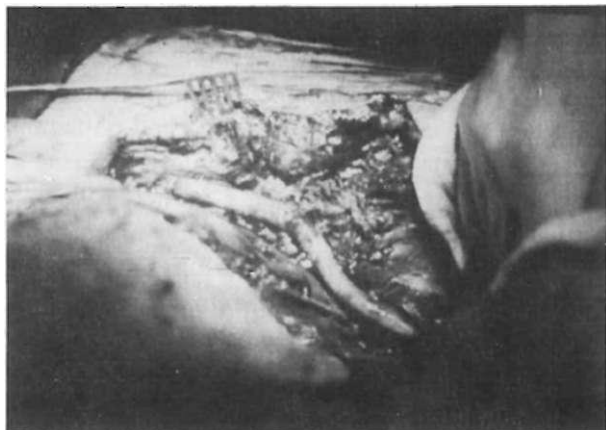
47-year-old male patient. The patient had undergone an emergency operation via resuscitation

in a rural area hospital, because of a shotgun wound affecting the right paracolic abdominal region. A segment of injured ileum (1.5 meter in length and having poor viability) was resected and remaining intact segments had been anastomosed in end to end fashion. Moreover, 8 and 1 scattered wounds located on ileum and sigmoid colon respectively had been repaired via primary sutures. Meantime, vascular injuries to the right external iliac and right common femoral arteries had been detected and after the subsequent ligation of affected arteries, the patient was emergently referred to our institution.

In physical examination, the cognitive functions were well and cooperated, systemic blood pressure was 80/40 mmHg and the heart rate was 125/ min. The incisions of former abdominal operation and massive necrosis of skin and muscle on right paracolic region were other important physical findings.

The patient was operated emergently with diagnosis of right iliac artery injury. Surgical approach to abdomen was made through former incision line extending above the right femoral artery region. The previously ligated right external iliac artery and right femoral artery were explored at proximal and distal levels. Because of the high probability of infection due to bowel injuries and massive skin and muscle necrosis, the replacement with a cryopreserved arterial homograft instead of synthetic material was decided as treatment modality. Two pieces of carotid arteries previously prepared and cryopreserved, each of 6 mm in diameter and 7 cm in length were end to end anastomosed each other, thereby a new conduit graft in adequate length was obtained. Thereafter, the conduit graft was inteposed between right common iliac artery and right common femoral artery, and vascular completeness was established again (Picture 3 and Figure 2). A buckshot injury on right iliac vein was repaired with primary suturing. After the revascularization procedure sigmoid loop colostomy was performed and the abdominal cavity was closed. Secondary healing of the right lower quadrant defect was recommended by plastic surgery.

The medical management of wound and colostomy was performed during postoperative follow-up of patient. After a complication free period, the patient was sent to back his first attendant - so-



Picture 3. The prepared conduit homograft was interposed between right common iliac artery and right common femoral artery to create vascular completeness.

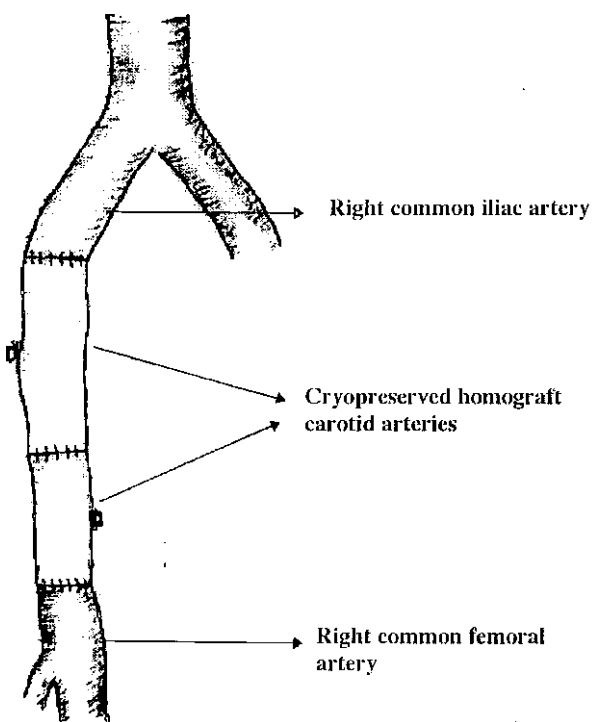


Figure 2. Schematic diagram illustrates the interposition between right common iliac artery and right common femoral artery with two pieces of cryopreserved carotid conduit homograft.

cial security hospital on postoperative 8th day with palpable right lower extremity pulses.

Colostomy was closed in postoperative 4th month and right lower quadrant defects were repaired via a series reconstructive surgical operations. Now, the patient is in the postoperative

14th month and there is no problem regarding extremity viability.

**Homograft preparation and storage methods:**

Arterial tissues that will be used as homograft materials were procured under sterile conditions from brain-death multiorgan donors or non-heart-beating cadavers. All segments of arterial tissues from aortic valve to carotid arteries cranially and to femoral arteries caudally were harvested. The arteries were decontaminated by being immersed in an antibiotic solution for 18 to 24 hours at room temperature. Specimens were taken for bacteriological, serological and mycological examinations. After this period, cryopreservation, which consists of the following steps, was performed. All vessels are first dipped in an ice-cold cryoprotective solution (10% dimethylsulfoxide) and sealed in triple aluminium pouches, then frozen in liquid nitrogen vapour to -60°C, according to an electronically monitored program, and stored in the vapour phase of liquid nitrogen at -196°C. The grafts were thawed and washed immediately before implantation in accordance with a well-defined protocol.

**Discussion**

The treatment of infected prosthetic grafts and the revascularization of patients with infected vascular injuries still constitute formidable problems for vascular surgeons. It was indicated in some reports that the mortality and amputation rates in aortic graft infections could be as high as 75 % and 35 % respectively (1,10). The recently developed antibiotics and other medical management techniques could not reduce the mortality and morbidity rates. The most preferred treatment modality is to perform an extraanatomical bypass subsequent to removing the former infected graft. Nevertheless, mortality and morbidity rates are still high with this procedure (3,11,12).

In fact, the place of arterial homografts in vascular surgery has a considerable older history. The emerged unwanted complications such as unsuccessful results of former homografts, spontaneous rupture, thrombosis and late aneurysm formation caused a delay and hesitation in using homografts, for a very long time (1,2,8). However, the failure of synthetic grafts especially in treatment of especially infected prosthetic grafts and of some traumatic

cases led the surgeons to search for new techniques. When Kieffer and coworkers reported the mortality and reoperation rates of patients treated with fresh homografts preserved in 4 °C , as 13.8 % and 9 % respectively, that were surprisingly and incomparably better results than those of former, homograft arterial materials gained all interests again (13). Subsequent investigators began to use cryopreserved homografts and obtained better results.

The difference between fresh and cryopreserved arterial allografts may be explained by several mechanisms. The degeneration of fresh homografts is accompanied by an immunological reaction which leads to intimal hyperplasia, medial thinning, and necrosis, as well as to progressive degeneration of the elastic fibers and the fibrous connective tissue. This reduces the mechanical strength of the homograft, leading to dilation and aneurysm formation, and ultimately spontaneous rupture. By contrast, cryopreserved homografts shows less infiltration with immunocompetent cells and they preserve their collagen network, the elastic lamina, and the amorphous extracellular matrix; reduces their antigenicity; and limits the immune response of the host.

Mestres and coworkers reported the mortality rate as 12.5 % in 16 patients with infected injury and operated with cryopreserved homografts (2,14). Vogt and coworkers, also, found 5.2 % mortality rate, which was an excellent result, in a similar patient group comprising 19 patients and operated with the same technique (1). The cryopreserved arterial homografts seems to be resistant to bacterial infections. Viability early after implantation may be an important factor, possibly by allowing the antibiotic drug to diffuse into the homograft. Patients with implantation of a vascular synthetic prosthesis had a higher percentage of persistence to infection during the follow-up despite the more extensive use of postoperative antibiotics. The low reoperation and structural degeneration rates of cryopreserved homograft heart valves lead to an increase in cryopreserved arterial homograft usage by investigators (8,15,16). Although there is no meticulous research with long term results about this matter, the low mortality and morbidity rates achieved with this technique are very encouraging

(1,2,13). Moreover the cryopreserved homografts shorten the hospitalization period, substantially lessen the postoperative antibiotic need and prevent the need for reoperations. In our study, the infection of first patient that could not be cured with medical management continued for 6 months. It was treated within 15 days after the operation. There ^vas no need of perfonning a second operation directed at arterial reconstruction for both patients.

Today the important matters of homograft usage are rejection and whether or not the immunosuppressive drug therapy is required. The adventitial inflammatory infiltration and degeneration in medial elastin following homograft usage may be associated with the development of rejection (2, 17). Brockbank and coworkers reported that the immunosuppressive therapy improved the patency rates in patients to whom cryopreserved arterial tissue grafts had been used (18,19). However, as Mitchell and coworkers reported, fibroblasts are unique cell type that remained alive in cryopreserved tissues and did not show antigenic property (16). Fischlein and coworkers reported that although they had confronted with immunologic reactions in almost all homograft valves, those were reversible and did not require any immunosuppressive management (20). Therefore, we did not apply immunosuppressive therapy for the patients to whom homografts were used.

It is well known that cryopreserved homografts are superior and more valuable than the fresh ones in regard to clinical performances (21). Gournier and coworkers observed in a research oriented to explain the sources of this superiority that collagen and elastic fibers were not structurally deformed and maintained their integrity in tissues exposed to a programmed cryopreservation (22). This observation is also a good evidence indicating that the better results and benefits can be obtained with cryopreserved homografts. Also Gall and coworkers suggested that homograft materials should be procured as soon as possible after the cessation of the heart and cryopreserved with short exposure of antibiotics without the use Amphotericin-B for maximum viability (23).

As a conclusion, although larger series and longer follow-ups are necessary to determine the role of cryopreserved arterial homografts in vascu-

lar surgery, we think that the cryopreserved homografts are remarkably good alternatives in some selected patients, especially with infected grafts with mycotic aneurysms and in some traumatic cases. The implantation of cryopreserved arterial homografts was highly cost-effective and that's an important factor in our country. However the limited availability of cryopreservation laboratory (to our knowledge there was no cryopreservation laboratory in Turkey except our's) excludes the extensive use of cryopreserved homografts. Only centers in limited number use fresh homograft sporadically. Collaborative studies and organisations are needed to increase the usage of cryopreserved homografts in different centers.

### REFERENCES

- Vogt PR, Segesser LK, Goffin Y, et al. Eradication of aortic infections with the use of cryopreserved arterial homografts. *Ann Thorac Surg* 1996;62:640-5.
- Mestres CA, Mulet J, Pomar JL. Large-caliber cryopreserved arterial allografts in vascular reconstructive operations: Early experience. *Ann Thorac Surg* 1995;60:S 105-7.
- Colburn MD, Moore WS. Reoperative approach for failed aortofemoral, axillofemoral and femorofemoral bypass. In: Rutherford RB, ed. *Seminars in Vascular Surgery*. Philadelphia: Saunders, 1994:139-51.
- Gross RE, Bill AH Jr., Pierce Ce III. Methods of preservation and transplantation of arterial grafts: observation on arterial grafts in dogs. Report of transplantation of preserved arterial grafts in 9 human cases. *Surg Gynecol Obstet* 1949; 88: 689.
- Dubost C, et al. A propos du traitement des aneurysms de l'aorte; ablation de l'aneurysm; reestablishment de la continuité Per greffe d'aorte conserve. *Mem Acad Chir* 1951; 77: 381.
- Oudot J. La greffe vasculaire dans les thromboses du carrefour aortique. *Pre Med* 1951; 59: 234.
- Mortensen JD, Grinday JH, Kirklin JW. The arterial homograft bank. *Proc Staff Meet. Mayo Clin.* 1953; 28: 713.
- Fujitani RM. Cryopreserved saphenous vein allogenic homografts: An alternative conduit in lower extremity arterial reconstruction in infected fields. *J Vase Surg* 1992; 15:519-26.
- Szilagyi DE, Rodriguez FJ, Smith RF. Late fate of arterial allografts: Observations 6 to 15 years after implantation. *Arch Surg* 1970;101:721-33.
- Fry WJ, Lindenauer SM. Infection complicating the use of plastic arterial implants. *Arch Surg* 1967;94:600-9.
- Bandyk DF, Bergamini TM. Infection in prosthetic vascular grafts. In: Rutherford RB, ed. *Vascular Surgery*. Philadelphia: Saunders, 1995:588-604.
- Kirklin JK, Kirklin JW, Pacifico AD, Philips SJ. Cryopreservation of aortic valve homografts. In: Yankah AC, Hetzer R, Miller DC, Ross DN, Somerville J, Yacoub MH, eds. *Cardiac valve allografts 1962-1987*. Darmstadt: Steinkopff Verlag, 1988:35-6.
- Kieffer E, Bahnini A, Koskas F, et al. In situ allograft replacement of infected infrarenal aortic prosthetic grafts: results in forty-three patients. *J Vase Surg* 1993; 17: 349-56.
- Mestres CA, Miro JM, Pomar JL. Cryopreserved homografts in the treatment of relapsing fungal cardiovascular infections. *J Thorac Cardiovasc Surg* 1994; 108: 990-1.
- O'Brien MF, Stafford EG, Gardner MAH, et al. Allograft aortic valve replacement: long-term follow up. *Ann Thorac Surg* 1995;60:S65-70.
- Mitchell RN, Jonas RA, Schoen FJ. Structure-function correlations in cryopreserved allograft cardiac valves. *Ann Thorac Surg* 1995;60:S 108-13.
- Smith JD, Ogino H, Hunt D, et al. Humoral immune response to human aortic valve homografts. *Ann Thorac Surg* 1995;60:S 127-30.
- Brockbank KGM, Donovan TJ, Ruby ST, et al. Functional analysis of cryopreserved veins: preliminary report. *J Vase Surg* 1990;2:94-102.
- Brockbank KGM, McNally R, Walsh KA. Cryopreserved vein transplantation. *J Card Surg* 1992;7: 170-6.
- Fischlein T, Schütz A, Haushofer M, et al. Immunologic reaction and viability of cryopreserved homografts. *Ann Thorac Surg* 1995;60:S 122-6.
- Ozbaran M, Mutaf I, Atay Y, Badak Z, Tokbas G, Bayindir O, Durmaz İ. Investigation of aortic homograft viability with biochemical methods. *GKD Cer.Dergisi* 1992; 1:146-51.
- Gournier JP, Adham M, Favre JP, et al. Cryopreserved arterial homografts: preliminary study. *Ann Vase Surg* 1993;7:503-11.
- Gall KL, Smith SE, Willmette CA, O'Brien MF. Allograft heart valve viability and valve-processing variables. *Ann Thorac Surg* 1998;65:1032-8.