

Right Atrial Tumor Thrombus: Original Image

Sağ Atriyal Tümör Trombüsü

Emrullah KIZILTUNÇ,^a
Selçuk ÖZKAN^b

^aClinic of Cardiology,
Ankara Numune Training and
Research Hospital,

^bDepartment of Cardiology,
Gazi University Faculty of Medicine,
Ankara

Geliş Tarihi/Received: 23.02.2013
Kabul Tarihi/Accepted: 29.03.2013

Yazışma Adresi/Correspondence:
Emrullah KIZILTUNÇ
Ankara Numune Training and
Research Hospital,
Clinic of Cardiology, Ankara,
TÜRKİYE/TURKEY
e.kiziltunc@gmail.com

Anahtar Kelimeler: Kalp atriumları;
adrenal korteks tümörleri

Key Words: Heart atria;
adrenal cortex neoplasms

For the video/videos of the article:



Türkiye Klinikleri J Cardiovasc
Sci 2014;26(2):100

Copyright © 2014 by Türkiye Klinikleri

Differential diagnosis of right atrial masses includes thrombus, vegetations and neoplasm. Our image is recorded from a 20 year-old man, who was admitted emergency service with abdominal pain and weight loss. Abdominal ultrasonography revealed a surrenal mass, and inferior vena cava invasion. We carried out an echocardiography and showed the tumor thrombus filling the inferior vena cava and expanding into the right atrium (Figure 1, 2, Video 1). The patient operated successfully, pathologic examination revealed adrenocortical tumor. Right atrial tumor thrombus is especially due to renal cell carcinoma. Other causes include adrenocortical tumors, hepatocellular carcinomas, uterine malignancies, germ line tumors, retroperitoneal neoplasms. Our image is a good example of tumor thrombus in the right atrium.

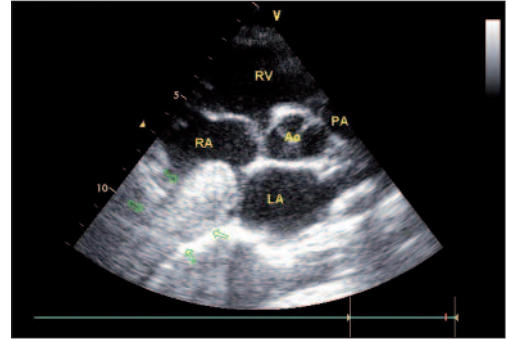


FIGURE 1: Parasternal short axis image is excellently showing the tumor thrombus filling whole inferior vena cava and protruding into the right atrium. Note that borders of mass can easily distinguished from caval walls (arrows).

RV: Right ventricul; PA: Pulmonary arter; RA: Right atrium; LA: Left Atrium; A: Aort.

(See color figure at

<http://www.turkiyeklinikleri.com/journal/cardiovascular-sciences/1306-7656/>)

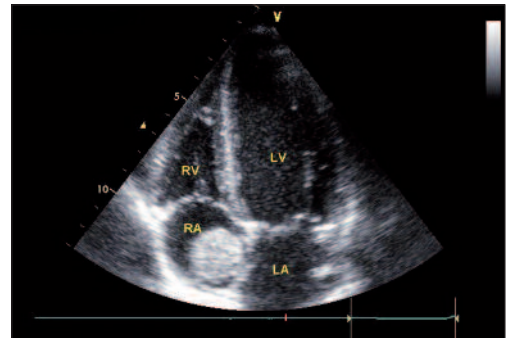


FIGURE 2: From apical four chamber window the mass can be seen like a smooth-edged ball.

RV: Right ventricul; LV: Left ventricul; LA: Left atrium; RA: Right atrium.

(See color figure at

<http://www.turkiyeklinikleri.com/journal/cardiovascular-sciences/1306-7656/>)