

# Tc-99m DMSA Scintigraphy in Recurrent Urinary Tract Infection in Children

## ÇOCUKLARDA TEKRARLAYAN İDRAR YOLU ENFEKSİYONLARINDA Tc-99m DMSA SİNTİGRAFİSİ

Elvan SAYIT\*, Mustatafa YILMAZ\*\*, İlginç YORULMAZ\*\*\*, Özlem KUT\*\*, Yakup YÜREKLİ\*\*, Mehmet TÜRKMEN\*\*\*\*, Salih KAVUKÇU\*\*\*\*, Hatice DURAK\*\*

\* Dept. of Nuclear Medicine, Medical School of Celal Bayar University, Manisa,

\*\* Dept. of Nuclear Medicine, Medical School of Dokuz Eylül University, İzmir,

\*\*\* Dept. of Radiology, Medical School of Celal Bayar University, Manisa

\*\*\*\* Dept. of Pediatrics, Medical School of Dokuz Eylül University,

\*\*\*\*\* Dept. of Pediatrics, Medical School of Dokuz Eylül University, İzmir, TURKEY

### Summary

*Tc-99m DMSA scintigraphy is the imaging modality of choice for the detection of renal cortical scarring and renal parenchymal status. The present study was designed to compare radionuclide cortical imaging with IVU and USG for the detection of postpyelonephritic cortical scars and to define the indications of DMSA in the pediatric nephrology field and to enhance the clinicians' interest in the renal cortical scintigraphy. In the present study, we performed Tc-99m DMSA cortical scan on 25 children (49 kidneys) with recurrent urinary tract infections who were at risk for renal scarring. Intravenous urography and ultrasonography were also performed on 15 patients. Their age ranged from 4 months to 16 years (mean: 8.1±4.4 years). Renal scarring was detected in 24 of 49 kidneys. DMSA cortical scanning and IVU/USG were in concordance in the normal kidneys. DMSA cortical scanning detected more scars than IVU and USG. We conclude that DMSA scanning is the most valid modality in the evaluation of kidneys at risk for scarring in children.*

**Key Words:** Tc-99m DMSA, Urinary tract infection, Intravenous urography, Ultrasonography.

T Klin J Med Res 2000, 18:17-21

Received: Sep. 16, 1999

Correspondence: Elvan SAYIT  
Dept. of Nuclear Medicine  
Medical School of Celal Bayar University  
45030, Manisa, TURKEY

*^This article was presented as a poster presentation on October. 24-27, 1993, at the 21st Congress of Union of Middle Eastern and Mediterranean Pediatric Societies (UMEMPS), İzmir, TURKEY*

T Klin J Med Res 2000. 18

### Özet

*Tc-99m DMSA sintigrafisi renal kortikal skar saptanmasında ve renal parankim incelenmesinde seçilecek görüntüleme yöntemidir. Bu çalışmada postpyelonefritik kortikal skorların saptanmasında radyonüklid kortikal görüntülemenin TVU ve USG ile karşılaştırılmasının yanısıra pediatrik nefroloji alanında DMSA'nın endikasyonlarını daha iyi belirleyerek klinisyenlerin renal kortikal sintigrafiye olan ilgilerinin artırılması amaçlandı. Bu çalışmada renal skar açısından risk altında olan tekrarlayan idrar yolu enfeksiyonlu 25 çocuğa (49 böbrek) Tc-99m DMSA kortikal sintigrafisi uygulandı. 15 hastaya intravenöz ürografi (IVU) ve ultrasonografi (USG) uygulandı. Hastaların yaşları 4 ay ile 16 yıl arasındaydı (ortalama: 8.1±4.4 yıl). 49 böbreğin 24'ünde renal skar saptandı. Skar açısından risk altında olan böbreklerin değerlendirilmesinde DMSA sintigrafisinin en geçerli yöntem olduğu sonucuna varıldı.*

**Anahtar Kelimeler:** Tc-99m DMSA, Üriner sistem enfeksiyonu, intravenöz ürografi, ultrasonografi

T Klin Araştırma 2000, 18:17-21

Urinary tract infections in children may be symptomatic or asymptomatic. Symptomatic urinary tract infections may be confined to the bladder (cystitis) or renal parenchyma (pyelonephritis).

Technetium 99m (Tc-99m) dimercaptosuccinic acid (DMSA) scintigraphy is the imaging modality of choice for the detection of acute pyelonephritis and chronic renal scarring in children. DMSA is a

radiopharmaceutical that localizes in the proximal tubular cells in the renal cortex, that provides an image of functional renal parenchyma (that allows visualization of functioning renal parenchyma) (1). DMSA is actively accumulated by the renal proximal tubules following two pathways:

- peritubular uptake
- filtration plus reabsorption

Its integrity is dependant upon several parameters combining intact intrarenal blood flow and intact enzyme function (2). Any pathological process that alters either or both of these parameters may result in focal or diffuse areas of diminished uptake. DMSA offers a unique opportunity to study the progression of renal damage and functional loss from the initial insult of acute pyelonephritis to the subsequent development of irreversible renal scarring.

Clinical reports in the 1980's indicated that renal cortical scintigraphy was more useful than intravenous urography (IVU) or ultrasonography (USG) in confirming the diagnosis of acute pyelonephritis (3-5).

Intravenous urography has been the traditional modality to evaluate renal parenchymal scarring. However, recent studies comparing the diagnostic capability of renal cortical scintigraphy with DMSA to that of the IVU have demonstrated a greater sensitivity with radionuclide imaging, especially in younger children (6,7). USG has been evaluated as one of the imaging techniques for differentiating acute pyelonephritis from lower urinary tract infection (UTI). Although USG is a useful technique for initial assessment of upper urinary tracts and anatomical definition, it is a relatively insensitive test for the detection of acute inflammatory changes of renal cortex. The present study has two aims: one of them is to compare radionuclide cortical imaging with IVU and USG for the detection of postpyelonephritic cortical scars and the other one is to define the indications of DMSA in the pediatric nephrology field and to enhance the clinicians' interest in the renal cortical scintigraphy.

### Materials and Methods

Sixteen female and 9 male children (mean age:  $8.1 \pm 4.4$  years; range from 4 months to 16 years) were included. They all experienced urinary tract

infection more than once. For follow up, they were imaged again at least 3 months after acute infection. Tc-99m DMSA, IVU and/or USG were performed within the same week.

A dose of 2 MBq/kg (with a minimum dose of 20 MBq) Tc-99m DMSA was administered intravenously. Four and 24 hours later anterior, posterior and posterior oblique planar images were obtained with a gamma camera (GE Starcam, XR/T) in 256 x 256 matrix using an acquisition time of 5 minutes for each individual image. DMSA images of 49 kidneys were evaluated visually by two independent observers. Presence of areas with diminished focal cortical uptake was accepted as cortical scarring. The set of criteria for the normal appearance of Tc-99m DMSA planar images as developed by "International Radionuclides in Nephrology" was used to minimize false positive results (8). IVU, USG and DMSA scanning were evaluated by correlating with each other.

### Results

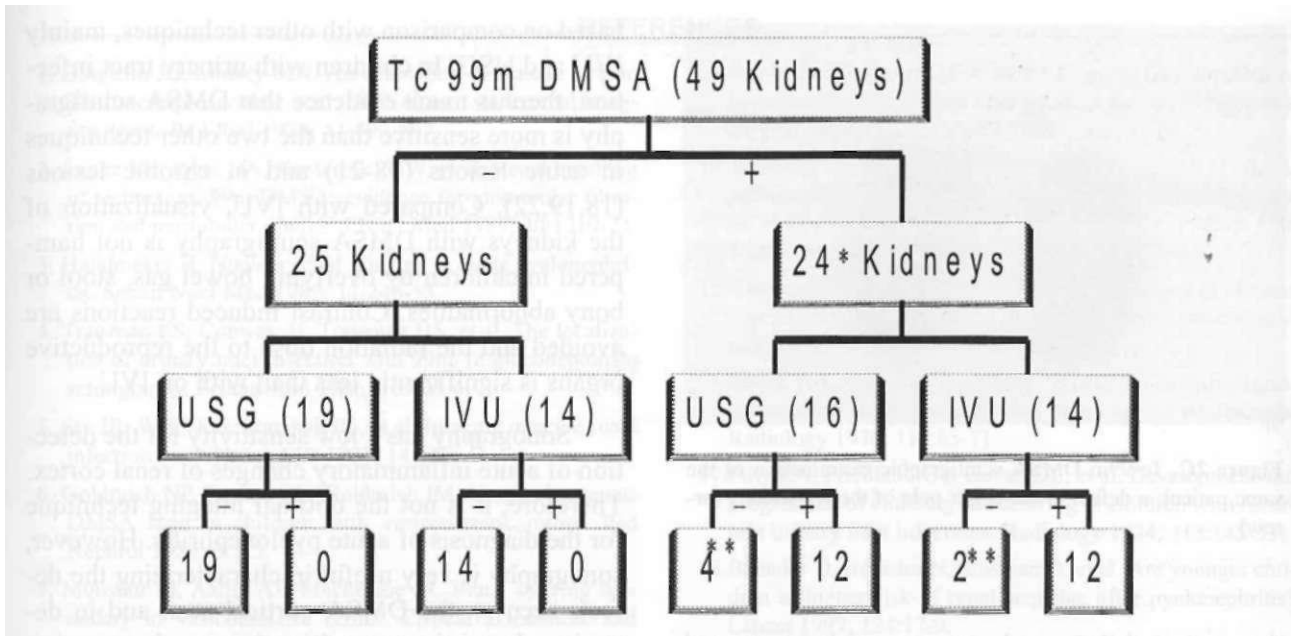
The distribution of positive and negative findings in three modalities is shown in Figure 1. Regarding Tc-99m DMSA as the gold standard modality; the evaluation of the sensitivity and specificity of IVU and USG compared to DMSA is shown in Table 1. USG, IVU and Tc-99m DMSA examinations of a 8 year old male patient are shown in Figure 2A, 2B and 2C, respectively.

### Discussion

Tc-99m DMSA is an excellent renal cortical imaging agent. About 60% of the administered dose is tightly bound to the proximal tubular cells and only a small amount is slowly excreted in the urine. DMSA allows visualization of renal parenchyma without interference from retained tracer in the collecting systems (9). Renal cortical abnormalities, demonstrated by DMSA radionu-

**Table 1.** The sensitivity and specificity of IVU and USG compared to DMSA

	Gold standard: Tc-99m DMSA	
	IVU	USG
Sensitivity (%)	85	75
Specificity (%)	100	100

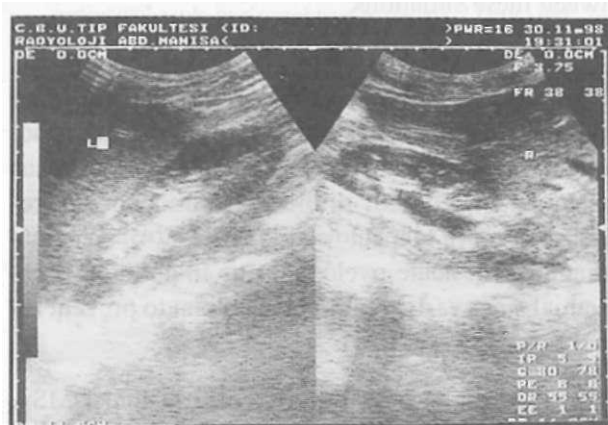


**Figure 1.** The distribution of positive and negative findings in IVU-USG-DMSA.

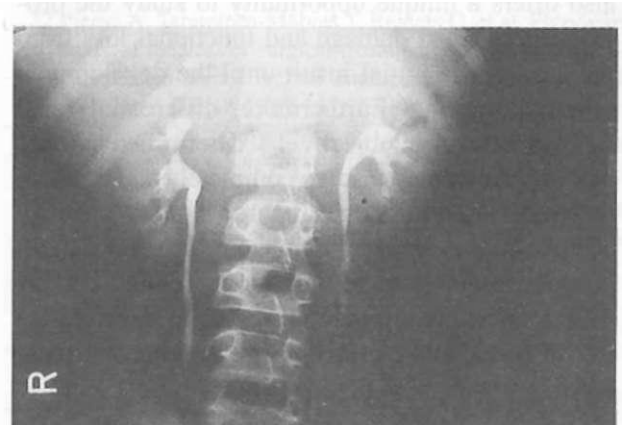[Values in parenthesis ( ) indicate the number of kidneys examined with the mentioned technique]

\*;/ the follow up of these 24 kidneys after at least three months, no change in the scintigraphic appearances were detected, thus indicating renal scarring.

\*\*The negative findings in ultrasonographic examination were present in 4 kidneys which were later studied with IVU examination.



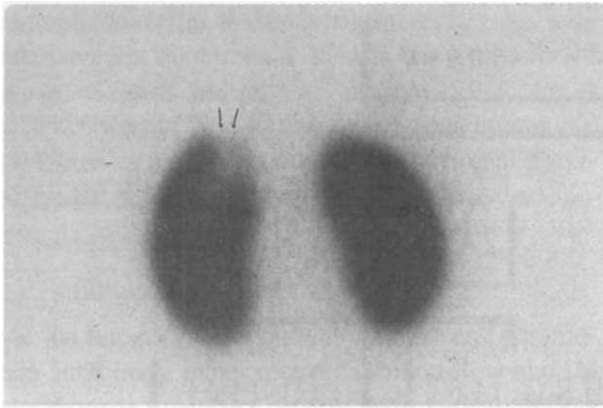
**Figure 2A.** Ultrasonographic examination of a 8 year old male patient: normal.



**Figure 2B.** The intravenous urographic examination of the same patient: normal.

elide studies, represent areas of proximal tubular dysfunction and scars. It has been shown in the pig model that DMSA abnormalities detected in the presence of an experimentally induced urinary tract infection correspond to acute pyelonephritic foci (10,11).

Acute pyelonephritis is a major cause of morbidity in children with UTI and can result in irreversible renal cortical scarring. Well recognized late sequelae of pyelonephritic scarring include hypertension, proteinuria and chronic renal failure (12,13). Clinical and experimental studies have



**Figure 2C.** Tc-99m DMSA scintigraphic examination of the same patient: a defect in the upper pole of the left kidney (arrow)

demonstrated that renal scarring can be prevented or diminished by early diagnosis and aggressive treatment of acute pyelonephritis (14,15). Therefore, accurate diagnosis of acute pyelonephritis has significant clinical relevance. DMSA renal scintigraphy is a valid tool for confirming the diagnosis of acute pyelonephritis and for identifying kidneys at risk for subsequent cortical scarring and also offers a unique opportunity to study the progression of renal damage and functional loss from the time of the initial insult until the development of renal scarring. Furthermore, differential renal function can be objectively determined. Acute pyelonephritis may resolve completely and the scan may return to normal within three months or it may become into permanent damage or scar formation. In order to increase the specificity, Tc-99m DMSA follow up scans are recommended to differentiate ischemia due acute infection from permanent renal scarring.

The IVU has been the traditional modality for evaluation of renal parenchymal scarring, but however it is not a sensitive detector of acute pyelonephritis (16). Furthermore, it has been stated that pyelographic evidence of new renal scarring may take up to 2 years to develop after urinary tract infection (17). Pyelographic evidence of renal scarring reflects an architectural change caused by contraction of the damaged cortex and continued growth of the surrounding normal cortex, which requires time. Studies on sensitivity are generally

based on comparison with other techniques, mainly IVU and USG. In children with urinary tract infection, there is much evidence that DMSA scintigraphy is more sensitive than the two other techniques in acute lesions (18-21) and in chronic lesions (18,19,22). Compared with IVU, visualization of the kidneys with DMSA scintigraphy is not hampered in children by overlying bowel gas, stool or bony abnormalities. Contrast induced reactions are avoided and the radiation dose to the reproductive organs is significantly less than with on IVU.

Sonography has a low sensitivity for the detection of acute inflammatory changes of renal cortex. Therefore, it is not the optimal imaging technique for the diagnosis of acute pyelonephritis. However, sonography is very useful in characterizing the defects seen on the DMSA cortical scan and in detecting obstructive uropathies that may be associated with UTI. Scintigraphic abnormalities are not specific. In case of acute urinary tract infection, regional defects can be due to acute infection but also to any other underlying disease such as renal abscess, hydronephrosis, cysts, or complicated duplex kidney. It is mandatory, therefore, to combine scintigraphy with USG allowing differentiation between these situations.

The importance of the timing of therapy has been reported in animal studies in which early antibiotic treatment prevented or diminished subsequent renal scarring (15). Therapeutic delay has been associated with an increased frequency of renal scarring in clinical reports (14,23,24). Accurate diagnosis of acute pyelonephritis in children is essential since early treatment is crucial to prevent renal scarring (14,23,24).

The results of our study confirm that DMSA examinations detects a significantly higher number of renal cortical abnormalities than detected on USG and/or IVU. We conclude that Tc-99m DMSA scanning is a sensitive modality compared to IVU and USG in the evaluation and the follow up of the kidneys at risk for scarring in children. There should definitely be no concern regarding the efficiency of DMSA in the pediatric nephrology departments and clinicians should enhance their interest in referring pediatric patients for DMSA scintigraphic examinations.

## REFERENCES

1. Bingham JB, Maisey MN. An evaluation of the use of 99m Tc-dimercaptosuccinic acid (DMSA) as a static renal imaging agent. *Br J Rad* 1978; 51:599-607.
2. Lange MJ, Piers DA, Kosternik JGW, et al. Renal handling of technetium-99m DMSA: evidence for glomerular filtration and peritubular uptake. *J Nucl Med* 1989; 30:1219-23.
3. Handmaker H. Nuclear renal imaging in acute pyelonephritis. *Semin Nucl Med* 1982; 12:246-53.
4. Traisman ES, Conway JJ, Traisman HS, et al. The localization of urinary tract infection with 99m-Tc glucoheptonate scintigraphy. *Pediatr Rad* 1986; 16:403-6.
5. Sty JR, Wells RG, Starshak RJ, et al. Imaging in acute renal infection in children. *AJR* 1987; 148:471-7.
6. Goldraich NP, Ramos OL, Goldraich IM. Urography versus DMSA scan in children with vesicoureteric reflux. *Ped Nephrol* 1989; 3:1-5.
7. Monsour M, Azmy AF, Mackenzie JR. Renal scarring secondary to vesicoureteric reflux. Critical assessment and new grading. *Br J Urol* 1987; 60:320-4.
8. Pusuwan P, Reyes L, Gordon I. Normal appearances of technetium-99m dimercaptosuccinic acid in children on planar imaging. *Eur J Nucl Med* 1999; 26:483-8.
9. Bjorgvinsson E, Majd M, Eggli KD. Diagnosis of acute pyelonephritis in children: comparison of sonography and 99mTc-DMSA scintigraphy. *AJR* 1991; 157:539-43.
10. Rushton HG, Majd M, Chandra R, et al. Evaluation of 99mtechnetium dimercaptosuccinic acid renal scans in experimental acute pyelonephritis in piglets. *J Urol* 1988; 140 (part 2): 1169-74.
11. Parkhouse HF, Godley ML, Cooper J, et al. Renal imaging with 99mTc-labelled DMSA in the detection of acute pyelonephritis: an experimental study in the pig. *Nucl Med Comm* 1989; 10:63-70.
12. Torres VE, Velosa JA, Holley KE, et al. The progression of vesicoureteral reflux nephropathy. *Ann Intern Med* 1980; 92:776-84.
13. Jacobson SH, Eklof O, Eriksson CG, et al. Development of hypertension and uremia after pyelonephritis in childhood: 27 year follow up. *Br Med J* 1989; 299:703-6.
14. Winberg J, Bollgren I, Kallenius G, et al. Clinical pyelonephritis and focal renal scarring. A selected review of pathogenesis, prevention and prognosis. *Pediatr Clin North Am* 1982; 29:801-14.
15. Glauser MP, Lyons JM, Braude AL. Prevention of chronic experimental pyelonephritis by suppression of acute suppuration. *J Clin Invest* 1978; 61:403-7.
16. Silver TM, Kass EJ, Thornbury JR, et al. The radiological spectrum of acute pyelonephritis in adults and adolescents. *Radiology* 1976; 118:65-71.
17. Filly RA, Friedland GV, Govan DE, et al. Development and progression of clubbing and scarring in children with recurrent urinary tract infections. *Radiology* 1974; 113:145-53.
18. Benador D, Benador N, Slosman D, et al. Are younger children at higher risk of renal sequelae after pyelonephritis? *Lancet* 1997; 349:17-9.
19. Benador D, Benador N, Slosman DO, et al. Cortical scintigraphy in the evaluation of renal parenchymal changes in children with pyelonephritis. *J Pediatr* 1994; 124:17-20.
20. Linne T, Fituri O, Escobar-Billing R, et al. Functional parameters and Tc-99m DMSA scan in acute pyelonephritis. *Pediatr Nephrol* 1994; 8:694-9.
21. Goldraich NP, Goldraich IP. Update on DMSA renal scanning in children with urinary tract infection. *Pediatr Nephrol* 1995; 9:221-6.
22. Piepsz A, Tamminen-Mobius T, Reiners C, et al. Five-years study of medical or surgical treatment in children with severe vesico-ureteral reflux dimercaptosuccinic acid findings. *Eur J Pediatr* 1998; 157:753-8.
23. Winter AL, Handy BE, Alton DJ, et al. Acquired renal scars in children. *J Urol* 1983; 129:1190-94.
24. Smellie JM, Ransley PG, Normand ICS, et al. Development of new renal scars: a collaborative study. *Br Med J* 1985; 290:1957-60.