

Chairside All-Ceramic Resin Bonded Fixed Partial Denture: Case Report and Review of the Literature

Hasta Başında Üretilen Tam Seramik Rezın Bağlı Sabit Bölümlü Protez: Olgu Sunumu ve Literatür Derlemesi

İrem TÜRKCAN,^a
Seçil KARAKOÇA NEMLİ,^a
Merve BANKOĞLU GÜNGÖR,^a
Evşen TAMAM^a

^aDepartment of Clinical Sciences,
Division of Prosthodontics,
Gazi University Faculty of Dentistry,
Ankara

Geliş Tarihi/Received: 07.10.2014
Kabul Tarihi/Accepted: 08.01.2015

*This study was presented as a poster at
Congress of 19th BaSS, 24-27 April 2014,
Belgrade, Serbia*

Yazışma Adresi/Correspondence:
Seçil KARAKOÇA NEMLİ
Gazi University Faculty of Dentistry,
Department of Clinical Sciences,
Division of Prosthodontics, Ankara,
TÜRKİYE/TURKEY
secilkarakoca@yahoo.com

ABSTRACT Resin-bonded fixed partial dentures (RBFDPs) offer a minimally invasive, fixed-prosthetic alternative for anterior single-tooth replacement. The purpose of this report is to represent the use of chairside CAD/CAM generated all-ceramic RBFDP and to provide a brief review of literature on outcomes of all-ceramic RBFDPs. In a patient with anterior single-tooth loss, minimal preparations were made on periodontally healthy and caries free abutment teeth. Using CEREC system; optical impressions were taken, virtual models were generated, and RBFDP was individually designed. The restoration was milled from IPS e.max CAD block, glazed and adhesively cemented. The patient was satisfied with the esthetic result. During a 1-year follow-up period no biological or mechanical complication was observed. By using a tooth colored and naturally translucent restorative material, all-ceramic resin bonded fixed partial dentures provided satisfactory esthetic result. Furthermore due to the chairside CAD/CAM production, highly precise restorations could be fabricated in a single appointment.

Key Words: Denture, partial, fixed, resin-bonded; ceramics; computer-aided design; lithia disilicate

ÖZET Rezın bağı sabit bölümlü protezler (RBSBP), anterior tek diş eksikliğinin tedavisinde minimal invaziv bir tedavi alternatifidir. Bu olgu sunumunun amacı, hasta başında CAD/CAM ile üretilen tam seramik RBSBP'nin uygulamasını anlatmak ve tam seramik RBSBP'lerin uzun dönem sonuçları ile ilgili kısa bir literatür derlemesi sunmaktır. Anterior tek diş eksikliğine sahip bir hastada, periodontal olarak sağlıklı ve çürüksüz olan destek dişlerde minimal preparasyon yapılmıştır. CEREC sistemi kullanılarak optik ölçüler alınmış, sanal modeller elde edilmiş ve kişisel RBSBP tasarımı yapılmıştır. IPS e.max CAD bloktan freze edilerek üretilen restorasyon glazelenmiş ve adeziv olarak simante edilmiştir. Hasta estetik sonuçtan memnun kalmış ve 1 yıllık takip süresince biyolojik veya mekanik komplikasyon gözlemlenmemiştir. Diş renginde olan ve doğal translusensiyeye sahip bir restoratif materyal kullanılarak üretilen tam seramik RBSBP'ler ile estetik olarak oldukça memnun edici bir sonuç elde edilmektedir. Ayrıca, hasta başı CAD/CAM üretimi sayesinde tek seansta hassas uyuma sahip restorasyonlar hazırlanabilmektedir.

Anahtar Kelimeler: Protez, kısmi, sabit, rezın bağı; seramikler; bilgisayar yardımlı tasarım; lityum disilikat

Türkiye Klinikleri J Dental Sci Cases 2015;1(1):41-9

Prosthetic restoration of short edentulous spaces can be accomplished by implant-supported fixed partial dentures (FPDs), conventional FPDs, or resin bonding fixed partial dentures (RBFDPs).¹ Although implant-supported FPDs represent a reliable treatment alternative with long term high success rates, they might require a number of surgical interven-

doi: 10.5336/dentalcase.2014-41936

Copyright © 2015 by Türkiye Klinikleri

tions.² Especially in the anterior region, placement of implants is not always possible due to inadequate bone volume.¹ In these situations, several surgical procedures including grafting, implant placement, and abutment connection become compulsory. Therefore, the treatment period is generally prolonged and comfort and satisfaction of the patient may be impaired. Conventional FPDs, another common treatment option for restoration of short edentulous spaces, is questionable in the presence of sound and restoration free adjacent teeth because of the extensive reduction of these teeth.³ When compared with implant-supported and conventional FPDs, RBFDPs have many advantages in terms of preserving tooth structure, reversibility, reducing chairside time, cost effectiveness, and decreasing the stress caused by tooth preparation.⁴ Therefore, a RBFDP might represent a good alternative for the treatment of short edentulous spaces, particularly in cases with single tooth loss in the anterior region.⁴

Replacement of single maxillary or mandibular anterior teeth by means of RBFDPs was first introduced in 1970s by Rochette, utilizing macro-mechanical retention through perforated cast metal retainers.⁵⁻⁷ With introduction of non-perforated cast metal framework designs, the poor performance of RBFDPs was somewhat improved.^{7,8} With advances in adhesive cementation, alloy-surface treatments provided higher bond strength for metal restorations.⁹ However, debonding at the metal-cement interface is still the most frequent cause of clinical failure of RBFDPs.⁷ Additionally, the major problem with metal-ceramic RBFDPs is the grayish appearance of the metal framework through thin or translucent anterior teeth, which jeopardize the esthetics of the prosthesis.^{10,11} Also, biocompatibility of non-precious metal alloys used in metal-ceramic RPFDPs is questionable.¹² These alloys can cause allergic responses when they come into contact with oral tissues in some patients.^{11,13}

First all-ceramic RBFDPs were introduced in early 1990s to eliminate the problems with metal structure.^{7,12} Due to the improved mechanical properties of reinforced ceramic materials, all ceramic RBFDPs become a viable treatment option espe-

cially for anterior single tooth replacements. In-Ceram Alumina (VITA Zahnfabrik, Bad Säckingen, Germany), reinforced with aluminum oxide, was used in the initial applications of all ceramic RBFDPs.¹² Afterwards, various ceramic materials including reinforced with leucite (IPS Empress), lithium disilicate (IPS Empress 2, IPS e.max) and zirconium oxide have been used in fabrication of RBFDPs.^{7,12,14-18}

CAD/CAM (computer aided design-computer aided manufacturing) systems are recently used for the fabrication of all-ceramic RBFDPs.¹⁹ In contrast to conventional fabrication procedures, chairside CAD/CAM systems with optical impression components, reduce time consuming steps (impression making, plaster model fabrication) and enable dentists to deliver restorations in a single appointment.²⁰ After tooth preparation; optical impression making, evaluating the virtual models, and 3D design of the restoration can be performed chairside. Then, the information is transferred to the milling unit. Eventually, restoration can be fabricated from ceramic blocks in a few hours. Thus, CAD/CAM generated RBFDPs offer chairside treatment and less fabrication time than laboratory produced RPFDPs. Furthermore, restorations composed of dense, high quality, homogeneous ceramic structure can be obtained due to prefabricated blocks.²¹

While this alternative has advantages as superior esthetic and possibility of chairside production, its long-term outcomes is still unknown. The purpose of this report is to represent the use of chairside CAD/CAM generated all-ceramic RBFDP for anterior single-tooth replacement and to provide a brief review of literature on outcomes of all-ceramic RBFDPs.

CASE REPORT

A 51-year-old woman, with loss of mandibular right central incisor, referred to department of prosthodontics for treatment (Figure 1). Neighboring teeth to the edentulous space were clinically and radiographically evaluated, owing to being considered as the abutment teeth for the prospective restoration. Mandibular left central incisor and

right lateral incisor were caries-free, vital, periodontically healthy and had no restorations. Therefore, as a minimally invasive approach, a RBFDP was planned. Patient's high esthetic demands led to fabricate a lithium disilicate based all-ceramic restoration.

Prior to preparation, shade was selected after cleaning teeth with pumice slurry. IPS e.max CAD LT (low translucency) A2 lithium disilicate block (Ivoclar Vivadent, Schaan, Liechtenstein) was preferred. Minimal tooth preparations were made limited in the enamel by using flame shaped chamfer and shoulder diamond rotary cutting instruments (Diatech Premium Rotary Instruments, Coltène/Whaledent AG, Altstätten, Switzerland) (Figure 2). The lingual surfaces of abutment teeth were reduced with the guidance of a 0.3 mm-depth marker rotary instrument (Diatech Premium Rotary Instruments, Coltène/Whaledent AG, Altstätten, Switzerland), approximately 0.3 mm. A supragingival chamfer finish line was formed approximately 1 mm above the marginal gingival and approximately 2 mm below the incisal edge. A proximal knife-edge finish line was formed 1mm above the marginal gingiva.

Digital impressions of maxillary and mandibular teeth were made using an intraoral camera (Cerec Omnicam, Sirona Dental Systems, Bensheim, Germany). Then, buccal bite registration was recorded in maximum intercuspation. After 3D virtual models were obtained (Figure 3a), the model axis was set. A special software (inLab SW 4.2.1.61068, Sirona Dental Systems, Bensheim, Germany) was used to design the RBFDP. "Biogeneric Individual" and "Bridge Restoration" were selected for the design mode and restoration type, respectively. Mandibular left central incisor and right lateral incisor were selected as "veneers" and mandibular right central incisor was selected as "pontic". Margins were drawn on the virtual model (Figure 3b). After a restoration proposal was calculated by the software, some modifications were made on this design. To generate a cleanable space for tissue surface of the pontic, "lingual opening angle" parameter of the restoration was set 15° (Figure 3c). Soft tissue contact was ensured at the buc-

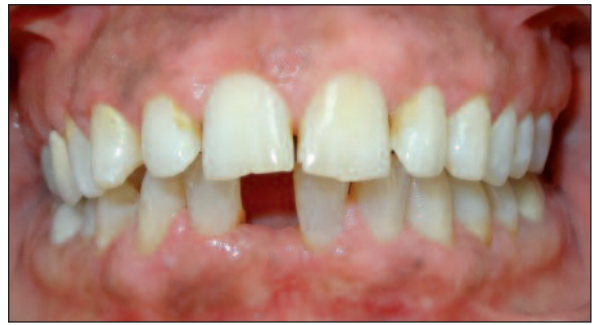

FIGURE 1: Initial view of mandibular single tooth loss.

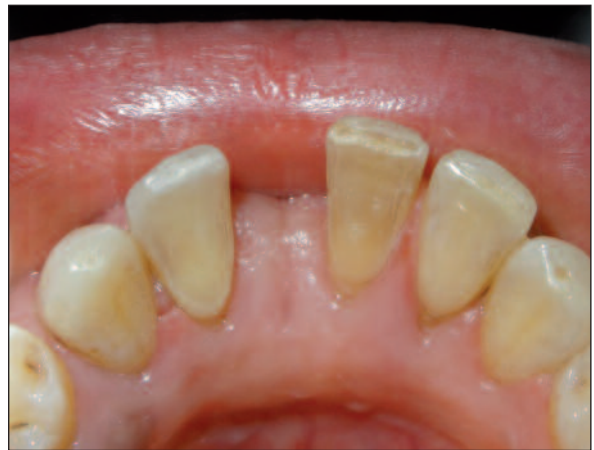

FIGURE 2: Preparation of the abutment teeth.

cal surface of pontic (Figure 3d). Spacer thickness of 100 μm and veneer thickness of 300 μm were set.

RBFDP was milled from a partially crystallized lithium disilicate glass-ceramic block (IPS e.max CAD, Ivoclar Vivadent, Schaan, Liechtenstein) by a milling unit (inLab MC XL, Sirona Dental Systems, Bensheim, Germany). When the milling process was finished, the RBFDP in the partially crystallized state was retrieved from the milling unit (Figure 4a). Then, the restoration was fully crystallized in a furnace (Programat P300, Ivoclar Vivadent, Schaan, Liechtenstein) according to the crystallization firing program recommended by the manufacturer (Figure 4b). Due to the lithium disilicate block was monochromatic, further shade characterization was required. Shade characterization was performed considering adjacent teeth, with using IPS e.max Ceram Shade 1 and E 04 Sun-

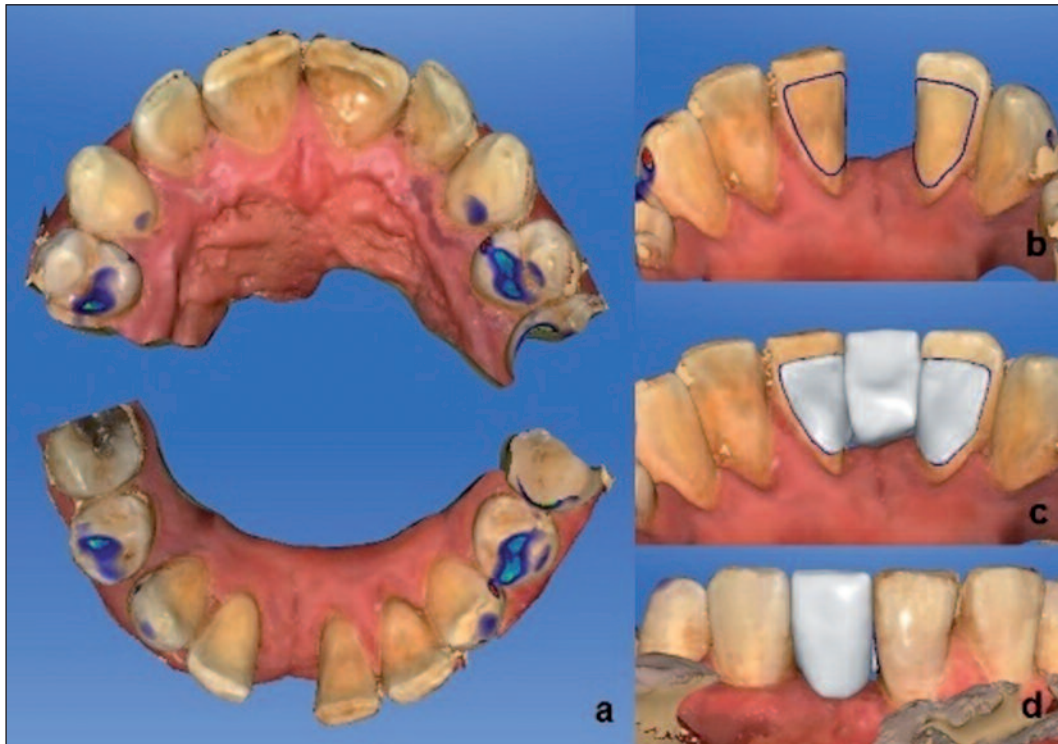


FIGURE 3: Virtual models and design of the restoration. (a) Virtual models of maxilla and mandible. (b) Margins of the restoration. (c) Lingual view of the restoration. (d) Buccal view of the restoration.

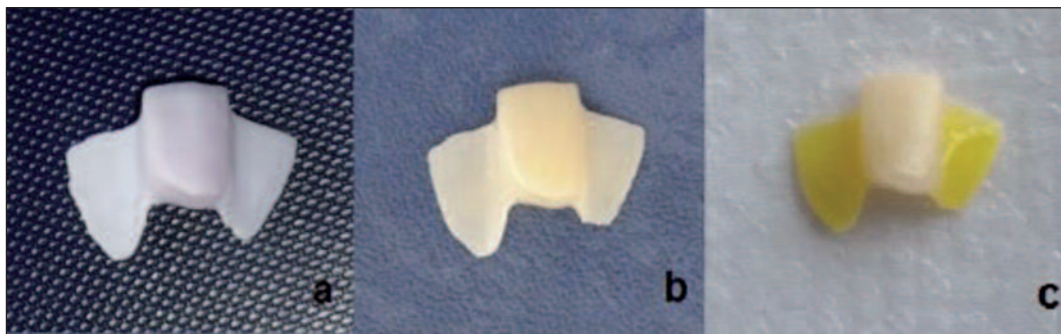


FIGURE 4: Milled restoration. (a) Partially crystallized state of the lithium disilicate based restoration. (b) Fully crystallized restoration. (c) Hydrofluoric acid etching of the bonding surfaces of the restoration.

set (Ivoclar Vivadent, Schaan, Liechtenstein). The RBFPD was checked in terms of fit, esthetics, and occlusion and subsequent glaze (IPS e.max CAD Crystall/Glaze Paste) firing was performed. Prior to cementation of RBFPD, restoration bonding surfaces of the retainer teeth and restoration were prepared. Enamel surfaces of the retainer teeth were cleaned with pumice slurry and etched with 35% phosphoric acid for 30 seconds. Ceramic surfaces

were conditioned with 9% hydrofluoric acid (Ultradent Porcelain Etch, South Jordan, Utah, USA) for 90 seconds (Figure 4c) and subsequent silanization (Ultradent Silane, South Jordan, Utah, USA) was performed for 60 seconds. Bonding was accomplished with dual-cure resin cement (Panavia F 2.0, Kuraray, Okayama, Japan) according to manufacturer's instructions (Figures 5, 6). Luting resin cement was light-cured for 5 seconds and excess

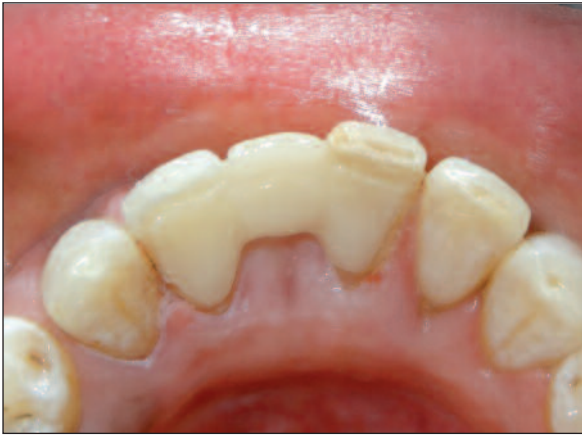

FIGURE 5: Lingual view of the cemented restoration.

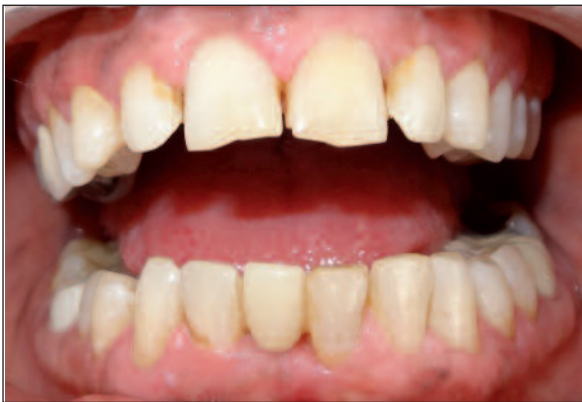

FIGURE 6: Buccal view of the cemented restoration.

cement was removed. Afterwards, light curing of the cement was completed.

The patient was satisfied with the esthetical results and the function of the prosthesis. During a 1-year follow-up period, no biological or mechanical complication was observed. Retaining teeth were caries-free and periodontal tissues were healthy.

DISCUSSION

In the present case, a chairside all-ceramic RBFPD was the choice of treatment considering clinical conditions and the patient's treatment needs and preferences. An implant-supported crown and a conventional three-unit FPD, which are the most common treatment options in case of single-tooth

loss were excluded from the treatment planning. Although the implant-supported single crowns are probably the most common indication for implant placement and very promising outcomes have been reported; surgical procedures and osseointegration period were not accepted by the patient.²²⁻²⁶ The conventional FPD treatment was also excluded since the abutment teeth were vital and sound. RBFPD was explained to the patient, owing to minimal invasive approach it was accepted by the patient. Furthermore, to improve esthetic outcome of the restoration and to reduce treatment time, chairside all-ceramic RBFPD was considered as the most appropriate indication for the present case.

RBFPDs, in other respects, might be the most rational treatment alternative in certain clinical situations. In patients with medical conditions such as immune-suppression or active treatment of malignancy, this minimal invasive approach might be the only viable prosthetic treatment type.^{7,27} Also, other advantages as reversibility which facilitates temporary applications of RBFPD and low cost should be considered. In the present case, cost of the treatment was lower than laboratory produced RBFPD restorations and conventional FPDs. Because restorations fabricated in a dental laboratory increases number of patient appointments.

High mechanical strength and translucency of the restorative materials are important considerations for anterior ceramic restorations.¹⁸ Alumina-based and zirconia-based ceramics have been the widely used in fabrication of all ceramic RBFPD.¹⁴⁻¹⁷ In-Ceram Alumina is an alumina-reinforced ceramic that has been used as a core material for crowns and anterior 3- unit FPDs since the early 1990s.¹¹ With adequate translucency and esthetical properties, this material is used in the fabrication of all-ceramic RBFPD.¹² However, clinical fractures experienced with In-Ceram RBFPDs.^{14,16} The most recent dental ceramic zirconia is also used in RBFPD as a core material. Zirconia can be used both anterior and posterior crowns and FPDs due to its superior mechanical properties. However due to its optical opacity, zirconia is used as core material and covered with veneering ceramics.¹⁸ The most cited mechanical complication with zir-

conia restorations is chipping of the veneer.²⁸ Besides high risk for chipping, veneering procedures makes chairside applications impossible.²⁹

In 1998, lithium disilicate ceramic (IPS Empress 2, Ivoclar Vivadent, Schaan, Liechtenstein) was introduced for single tooth and anterior three-unit FPD restorations.³⁰ This reinforced glass ceramic system utilized lost-wax press technique. Afterwards, IPS e.max Press (Ivoclar Vivadent, Schaan, Liechtenstein) with advanced optical and mechanical features, was introduced to the market in 2001.³⁰ The most recently introduced lithium disilicate material, IPS e.max CAD (Ivoclar Vivadent, Schaan, Liechtenstein), is a prefabricated block to be used in a CAD/CAM system.³⁰ Lithium disilicate ceramic is processed as pressed ceramic or milled from a blue intermediate phase (lithium metasilicate). The intermediate phase is milled by means of CAD/CAM systems. Complete crystallization of lithium metasilicate is achieved during firing. The final strength of the ceramic is obtained by crystallization. Lithium disilicate material provides esthetic outcomes due to its high translucency. Depending on high translucency,

monolithic use of lithium disilicate is possible for full anatomical restorations as well as the material can be used as a substructure material for layered esthetic restorations.³¹ Besides improved optical properties, lithium disilicate have a high flexural strength (360-400 MPa) compared with other ceramic materials.^{32,33} In the present case report, lithium disilicate was used to fabricate an all-ceramic RBFPD considering its superior optical and mechanical properties. Thanks to the chairside CAD/CAM production possibility of the material, the restoration was fabricated in a few hours. On the other hand, zirconia which is another high strength ceramic material used for fabrication of RBFPD, requires an additional laboratory step. Because zirconia is used as substructure material and veneering porcelain application is required.¹⁸ Thus, chairside use of zirconia is not feasible.

In the literature, limited numbers of studies are available regarding all-ceramic RBFPDs (Table 1). Ohlmann et al. delivered 30 RBFPDs, fabricated from yttria-stabilized zirconia veneered with fluorapatite glass ceramic, in 27 patients. After a 12-month follow-up period, 6 debondings, 3

TABLE 1: Survival rates of all-ceramic RBFPDs.

Author(s) (Year)	Material	Position*	Number of retainers	Number of		Follow-up period	Debonded prosthesis	Survival rate (%)
				Patients	Restorations			
Kern ¹⁴ (2005)	Glass-infiltrated alumina ceramic (In-Ceram) veneered with Vitadur Alpha	A	1 (21), 2 (16)	30	37	1 retainer: 52±17 (25-86) months 2 retainers: 76±46 (3-146) months	-	1 retainer: 92.3 2 retainers: 67.3
Ohlmann et al. ¹⁵ (2008)	Yttria-stabilized zirconia (IPS e.max ZirCAD) veneered with fluorapatite glass ceramic (IPS e.max ZirPress)	P	2	27	30	12 months	6	Delamination: 3 Chipping: 1 Framework fracture: 3
Kern and Sasse ¹⁶ (2011)	Glass-infiltrated alumina ceramic (In-Ceram)	A	1 (22), 2 (16)	30	38	1 retainer: 111±44 (37-171) months 2 retainers: 120±83 (3-231) months	-	1 retainer: 94.4 2 retainers: 67.3
Sasse et al. ¹⁷ (2012)	IPS e.max ZirCAD veneered with IPS e.max Ceram	A	1	25	30	41.7 (9.4-55.9) months	2	100 (including debonding: 93.1)
Sailer et al. ⁷ (2013)	IPS Empress or IPS e.max Press, veneered with IPS e.max Ceram in anterior	A,P	1	28	35	5.96 (0.31-13.5) years	-	100
Sun et al. ¹⁸ (2013)	IPS e.max Press	A	1	35	35	46.57 (35-69) months	-	100

A: Anterior; P: Posterior.

delaminations, 1 chipping and 3 framework fractures were reported.¹⁵ In a randomized clinical trial performed by Sasse et al., thirty anterior zirconia ceramic (IPS e.max ZirCAD veneered with IPS e.max Ceram) RBFDPs were prepared. During the follow-up period (mean: 41.7 months; min. 9.4, max. 55.9) two debondings were occurred.¹⁷ Reported three-year survival rate was 100%, however, with regarding debonding as a failure survival rate was 93.1%. In a study conducted by Sailer et al., 35 RBFDPs with substructures fabricated from IPS Empress or IPS e.max Press and veneered with IPS e.max Ceram were delivered to 28 patients in

anterior or posterior regions.⁷ According to the results of clinical follow-up examination of approximately 6 years, a survival rate of 100% was reported. Similarly, a survival rate of 100% was reported by Sun et al. after approximately 4-year clinical service of 35 anterior RBFDPs fabricated from IPS e.max Press.¹⁸

In the relevant literature, RBFDPs were also evaluated in terms of retainer type. Comparing single-retainer and two-retainer RBFDP designs, single-retainer RBFDPs showed higher success.^{14,16} In a clinical trial conducted by Kern, a total of 37 anterior RBFDPs in 30 patients were fabricated from

TABLE 2: Resin cements used for RBFDPs.

Brand Name	Manufacturer	Composition
Variolink II	Ivoclar Vivadent, Schaan, Liechtenstein	The monomer matrix is composed of Bis-GMA, urethane dimethacrylate, and triethylene glycol dimethacrylate. The inorganic fillers are barium glass, ytterbium trifluoride, Ba-Al-fluorosilicate glass, and spheroid mixed oxide. Additional contents: catalysts, stabilizers, and pigments. The particle size is 0.04–3.0 µm. The mean particle size is 0.7 µm.
Multilink Automix	Ivoclar Vivadent, Schaan, Liechtenstein	Multilink Automix: The monomer matrix is composed of dimethacrylate and HEMA. The inorganic fillers include barium glass, ytterbium trifluoride and spheroid mixed oxide. The particle size is 0.25–3.0 µm. The mean particle size measures 0.9 µm. The total volume of inorganic fillers is approximately 40%. Multilink Primer A and B: Multilink Primer A is an aqueous solution of initiators. Multilink Primer B contains HEMA, phosphonic acid and methacrylate monomers.
Panavia F 2.0	Kuraray, Okayama, Japan	A Paste: 10-Methacryloyloxydecyl dihydrogen phosphate (MDP), hydrophobic aromatic dimethacrylate, hydrophobic aliphatic methacrylate, hydrophilic aliphatic dimethacrylate, silanated silica filler, silanated colloidal silica, dl-camphorquinone, catalysts, initiators. B Paste: Hydrophobic aromatic dimethacrylate, hydrophobic aliphatic dimethacrylate, hydrophilic aliphatic dimethacrylate, silanated barium glass filler, surface treated sodium fluoride, catalysts, accelerators, pigments. Ed Primer II Liquid A: 2-Hydroxyethyl methacrylate (HEMA), 10-Methacryloyloxydecyl dihydrogen phosphate (MDP), water, n-methacryloyl-5-aminosalicylic acid [5-NMSA], accelerators. Liquid B: N-methacryloyl-5-aminosalicylic acid [5-NMSA], water, catalysts, accelerators. Oxyguard II: Glycerol, polyethyleneglycol, catalysts, accelerators, dyes.
Panavia 21	Kuraray, Okayama, Japan	Catalyst Paste: 10-Methacryloyloxydecyl dihydrogen phosphate (MDP), hydrophobic aromatic dimethacrylate, hydrophobic aliphatic methacrylate, silanated silica filler, colloidal silica, catalysts. Universal Paste: Hydrophobic aromatic dimethacrylate, hydrophobic aliphatic methacrylate, hydrophilic aliphatic dimethacrylate, silanated titanium oxide, silanated barium glass filler, catalysts, accelerators, pigments. Ed Primer II Liquid A: 2-Hydroxyethyl methacrylate (HEMA), 10-Methacryloyloxydecyl dihydrogen phosphate (MDP), water, n-methacryloyl-5-aminosalicylic acid [5-NMSA], accelerators. Liquid B: N-methacryloyl-5-aminosalicylic acid [5-NMSA], water, catalysts, accelerators. Oxyguard II: Glycerol, polyethyleneglycol, catalysts, accelerators, dyes.

glass infiltrated ceramic material (In-Ceram) with conventional or cantilevered design.¹⁴ They reported that no restorations were debonded. In single-retainer group 1 restoration was fractured and in two-retainer group 5 fractures were occurred. 5-year survival rates of 92.3% and 67.3% were recorded for single-retainer and two-retainer groups, respectively. In a similar clinical study, anterior In-Ceram RBFPDs were revealed 10-year survival rate of 94.4% for single retainer design, and 67.3% for two-retainer design.¹⁶ In two-retainer restorations the differential movement of the abutment teeth during the functional movements of the mandible has been indicated as reason for these outcomes.¹⁴ In single-retainer RBFPDs, the movement of pontic and abutment tooth occurs simultaneously; thus shear forces on the pontics and the connectors can be minimized.¹⁴ However, long term outcomes with single-retainer RBFPDs are still unclear. Long term randomized controlled clinical studies are required.

The adhesive cementation also plays an important role in the success of the RBFPDs. A sound bonding system not only ensures a strong retention

but also enhances the fracture strength of the restoration.¹¹ For adhesive cementation of the all-ceramic RBFPDs, various resin cements are available (Table 2). Although phosphate monomer containing resin cements are recommended for cementation of the restorations containing metal oxides such as alumina (Al_2O_3) and zirconium (ZrO_2),^{34,35} there is no consensus regarding the cementation of lithium disilicate based restorations. The main issue in cementation of these restorations is proper treatment of the ceramic surface including etching with hydrofluoric acid and subsequent silanization.

RBFPD is a minimally invasive, reversible, and cost effective restoration type for prosthetic management of single tooth loss. With the recent advances in dental ceramics, a wide range of esthetic and high strength ceramic materials is available for all-ceramic restorations. By choosing the most appropriate material, all-ceramic RBFPDs can provide highly esthetic and minimally invasive restorations in anterior single tooth replacements. Furthermore, due to the chairside CAD/CAM production, highly precise restorations can be fabricated in single appointment.

REFERENCES

- Hagiwara Y, Matsumura H, Tanaka S, Woelfel JB. Single tooth replacement using a modified metal-ceramic resin-bonded fixed partial denture: a clinical report. *J Prosthet Dent* 2004; 91(5):414-7.
- Adell R, Eriksson B, Lekholm U, Brånemark PI, Jemt T. Long-term follow-up study of osseointegrated implants in the treatment of totally edentulous jaws. *Int J Oral Maxillofac Implants* 1990;5(4):347-59.
- Wyatt CC. Resin-bonded fixed partial dentures: what's new? *J Can Dent Assoc* 2007; 73(10):933-8.
- Izgi AD, Kale E, Eskimez S. A prospective cohort study on cast-metal slot-retained resin-bonded fixed dental prostheses in single missing first molar cases: results after up to 7.5 years. *J Adhes Dent* 2013;15(1):73-84.
- Rochette AL. Attachment of a splint to enamel of lower anterior teeth. *J Prosthet Dent* 1973; 30(4 Pt 1):418-23.
- Aggstaller H, Beuer F, Edelhoft D, Rammelsberg P, Gernet W. Long-term clinical performance of resin-bonded fixed partial dentures with retentive preparation geometry in anterior and posterior areas. *J Adhes Dent* 2008; 10(4):301-6.
- Sailer I, Bonani T, Brodbeck U, Hämmelerle CH. Retrospective clinical study of single-retainer cantilever anterior and posterior glass-ceramic resin-bonded fixed dental prostheses at a mean follow-up of 6 years. *Int J Prosthodont* 2013;26(5):443-50.
- Livaditis GJ, Thompson VP. Etched castings: an improved retentive mechanism for resin-bonded retainers. *J Prosthet Dent* 1982; 47(1):52-8.
- Johnson GH, Lepe X, Zhang H, Wataha JC. Retention of metal-ceramic crowns with contemporary dental cements. *J Am Dent Assoc* 2009;140(9):1125-36.
- Barrack G, Bretz WA. A long-term prospective study of the etched-cast restoration. *Int J Prosthodont* 1993;6(5):428-34.
- Williams S, Albadri S, Jarad F. The use of zirconium, single-retainer, resin-bonded bridges in adolescents. *Dent Update* 2011;38(10):706-10.
- Kern M, Knode H, Strubb JR. The all-porcelain, resin-bonded bridge. *Quintessence Int* 1991;22(4):257-62.
- Reclaru L, Unger RE, Kirkpatrick CJ, Susz C, Eschler PY, Zuercher MH, et al. Ni-Cr based dental alloys; Ni release, corrosion and biological evaluation. *Mater Sci Eng C Mater Biol Appl* 2012;32(6):1452-60.
- Kern M. Clinical long-term survival of two-retainer and single-retainer all-ceramic resin-bonded fixed partial dentures. *Quintessence Int* 2005;36(2):141-7.
- Ohlmann B, Rammelsberg P, Schmitter M, Schwarz S, Gabbert O. All-ceramic inlay-retained fixed partial dentures: preliminary results from a clinical study. *J Dent* 2008; 36(9):692-6.
- Kern M, Sasse M. Ten-year survival of anterior all-ceramic resin-bonded fixed dental prostheses. *J Adhes Dent* 2011;13(5):407-10.

17. Sasse M, Eschbach S, Kern M. Randomized clinical trial on single retainer all-ceramic resin-bonded fixed partial dentures: Influence of the bonding system after up to 55 months. *J Dent* 2012;40(9):783-6.
18. Sun Q, Chen L, Tian L, Xu B. Single-tooth replacement in the anterior arch by means of a cantilevered IPS e.max Press veneer-retained fixed partial denture: case series of 35 patients. *Int J Prosthodont* 2013;26(2):181-7.
19. Van Zeghbroeck L. CAD/CAM treatment for the elderly--a case report. *Gerodontology* 2012;29(2):e1176-9.
20. Blatz MB, Ripps A, Sadan A, Holst S. Adhesive cementation of chairside CAD/CAM inlays and onlays. *Dent Today* 2006;25(1):60, 62-5.
21. Giordano R. Materials for chairside CAD/CAM-produced restorations. *J Am Dent Assoc* 2006;137(Suppl):14S-21S.
22. Levin L, Sadet P, Grossmann Y. A retrospective evaluation of 1,387 single-tooth implants: a 6-year follow-up. *J Periodontol* 2006;77(12):2080-3.
23. Cordaro L, Torsello F, Chen S, Ganeles J, Brägger U, Hämmerle C. Implant-supported single tooth restoration in the aesthetic zone: transmucosal and submerged healing provide similar outcome when simultaneous bone augmentation is needed. *Clin Oral Implants Res* 2013;24(10):1130-6.
24. Scholander S. A retrospective evaluation of 259 single-tooth replacements by the use of Brånemark implants. *Int J Prosthodont* 1999;12(6):483-91.
25. Naert I, Koutsikakis G, Duyck J, Quirynen M, Jacobs R, van Steenberghe D. Biologic outcome of single-implant restorations as tooth replacements: a long-term follow-up study. *Clin Implant Dent Relat Res* 2000;2(4):209-18.
26. Gibbard LL, Zarb G. A 5-year prospective study of implant-supported single-tooth replacements. *J Can Dent Assoc* 2002;68(2):110-6.
27. Hwang D, Wang HL. Medical contraindications to implant therapy: part I: absolute contraindications. *Implant Dent* 2006;15(4):353-60.
28. Baldassarri M, Stappert CF, Wolff MS, Thompson VP, Zhang Y. Residual stresses in porcelain-veneered zirconia prostheses. *Dent Mater* 2012;28(8):873-9.
29. Trindade FZ, Amaral M, Melo RM, Bottino MA, Valandro LF. Zirconia-porcelain bonding: effect of multiple firings on microtensile bond strength. *J Adhes Dent* 2013;15(5):467-72.
30. Schultheis S, Strub JR, Gerds TA, Guess PC. Monolithic and bi-layer CAD/CAM lithium-disilicate versus metal-ceramic fixed dental prostheses: comparison of fracture loads and failure modes after fatigue. *Clin Oral Investig* 2013;17(5):1407-13.
31. Schmitter M, Seydler BB. Minimally invasive lithium disilicate ceramic veneers fabricated using chairside CAD/CAM: a clinical report. *J Prosthet Dent* 2012;107(2):71-4.
32. Kim JH, Lee SJ, Park JS, Ryu JJ. Fracture load of monolithic CAD/CAM lithium disilicate ceramic crowns and veneered zirconia crowns as a posterior implant restoration. *Implant Dent* 2013;22(1):66-70.
33. Seydler B, Rues S, Müller D, Schmitter M. In vitro fracture load of monolithic lithium disilicate ceramic molar crowns with different wall thicknesses. *Clin Oral Investig* 2014;18(4):1165-71.
34. Kern M, Wegner SM. Bonding to zirconia ceramic: adhesion methods and their durability. *Dent Mater* 1998;14(1):64-71.
35. Mehta D, Shetty R. Bonding to zirconia: elucidating the confusion. *Int Dent SA* 2010;12(2):46-52.