

A Rare Cause of Haematuria: Implantation of Placental Villous Structures into Detrusor Muscle Following Probe Curettage: Case Report

Nadir Bir Hematüri Nedeni: Küretaj Sonrası Detrüsör Kası İçerisine Placental Villus Yapılarının İmplantasyonu

Ömer YILMAZ,^a
Ali YILMAZ,^b
Zeki AKTAŞ,^a
Ercan MALKOÇ,^a
Ferhat ATEŞ^a

Clinics of

^aUrology,

^bGynecology and Obstetrics,

GATA Haydarpaşa Training Hospital,
İstanbul

Geliş Tarihi/Received: 27.03.2014

Kabul Tarihi/Accepted: 18.08.2014

Yazışma Adresi/Correspondence:

Ömer YILMAZ

GATA Haydarpaşa Training Hospital,

Clinic of Urology, İstanbul,

TÜRKİYE/TURKEY

dr_omeryilmaz@yahoo.com

ABSTRACT A 40 year-old woman with massive haematuria due to implantation of placental villus structures into detrusor muscle following curettage was reported. Haematuria has started one month after the curettage procedure. Abdominal ultrasonography revealed hematoma formation in the bladder. Gynecologic examination was normal. Because of persistent haematuria, cystoscopy was performed. A mucosal defect and flap was seen on the bladder neck. Transurethral resection and fulguration were performed for histopathologic examination. An urethral catheter was introduced for 10 days. Postoperative period was uneventful. To the best of our knowledge, this is the first case, which had massive haematuria because of implantation of placental villous structures into detrusor muscle as an iatrogenic trauma during curettage procedure. Evaluation of haematuria after such gynaecologic procedures must include cystoscopy.

Key Words: Hematuria; curettage; injuries; iatrogenic disease

ÖZET Küretaj sonrası plasental villüs yapılarının detrüsör kası içerisine implantasyonu nedeni ile masif hematüri gelişen 40 yaşında kadın hasta sunulmuştur. Küretajdan 1 ay sonra başlayan ve son 10 günde yoğunlaşan hematüri şikayeti nedeni ile yapılan ultrasonografide mesane içerisinde hematoma tespit edildi. Jinekolojik muayenesi normal olan hastaya hematürinin devam etmesi nedeni ile sistoskopi yapıldı. Mesane boynu yakınında mukozal bir defekt ve flep görüldü kanama odağı bu defekt olarak değerlendirildi. Mukozal flep transüretral rezeksiyon ile alındı ve kanama kontrolü için fulgurasyon yapıldı. Hematürisi düzelen hasta 10 gün sonda ile takibin ardından taburcu edildi. Alınan örneğin patolojisi plasental villüs yapıları olarak rapor edildi. Olgumuz literatürde plasental villüs yapılarının iatrojenik olarak implante olduğu ve masif hematüri oluşturduğu ilk vakadır. Jinekolojik bir girişimin ardından gelişen hematüri değerlendirmesi için sistoskopi mutlaka göz önünde bulundurulmalıdır.

Anahtar Kelimeler: Hematüri; küretaj; yaralanmalar; iatrojenik hastalık

Türkiye Klinikleri J Urology 2014;5(2):54-7

There are some well-known causes of macroscopic haematuria in urology; such as cancer, infection, stone and trauma.¹⁻⁴ Besides them, there are also some rare conditions like gynecological and obstetrical procedures resulting in iatrogenic urological traumas.⁵ Clinical approach to haematuria includes taking history, physical examination,

biochemical tests, imaging and cystoscopy/ureterorenoscopy.^{6,7} In this report, a 40 year-old woman with massive haematuria due to implantation of placental villous structures into detrusor muscle following curettage was reported.

CASE REPORT

A 40 year-old woman, who underwent curettage one month ago in an obstetrics and gynecology clinic due to unintended pregnancy, was admitted to our clinic with massive haematuria. Her macroscopic haematuria was permanent for the last ten days and very intensive for the last two days.

Despite the normal physical examination, biochemical analyses showed that beta-Human Chorionic Gonadotropin (Beta-HCG) levels were increased (280 IU/ml), hematocrit (21.6%) and hemoglobin (7.38 g/dl) levels were decreased. Her history revealed a caesarean section 2 years ago. She was not a smoker and did not have any comorbidity either.

Abdominal ultrasonography revealed hematoma formation in the posteroinferior part of the bladder with no other sonographic pathologies. A 3-way urethral catheter was introduced and her bladder was irrigated with 0.9% NaCl solution via this transurethral catheter. Afterwards she was hospitalized for blood transfusion and follow-up.

Gynecologic examination was normal and there was no vaginal bleeding. By the way, a 2x2 cm intramural myoma in posterior wall of uterus, and hematoma formation with irregularity on posterior bladder wall were detected with transvaginal ultrasonography. Daily follow-up of beta-HCG was suggested.

The patient was kept under surveillance for the following 2 days. Although 4 units erythrocyte suspension were transfused, massive haematuria continued. Abdominopelvic computerized tomography (CT) (Figure 1) was carried out for further evaluation and differential diagnosis. Once again, hematoma formation in the bladder

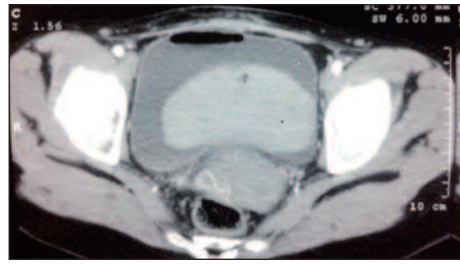


FIGURE 1: Pelvic tomography showing hematoma formation in the bladder.

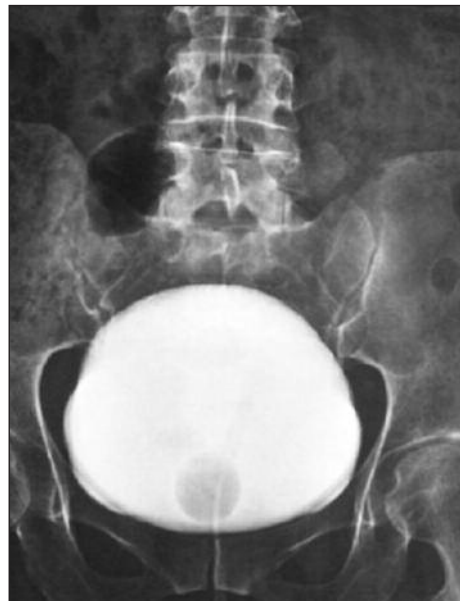

FIGURE 2: Cystography after transurethral resection and fulguration showing no extravasation.

(See color figure at <http://www.turkiyeklinikleri.com/journal/uroloji-dergisi/1309-632X/>)

figured out with CT. The area between bladder and uterus was normal in contrast to the area bladder and vagina. However no other pathologies explaining macroscopic haematuria could be figured out with CT.

Because of persistent haematuria, cystoscopic evaluation was performed under general anaesthesia. There was a huge hematoma formation in the bladder, and a 1-cm diameter mucosal defect and a mucosal flap were seen on the bladder neck at 5 o'clock position. Bleeding origin was at the bottom of this defect. Pathologic sampling and fulguration

with transurethral resection (TUR) was performed from the mucosal flap and irregular parts of the lesion. There were no additional pathological findings in the bladder. Haematuria disappeared after cystoscopy and fulguration. She was followed up for 10 days with foley urethral catheter then checked with cystography (Figure 2). After the integrity of the bladder proved, the urethral catheter was extracted.

In the postoperative period Beta-HCG levels gradually decreased. Histopathologic examination of the lesions revealed wide necrotic areas and degenerated placental villous formations. There were no histopathologic signs of bladder structures (Figure 3).

DISCUSSION

Iatrogenic urinary system injuries in gynecological surgeries, one of the less common causes of haematuria, occur with a frequency of 3%.⁸ The incidence is even lesser in curettage procedures.⁹

To the best of our knowledge, this is the first case, which had massive haematuria because of implantation of placental villous structures into detrusor muscle as an iatrogenic trauma during curettage procedure.

The onset of bleeding was at the first month of curettage procedure. It is presumed that it was due to patient's menstrual cycle and related hormonal changes.

Iatrogenic injuries in gynecological operations are seldom but important reasons of haematuria. It

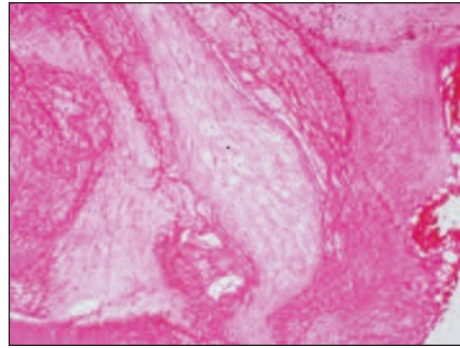


FIGURE 3: The image of histopathologic examination of the resected material: Placental villous structure (HE, x40).

(See color figure at <http://www.turkiyeklinikleri.com/journal/uroloji-dergisi/1309-632X/>)

seems that evaluation of haematuria following such gynaecological procedures must include cystoscopic evaluation in addition to other imaging modalities. Some studies put an emphasis on the need of intraoperative cystoscopic control if there is any doubt.⁹

Garcia et al. reported in their case that uterus and bladder were repaired with open surgery. But in our case, conservative treatment with fulguration and catheterization was enough and there was no need for open surgery.¹⁰

In conclusion, we must keep iatrogenic urinary traumas in our mind when evaluating haematuria especially in the patients who previously underwent gynaecological instrumentation and/or operation. In such cases, it is necessary to perform cystoscopy besides imaging modalities. If the defect is small, it can be treated by conservative approaches.

REFERENCES

1. Oosterlinck W, Solsona E, van der Meijden AP, Sylvester R, Böhle A, Rintala E, et al.; European Association of Urology. EAU guidelines on diagnosis and treatment of upper urinary tract transitional cell carcinoma. *Eur Urol* 2004;46(2):147-54.
2. Lee CT, Katz J, Fearn PA, Russo P. Mode of presentation of renal cell carcinoma provides prognostic information. *Urol Oncol* 2002;7(4): 135-40.
3. Brandt B, Ostri P, Lange P, Kvist Kristensen J. Painful caliceal calculi. The treatment of small nonobstructing caliceal calculi in patients with
4. symptoms. *Scand J Urol Nephrol* 1993;27(1): 75-6.
4. Buchberger W, Penz T, Wicke K, Eberle J. [Diagnosis and staging of blunt kidney trauma. A comparison of urinalysis, i.v. urography, sonography and computed tomography]. *Rofo* 1993;158(6):507-12.

5. El-Tabey NA, Ali-El-Dein B, Shaaban AA, El-Kappany HA, Mokhtar AA, El-Azab M, et al. Urological trauma after gynecological and obstetric surgeries. *Scand J Urol Nephrol* 2006; 40(3):225-31.
6. Shen X. Diagnostic algorithm for the evaluation of hematuria. *J Am Acad Nurse Pract* 2010;22(4):186-91.
7. Margulis V, Sagalowsky AI. Assessment of hematuria. *Med Clin North Am* 2011;95(1): 153-9.
8. Bouya PA, Odzébé AW, Otiobanda FG, Itoua C, Mahoungou-Guimbi K, Banga MR, et al. [Urological complications of gynecologic surgery]. *Prog Urol* 2011;21(12):875-8.
9. Gilmour DT, Dwyer PL, Carey MP. Lower urinary tract injury during gynecologic surgery and its detection by intraoperative cystoscopy. *Obstet Gynecol* 1999;94(5 Pt 2): 883-9.
10. Madrid García FJ, Madroñero Cuevas C, Rivas Escudero JA, Parra Muntaner L, Monsalve Rodríguez M, García Alonso J. [Bladder perforation as a complication of uterine curettage after spontaneous abortion]. *Arch Esp Urol* 2004;57(5):552-4.