

# Coexistence of Pemphigus Vulgaris with Hashimoto's Thyroiditis: Case Report

## Haşimoto Tiroiditi ile Birliktelik Gösteren Bir Pemfigus Vulgaris Olgusu

Ülker GÜL, MD,<sup>a</sup>  
Seçil SOYLU, MD,<sup>a</sup>  
Seray KÜLCÜ ÇAKMAK, MD,<sup>a</sup>  
Aylin OKÇU HEPER, MD<sup>b</sup>

<sup>a</sup>2<sup>nd</sup> Dermatology Clinic,  
Ankara Numune Education and  
Research Hospital,

<sup>b</sup>Department of Pathology,  
Ankara University School of Medicine,  
Ankara

Geliş Tarihi/Received: 13.03.2007  
Kabul Tarihi/Accepted: 05.06.2007

Yazışma Adresi/Correspondence:  
Seçil SOYLU, MD  
Ankara Numune Education and  
Research Hospital  
2<sup>nd</sup> Dermatology Clinic, Ankara  
TÜRKİYE/TURKEY  
secil.soylu@isnet.net.tr

**ABSTRACT** A 41 year-old man applied with bullae and erosions, persisting for two months. The laboratory tests were within normal limits except increased antithyroid peroxidase and antithyroglobulin antibody levels. The ultrasonographic examination of thyroid showed an enlarged gland with a homogeneous parenchyma, and the case was appraised as Hashimoto's thyroiditis with euthyroidism. HLA-A1, -A3, -B7, -B35, -Bw6, -Bw4, -Bw7, -DR4, -DR14, -DR52, -DR53 were detected in HLA genotyping. The histopathological and direct immunofluorescent examinations of skin lesions were consistent with pemphigus vulgaris. The therapy of pemphigus vulgaris with azathiopurine and prednisolone was started, and the patient is still being followed up. We present this case as the coexistence of pemphigus vulgaris with Hashimoto's thyroiditis has rarely been reported in the literature. And we believe that further studies of HLA can shed light on genetical base of this uncommon association.

**Key Words:** Pemphigus; thyroiditis, autoimmune; HLA antigens

**ÖZET** Kırk bir yaşında erkek hasta 2 ay önce başlamış olan vücutta yaygın bül ve erode lezyonlarla kliniğimize başvurdu. Serumda antitiroid peroksidaz ve antitiroglobulin antikor seviyeleri yüksekliği haricinde tüm laboratuvar testleri normal sınırlarda tespit edildi. Tiroid ultrasonografisinde homojen parankime sahip genişlemiş tiroid glandı gözlemlendi ve hasta Haşimoto tiroiditi olarak tanı aldı. HLA genotiplendirmesinde HLA-A1, -A3, -B7, -B35, -Bw6, -Bw4, -Bw7, -DR4, -DR14, -DR52, -DR53 bulundu. Lezyonların histopatolojik ve direkt immünfloresan incelemelerinde pemfigus vulgaris ile uyumlu idi. Azatiopurin ve prednizolon tedavisi başlandı ve hasta şu anda bu tedavi ile takip edilmektedir. Haşimoto tiroiditi gibi pemfigus vulgaris birlikteliğinin nadir gözlenmesi nedeniyle bu vakayı sunmaktayız. Pemfigus vulgaris ile otoimmün tiroidit birlikteliğinde HLA ile ilgili ileri araştırmaların faydalı olabileceğine inanıyoruz.

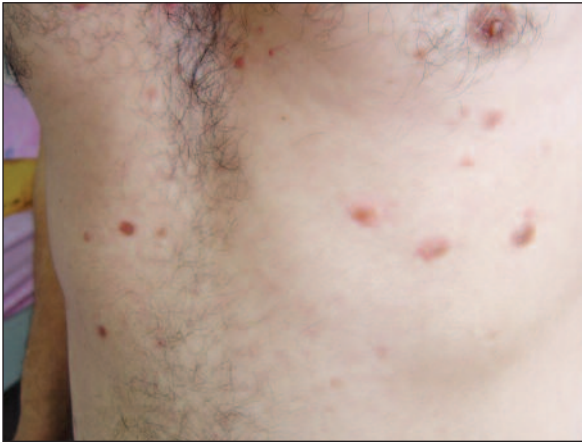**Anahtar Kelimeler:** Pemfigus; otoimmün tiroidit; HLA antijenleri

**Türkiye Klinikleri J Dermatol 2009;19(1):51-3**

**P**emphigus vulgaris is an autoimmune blistering disease of the skin of unknown etiology. Associations with various diseases, especially with other autoimmune diseases have been reported. However, there have been rare case reports of pemphigus vulgaris associated with autoimmune thyroid diseases.

### CASE REPORT

A 41 year-old man presented with bullae and erosions that was persisting for two months. The patient had no history of intake of any drugs. The der-



**FIGURE 1:** The bullae at the interscapular area of patient.

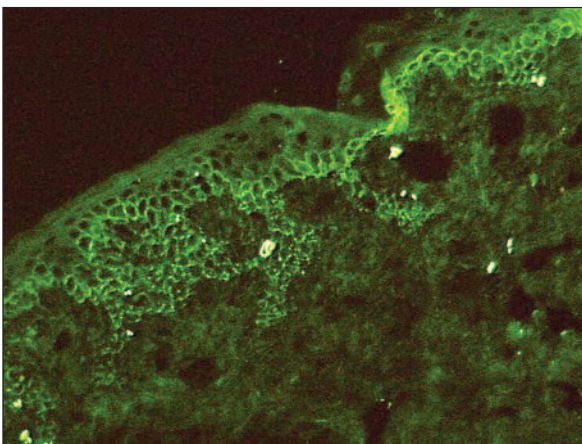
matologic examination revealed erosions and bullae on his presternal area, interscapular area and upper extremities (Figure 1). The erythrocyte sedimentation rate, whole blood count, fasting blood sugar level, liver and kidney function tests, thyroid function tests, hepatitis markers, anti-human immunodeficiency antibodies, rheumatoid factor, anti-nuclear antibodies were within normal limits. Antithyroid peroxidase antibody (anti-TPO Ab) level was 119.4 IU/mL (normal, 0-34 IU/mL), antithyroglobulin (anti-Tg) antibody level was 1067 IU/mL (normal, 0-115 IU/mL). The ultrasonographic examination of thyroid showed an enlarged gland with a homogeneous parenchyma. The case was appraised as Hashimoto's thyroiditis with euthyroidism.

The histopathological examination of the skin lesions revealed the diagnosis of pemphigus vulgaris. Direct immunofluorescent studies revealed intercellular deposits of immunoglobulin G and complement 3 (Figure 2A and 2B). Human leucocyte antigen (HLA) genotyping was performed by polymerase chain reaction, and HLA-A1, -A3, -B7, -B35, -Bw6, -Bw4, -Bw7, -DR4, -DR14, -DR52, -DR53 were found.

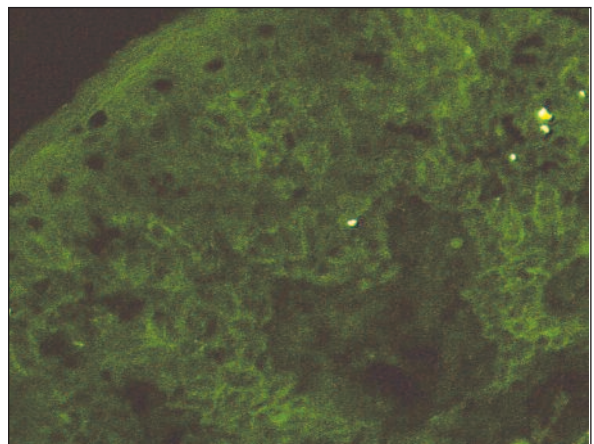
The therapy of pemphigus vulgaris with azathioprine and prednisone was initiated, and the patient is still being followed up.

## DISCUSSION

It appears that unknown factors, genetic or environmental trigger the production of the high titers of the pathogenic autoantibody that result in the development of clinical autoimmune diseases.<sup>1-3</sup> Autoimmune polyglandular syndromes (APS) have played an important role in understanding autoimmune disorders. APS is a rare constellation of autoimmune disorders characterised by more than one endocrine gland failure occurring in individuals and their families. In addition to endocrine glands, other non endocrine organs may be targeted by the immune system.<sup>4</sup> At least two or possibly more phenomenon may be involved in the pathogenesis.<sup>1,5</sup> The first is creation of pathogenetic T or B cells reacting with components of more than one tissue. The second is an inherited abnormal



**A**



**B**

**FIGURE 2.** A and B. Intercellular depositions of IgG and C3 on DIF examination.

function, predisposing to the loss of tolerance to a series of self antigens. Given such a predisposition, normal alleles of HLA genes within the major histocompatibility complex may then lead to targeting of specific organs. Different diseases are often associated with the same or similar HLA genotypes and thus would increase the co-occurrence of the disorders.<sup>6</sup>

HLA A10, -A11, -B22, -DR4, -DRw14, and -DR6 were reported to be more frequent in pemphigus in some studies.<sup>1,7-9</sup> HLA-B35, B44, CW4, DR4, DR14, DQ4 and DQ8 antigens were found to be frequent in Turkish pemphigus patients, and our patient had HLA-DR4, DR14 antigens consistent with this study.<sup>10</sup>

There are also studies and case reports about association of autoimmune thyroid diseases and

pemphigus.<sup>11-13</sup> An increased prevalence of autoimmune thyroid diseases has been reported in the family members of patients with pemphigus. It is concluded that pemphigus vulgaris is highly associated with primary thyroid disorders, mainly with positive titers of anti-TPO-Ab, although most patients do not present overt clinical thyroid disease.<sup>13</sup>

We present this case because the coexistence of pemphigus vulgaris with Hashimoto's thyroiditis has rarely been reported in the literature. This association might be related to shared antigen that can result in targeting of multiple tissues, and inherited abnormalities of immune function. We believe that the further studies on HLA can lead a light on genetical base of this uncommon association.

## REFERENCES

1. Firooz A, Mazhar A, Ahmed AR. Prevalence of autoimmune diseases in the family members of patients with pemphigus vulgaris. *J Am Acad Dermatol* 1994;31(3 Pt 1):434-7.
2. Tur E, Brenner S. Contributing exogenous factors in pemphigus. *Int J Dermatol* 1997; 36(12):888-93.
3. Tur E, Brenner S. Diet and pemphigus. In pursuit of exogenous factors in pemphigus and fogo selvagem. *Arch Dermatol* 1998;134(11):1406-10.
4. Wallaschofski H, Meyer A, Tuschy U, Lohmann T. HLA-DQA1\*0301-associated susceptibility for autoimmune polyglandular syndrome type II and III. *Horm Metab Res* 2003;35(2):120-4.
5. Bias WB, Reveille JD, Beaty TH, Meyers DA, Arnett FC. Evidence that autoimmunity in man is a Mendelian dominant trait. *Am J Hum Genet* 1986;39(5):584-602.
6. Eisenbarth GS. Autoimmune polyendocrine syndromes. *Adv Exp Med Biol* 2004;552:204-18.
7. Niizeki H, Inoko H, Narimatsu H, Takata H, Sonoda A, Tadakuma T, et al. HLA class II antigens are associated with Japanese patients. *Hum Immunol* 1991;31(4):246-50.
8. Stanley JR. Pemphigus. In: Freedberg IM, Eisen AZ, Wolff K, eds. *Fitzpatrick's Dermatology in General Medicine*. 6th ed. New-York: McGraw-Hill; 2003. p.558-67.
9. Kavak A, Aydoğan I, Gonen S. Simultaneous onset of pemphigus vulgaris in two Turkish siblings. *J Dermatol* 2005;32(3):186-8.
10. Birol A, Anadolu RY, Tutkak H, Gurgey E. HLA-class 1 and class 2 antigens in Turkish patients with pemphigus. *Int J Dermatol* 2002; 41(2):79-83.
11. Iino Y, Hara H, Suda T, Okada T, Baba S, Suzuki H. Co-existence of pemphigus vulgaris and Hashimoto's thyroiditis. *Eur J Dermatol* 2005;15(1):40-2.
12. Bartalena L, Bogazzi F, Chiovato L, Tanda ML, Martino E. Graves' hyperthyroidism and ophthalmopathy associated with pemphigus vulgaris: Onset of thyroid autoimmune disease during chronic low-dose glucocorticoid therapy. *J Endocrinol Invest* 1997;20(3): 155-7.
13. Pitoia F, Moncet D, Glorio R, Graciela Diaz A, Rodriguez Costa G, Carbia S, et al. Prevalence of thyroid autoimmunity in patients with pemphigus vulgaris. *Medicina (B Aires)* 2005;65(4):307-10.