

Posterior Capsular Pigment Deposition: A Rare Presentation of Pigment Dispersion Syndrome

Posterior Kapsüler Pigment Birikimi: Pigment Dispersiyon Sendromunun Nadir Bir Prezantasyonu

^{ib} Yasemin ÜN^a, ^{ib} Abdurrahman Çağrı GÜR^a, ^{ib} Serhat İMAMOĞLU^a, ^{ib} Gökhan ÇELİK^b

^aClinic of Ophthalmology, İstanbul Haydarpaşa Numune Training and Research Hospital, İstanbul, Türkiye

^bClinic of Ophthalmology, İstanbul Zeynep Kamil Women and Children Diseases Training and Research Hospital, İstanbul, Türkiye

ABSTRACT A 41-year-old white male patient with right posterior lenticular pigmentation detected during a routine ophthalmologic workup 2 months before was referred for further evaluation. On ophthalmic examination, the visual acuity was 20/20 without correction in both eyes. Biomicroscopy revealed bilateral Kruckenberg spindles and right inferior posterior subcapsular pigmentation, with no transillumination defects. Fundus examination displayed symmetric cupping of 0.4 bilaterally. Intraocular pressure was 20 mmHg in the right eye and 18 mmHg in the left. Gonioscopy showed a bilaterally open angle with dense, uniform pigmentation and the concave iris position. Inter-zonular and equatorial lens pigmentation was also remarkable bilaterally. Ultrasound biomicroscopy revealed no solitary or cystic lesions of the iris and ciliary body. In conclusion, based on the ophthalmologic findings and after ruling out cystic or solid intraocular mass lesion leading to pigment dispersion, we diagnosed the case as an atypical presentation of pigment dispersion syndrome.

Keywords: Pigment dispersion syndrome; lens pigmentation; pigmentary glaucoma; posterior lens capsule

ÖZET Kırk bir yaşında erkek hasta 2 ay önce rutin oftalmolojik muayenesinde sağ posterior lentiküler pigmentasyon saptanması üzerine ileri tetkik amacı ile yönlendirildi. Oftalmolojik muayenede görme keskinliği bilateral tashihsiz tamdı. Biyomikroskopide, bilateral Kruckenberg içiği ve sağ inferior posterior subkapsüler pigmentasyon saptandı, transillüminasyon defekti saptanmadı. Fundus muayenesinde bilateral simetrik 0,4 çukurluk izlendi. Göz içi basıncı sağda 20 mmHg, solda 18 mmHg idi. Goniyskopide bilateral yoğun ve uniform pigmente açık aç ve konkav iris pozisyonu saptandı. İnterzonuler alanda ve lensin ekvatoryal bölgesinde pigment birikimleri mevcut idi. Ultrasonik biyomikroskopide iris ve siliyer cisimde soliter veya kistik bir lezyon saptanmadı. Sonuç olarak, oftalmolojik bulgularla birlikte, kistik veya soliter iris ve siliyer cisim lezyonunu dışlayarak, vakamın pigment dispersiyon sendromunun ati pik bir prezantasyonu olduğuna karar verdik.

Anahtar Kelimeler: Pigment dispersiyon sendromu; lens pigmentasyonu; pigmenter glokom; posterior lens kapsülü

Pigment dispersion syndrome (PDS) is characterized by the dispersion of pigment from the iris pigment epithelium and its deposition on the anterior segment structures like endothelium, iris surface and trabeculum.^{1,2} The typical findings include Kruken-

berg spindle, iris transillumination, heavy trabecular meshwork pigmentation, and a concave iris on gonioscopy.^{3,4} The underlying pathophysiology is thought to be related to mechanical rubbing between the posterior surface of the concave iris and the ante-

Correspondence: Yasemin ÜN

Clinic of Ophthalmology, İstanbul Haydarpaşa Numune Training and Research Hospital, İstanbul, Türkiye

E-mail: malkocyasemin@hotmail.com



Peer review under responsibility of Türkiye Klinikleri Journal of Ophthalmology.

Received: 28 Feb 2023

Received in revised form: 21 Jul 2023

Accepted: 23 Jul 2023

Available online: 21 Aug 2023

2146-9008 / Copyright © 2023 by Türkiye Klinikleri. This is an open access article under the CC BY-NC-ND license (<http://creativecommons.org/licenses/by-nc-nd/4.0/>).

rior lens surface or zonules and consecutive release of pigment granules from the iris pigment epithelium.^{5,6} Detecting PDS is important because it can lead to elevated intraocular pressure (IOP) and pigmentary glaucoma (PG), ultimately resulting in visual loss.¹ A lifetime risk of PDS progressing to PG has been estimated between 35 and 50%.^{1,3}

In a recent report, the 4-year-conversion rate of PDS to PG was found to be 37.5%.⁷ The majority of patients with PDS are asymptomatic; only a small proportion of them may complain of intermittent blurred vision, halos around light sources, and headaches.³ PDS typically affects myopic patients aged between 20 and 40 years and is equally seen in men and women but glaucoma is more frequently encountered in men.¹ Early detection of PDS and regular follow-ups to detect a glaucomatous damage is important to hinder disease progression, glaucomatous damage, and vision loss.¹

In the current case, we present an atypical presentation of PDS.

CASE REPORT

All authors declare that informative consent was obtained from the patient to publish this case report and all the information and images belong to the case.

A 41-year-old male patient was referred by an ophthalmologist for a detailed examination and ultrasonic biomicroscopy (UBM) due to a pigmented posterior capsular lesion in his right eye. On the ophthalmologic examination, his past medical history was significant only for a mild coronavirus disease-2019 (COVID-19) infection, which occurred 2 years prior and the patient had no history of trauma.

The visual acuity was 20/20 without any correction, bilaterally. IOP was 20 mmHg in the right eye and 18 mmHg in the left eye. Light reactions were positive and pupils were symmetric. The anterior segment examination was significant with bilateral central vertically oriented endothelial pigment deposition without transillumination defect. After pupil dilatation, dense inferior posterior capsular pigmentation was observed in the right eye (Figure 1). The left dilated anterior segment examination was found to be insignificant. Fundus examination showed no signif-

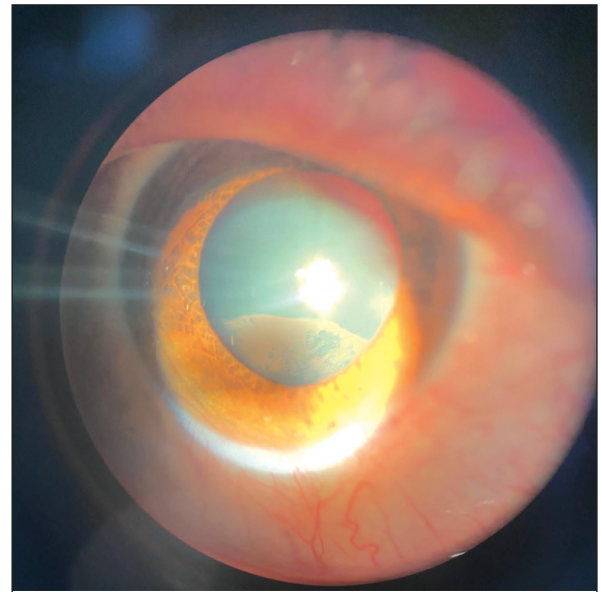


FIGURE 1: Slit lamp biomicroscopic photograph of the right eye showing pigment deposits on the posterior capsule of the lens.

icant findings. On gonioscopic examination, the angle was wide open with heavy pigmentation bilaterally (Figure 2). No mass lesion was observed posterior to the iris. In addition to right posterior capsular pigmentation, there was bilateral pigmentation around the lens equator, between the zonular fibers.

UBM (Ellex Medical, Adelaide, Australia), macular optical coherence tomography (OCT) (Topcon, Tokyo, Japan), retinal nerve fiber layer thickness (RNFL) measurement, and visual field test (Carl Zeiss Ophthalmic Systems, Inc., Dublin, CA) were performed. UBM revealed normal iris, lens, and ciliary body architecture bilaterally, with no mass lesions (Figure 3). OCT results were normal. The mean RNFL thickness was 101 μm and 109 μm in the right and the left eye, respectively. On the Central 24-2 Threshold visual field test, no scotoma was found.

Considering the patient's history, findings of the ophthalmological examination, and imaging results, we arrived at the diagnosis of an atypical presentation of PDS. The patient was ascertained that no mass lesion was found, but follow-ups and IOP measurements with 4-month intervals were suggested to screen for probable glaucomatous changes.




FIGURE 2: Gonioscopy photographs of the right and left eyes of the patient showing uniform and dense pigmentation of an open angle.
R: Right eye; L: Left eye.

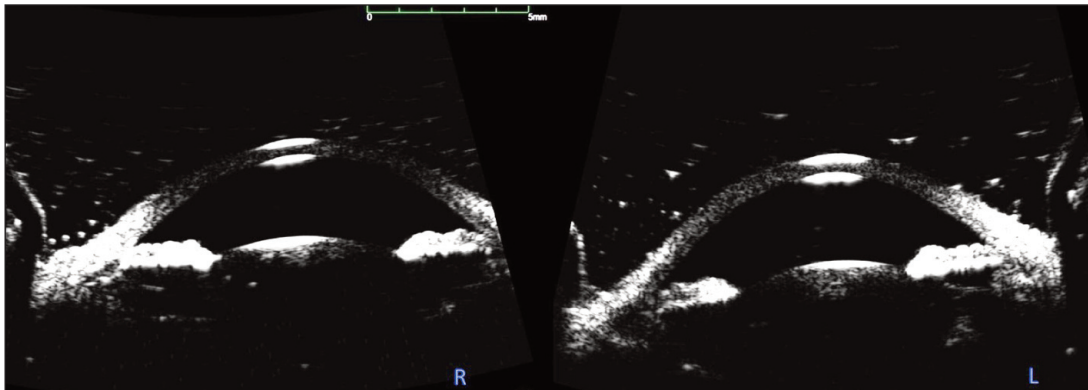


FIGURE 3: Ultrasonic biomicroscopy photographs belonging to the right and left eyes of the patient with normally appearing anterior segment architecture.
R: Right eye; L: Left eye.

DISCUSSION

Normal eye anatomy does not allow aqueous humor to flow through the posterior lens capsule due to the anterior hyaloideocapsular ligament, known as the ligament of Weiger, which provides a firm adhesion between the periphery of the lens capsule and anterior hyaloid. There have been reports of unilateral and bilateral pigment deposition on the posterior lens capsule without a history of trauma.⁵⁻¹¹ In the classic presentation of PDS, pigmentation of the lens capsule is seen in the periphery of the lens, known as Scheie's or Zentmayer's line.^{2,4} To detect more central posterior capsular pigmentation there must be an anatomical anomaly or a defect in the ligament of

Wieger to allow aqueous flow from the posterior chamber to the retrolental space.

In our case, the patient was referred to us with right posterior capsular pigment deposition, which was found to be suspicious of iris or ciliary body cyst or tumor. However, our examination findings of bilateral Krukenberg spindle, bilateral dense trabecular pigmentation, and anterior zonular and capsular pigmentation were consistent with PDS. Moreover, UBM scans did not reveal any mass lesions. On the UBM scans, iris concavity was observed in the left eye (Figure 4).

The patient's past medical history was only significant for a mild COVID-19 disease without

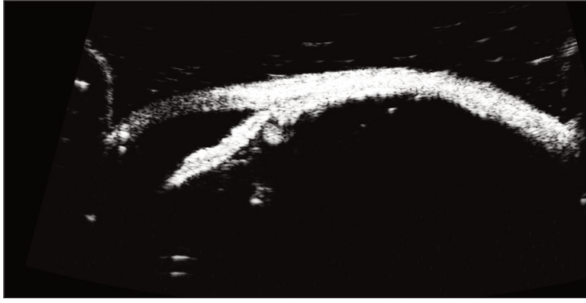


FIGURE 4: Ultrasonic biomicroscopy photo belonging to the left eye of the patient showing iris concavity and iris-lens touch.

hospitalization, occurring 2 years ago. His complaints about his eyes were not very significant and he complained of intermittent mild photophobia and discomfort after the COVID-19 infection which neither peaked nor ceased. In the literature, there are some reports of bilateral acute iris depigmentation and bilateral acute transillumination following the COVID-19 infection.^{12,13} The clinical presentation for both situations is more significant with iridocyclitis findings. When we detailed ocular history, the case did not indicate any redness or pain. The cause and effect relationship between the COVID-19 infection and PDS in this case is considered very weak. Therefore we diagnosed the case as idiopathic PDS associated with right,

inferior idiopathic defect in the ligament of Weiger.

This case represents a rare presentation of PDS, which should be kept in mind, and associated findings of PDS should be monitored.

Source of Finance

During this study, no financial or spiritual support was received neither from any pharmaceutical company that has a direct connection with the research subject, nor from a company that provides or produces medical instruments and materials which may negatively affect the evaluation process of this study.

Conflict of Interest

No conflicts of interest between the authors and / or family members of the scientific and medical committee members or members of the potential conflicts of interest, counseling, expertise, working conditions, share holding and similar situations in any firm.

Authorship Contributions

Idea/Concept: Yasemin Ün; **Design:** Yasemin Ün; **Control/Supervision:** Serhat İmamoğlu; **Data Collection and/or Processing:** Abdurrahman Çağrı Gür, Gökhan Çelik; **Analysis and/or Interpretation:** Yasemin Ün; **Literature Review:** Yasemin Ün; **Writing the Article:** Yasemin Ün; **Critical Review:** Yasemin Ün, Gökhan Çelik; **References and Fundings:** Gökhan Çelik, Serhat İmamoğlu.

REFERENCES

- Scuderi G, Contestabile MT, Scuderi L, Librando A, Fenicia V, Rahimi S. Pigment dispersion syndrome and pigmentary glaucoma: a review and update. *Int Ophthalmol.* 2019;39(7):1651-62. Erratum in: *Int Ophthalmol.* 2019. [Crossref] [PubMed]
- Okafor K, Vinod K, Gedde SJ. Update on pigment dispersion syndrome and pigmentary glaucoma. *Curr Opin Ophthalmol.* 2017;28(2):154-60. [Crossref] [PubMed]
- Niyadurupola N, Broadway DC. Pigment dispersion syndrome and pigmentary glaucoma—a major review. *Clin Exp Ophthalmol.* 2008;36(9):868-82. [Crossref] [PubMed]
- Yüksel NR. Pigment dispersiyon sendromu ve pigmenter glokom [Pigment dispersion syndrome and pigmentary glaucoma]. *Glo-Kat.* 2011;6(Özel Sayı):49-53. [Link]
- Turgut B, Türkçuoğlu P, Deniz N, Catak O. Annular and central heavy pigment deposition on the posterior lens capsule in the pigment dispersion syndrome: pigment deposition on the posterior lens capsule in the pigment dispersion syndrome. *Int Ophthalmol.* 2008;28(6):441-5. [Crossref] [PubMed]
- Lin DY, Volpicelli M, Singh K. Dense pigmentation of the posterior lens capsule associated with the pigment dispersion syndrome. *J Glaucoma.* 2003;12(6):491-3. [Crossref] [PubMed]
- Gomez Goyeneche HF, Hernandez-Mendieta DP, Rodriguez DA, Sepulveda AI, Toledo JD. Pigment dispersion syndrome progression to pigmentary glaucoma in a Latin American population. *J Curr Glaucoma Pract.* 2015;9(3):69-72. [Crossref] [PubMed] [PMC]
- Roberts DK, Miller E, Kim LS. Pigmentation of the posterior lens capsule central to Wieger's ligament and the Scheie line: a possible indication of the pigment dispersion syndrome. *Optom Vis Sci.* 1995;72(10):756-62. [Crossref] [PubMed]
- Nagarajiah S, Shun-Shin GA. Pigment deposition on the central aspect of the posterior lens capsule in pigmentary dispersion. *Digit J Ophthalmol.* 2011;17(4):69-71. [Crossref] [PubMed] [PMC]

10. Trampuž IŠ. A case of dense pigment deposition of the posterior lens capsule. *BMC Ophthalmol.* 2020;20(1):458. [[Crossref](#)] [[PubMed](#)] [[PMC](#)]
11. Canestraro J, Sherman J. Curvilinear, symmetrical, and profound pigment deposition on the posterior lens capsule in a patient with bilateral pigmentary dispersion syndrome. *Eye Brain.* 2018;10:79-84. [[Crossref](#)] [[PubMed](#)] [[PMC](#)]
12. Yüksel M, Özdemir HB, Özdek Ş, Gürelik G. Bilateral acute Iris transillumination after COVID-19 pneumonia. *Eur J Ophthalmol.* 2023;33(4):NP115-NP118. [[Crossref](#)] [[PubMed](#)] [[PMC](#)]
13. Gaur S, Sindhu N, Singh DV, Bhattacharya M, Sharma A, Shinde D. COVID-19-related bilateral acute de-pigmentation of iris with ocular hypertension. *Indian J Ophthalmol.* 2022;70(8):3136-9. [[Crossref](#)] [[PubMed](#)] [[PMC](#)]