

An Interesting Complication After the Transurethral Bladder Tumor Resection: Inflated Catheter Balloon Out of the Bladder

Transüretal Mesane Tümörü Rezeksiyonu Sonrası İlginç Bir Komplikasyon: Mesane Dışında Şişirilmiş Sonda Balonu

Erhan DEMİRELLİ^a,
Özkan ÖZEN^b,
Mehmet KARADAYI^a,
Ercan ÖĞREDEN^a,
Ural OĞUZ^a,
Orhan YALÇIN^a

^aDepartment of Urology,
Giresun University Faculty of Medicine,
Giresun, TURKEY

^bDepartment of Radiology,
Alanya Alaaddin Keykubat University,
Faculty of Medicine,
Antalya, TURKEY

Received: 29.07.2018

Received in revised form: 14.10.2018

Accepted: 15.10.2018

Available online: 28.12.2018

Correspondence:

Erhan DEMİRELLİ
Giresun University Faculty of Medicine,
Department of Urology, Giresun,
TURKEY/TÜRKİYE
erhandemirelli@yahoo.com

ABSTRACT Sixty five years old male patient who has been applied transurethral resection of bladder tumor (TUR-BT) and has been followed with an urethral catheter for three days. After removing the catheter, he has admitted to the emergency service with acute urinary retention and abdominal pain. After placing a 20F urethral catheter, the patient's abdominal pain has reduced and the patient has been discharged with own request with catheter. He was admitted to the out-patient clinic with no urine output and abdominal pain 12 hours after has discharged from the emergency department. A vesical globe was detected in the patient despite he has an urethral catheter. Ultrasonography (USG) revealed that the foley catheter was outside the bladder. The balloon was inflated outside the bladder and it was closing the hole on the bladder wall. The catheter balloon was evacuated and the catheter was pulled in the bladder. The conservative treatment was planned for the patient.

Keywords: Urinary bladder neoplasms; urinary catheterization; complications

ÖZET Altmış beş yaşında erkek hastaya transüretal mesane tümörü (TUR-MT) rezeksiyonu uygulandı ve üç gün boyunca üretral kateter ile takip edildi. Kateteri çıkardıktan sonra akut idrar retansiyonu ve abdominal ağrı ile acil servise başvurdu. 20F üretral kateter yerleştirildikten sonra hastanın karın ağrısı azaldı ve hasta kendi isteği ile sonralı olarak taburcu edildi. Acil servisten taburcu olduktan 12 saat sonra idrar çıkışı olmayışı ve abdominal ağrı ile polikliniğe başvurdu. Üretral kateteri olmasına rağmen, fizik muayenede glob vezikale tespit edildi. Ultrasonografide (USG) foley kateterin mesane dışında olduğu izlendi. Sonda balonu mesane dışında şişirilmiş ve mesane duvarındaki deliği kapatıyordu. Kateter balonu indirildi ve kateter mesaneye çekildi. Hastaya konservatif tedavi planlandı.

Anahtar Kelimeler: Mesane neoplazileri; üriner kateterizasyon; komplikasyonlar

The bladder perforation mostly occurs secondarily to the trauma or iatrogenically and rarely spontaneously.¹ When the reasons for the iatrogenic bladder perforation are considered, 61.5% develop due to gynecological operations, 26.2% develop due to general surgery operations and 12.3% develop due to urologic operations. The risk of perforation is high especially in TUR-BT among urologic operations. The bladder perforation is observed approximately at the rate of 6.5% after TUR-BT.^{2,3} Although foley catheterization in of the bladder is a widespread and safe operation, the bladder perforation developing due to catheterization is reported in a few cases in the literature.^{4,5} We aimed to introduce an interes-

ting presentation of the bladder perforation due to the foley catheterization after TUR-BT in this case.

CASE REPORT

The case is a 56-year old male patient. TUR-BT was performed due to the bladder tumor in December 2015. The pathology of the patient was reported as a high grade T1 transitional epithelium cellular bladder tumor. Then, second TUR-BT was applied to the patient in January 2016. After second TUR-BT, intravesical bacillus Calmette-Guérin (BCG) induction treatment was administered to the patient once a week during 6 weeks. The control cystoscopy was applied to the patient 15 days after the intravesical BCG treatment and suspected areas were resected. The patient has been followed with the catheter for three days and he was discharged from hospital by removing the catheter. On the day of discharge, the patient applied to the emergency service of the same clinic with the complaints of unable to urinate and abdominal pain. The urethral foley catheter was placed in the patient and routine blood tests were requested. Although the patient's creatinine value was measured as 2.04 mg/dl, he left the emergency service voluntarily with the catheter when his pain was relieved. Then, the patient applied to our polyclinic with the complaints of widespread abdominal pain and anuria for 12 hours. Widespread sensitivity in the abdomen and a vesical globe were identified during the physical examination of the patient. The vesical globe was observed in the bladder in ultrasonography (USG) applied to the patient. It was seen that the foley catheter was out of the bladder and the balloon was inflated out of the bladder (Figure 1). There was approximately 50-mm liquid collection in the perivesical area. Then, the catheter balloon was deflated accompanied by USG and the catheter was pulled in the bladder carefully. And then the catheter balloon was reinflated in the bladder. At this stage, 700 cc of urine was drained from the catheter. A significant improvement was observed in the complaints of the patient after urine drainage. Moreover, it was determined in the physical examination that the sensitivity in the abdomen almost completely disappear. Since the cli-

nic of the patient recovered dramatically, the conservative treatment was planned for the patient. The creatinine value decreased to 1,6 mg/dl on the day following the placement of the catheter in the bladder. It was seen in the USG conducted on the 3rd day after the procedure that perivesical liquid completely disappeared. The creatinine value decreased to 0,93 mg/dl. The catheter was removed when it was seen that there was no extravasation in the cystography on the 10th day (Figure 2).

The manuscript was written after the patient's written approval.

DISCUSSION

The bladder perforation occurs mostly traumatically or iatrogenically and rarely spontaneously. When the reasons for iatrogenic bladder perforation are considered, 61.5% develop due to gynecological operations, 26.2% develop due to general surgery operations and 12.3% develop due to urologic operations. The risk of perforation is high especially in the TUR-BT in the transurethral operations among urologic operations. The bladder perforation may be observed approximately at the rate of 6.5% after TUR-BT. The perforations that develop due to TUR-BT are mostly diagnosed during operation.^{2,3} The perforation in this case also occurred after TUR-BT. However, the fact that no perforation finding was noted during the operation and the actual suggestive findings of the perforation occurred after TUR-BT make us consider that

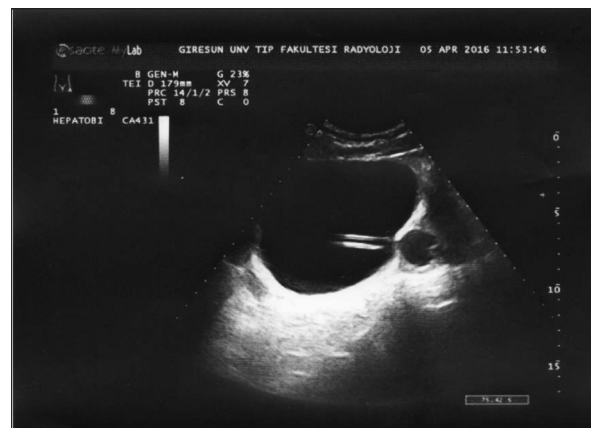


FIGURE 1: Inflated catheter balloon outside the bladder.

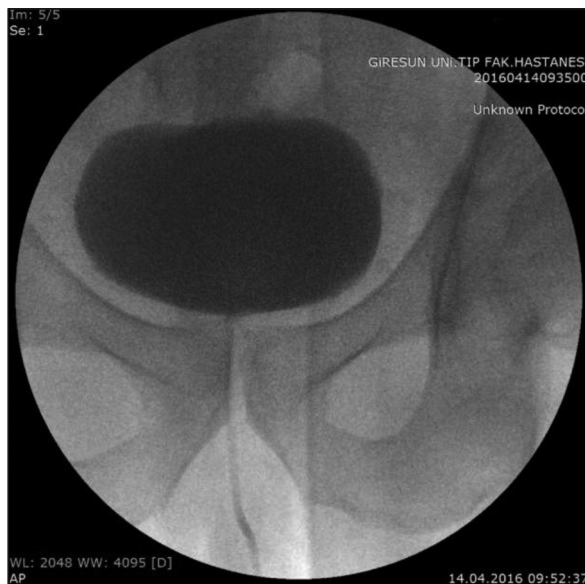

FIGURE 2: Cystography image taken after conservative treatment.

the bladder perforation has developed due to foley catheterization after the discharge.

The bladder perforation can be intraperitoneal or extraperitoneal. While the main symptom of the bladder perforation is macroscopic hematuria, non-specific symptoms such as peritonitis symptoms related to the peritoneal extravasated urine, uremia, acidosis and hypervolemia symptoms because of the extravasated urine reabsorption are observed. Therefore, usually, there are delays in the diagnosis and treatment.^{6,7} The fact that the patient had urine retention and the foley catheter balloon was inflated out of the bladder in USG, prevented the delays in the diagnosis in our case. The first creatinine value was measured as 2.04 mg/dl in our case. However, the facts that urine extravasation out of the bladder was not high, the patient had urine retention and the creatinine value decreased dramatically after the urine drainage support the hypothesis that the reason for the increase of creatinine is a postrenal renal failure that developed depending on urine retention.

The presence of urine in the bladder does not always exclude the bladder perforation. Although the patient was admitted to the polyclinic with the complaints of abdominal pain and urine retention in our case, a vesical globe was identified in the

physical examination. Although it was determined in the USG that the bladder was perforated, it was identified that the patient had urine retention. We consider that this retention is related to the fact that the catheter balloon was inflated out of the bladder and the catheter balloon closed the perforation in the bladder wall mechanically.

The bladder perforation that develops depending on the catheterization is rarely encountered in the literature. It is reported in the literature that the bladder perforation related to the catheter is observed in the patients to whom short-term repetitive catheterization is applied, applying clean intermittent catheterization (CIC) and having a long-term indwelling catheter or during urodynamics. Erosion caused by the catheter in the bladder wall is accepted as a preliminary factor in the patients with the long-term indwelling catheter. Moreover, the bladder tumor itself, thinning in the wall after the bladder surgery, pelvic radiation therapy, inflammation in the bladder wall and bladder outlet obstruction are accepted as predisposing factors for the bladder rupture by creating damage in the bladder wall.^{6,8-12}

It is reported in the literature that catheters made from hard materials such as silicon cause bladder perforation. Since especially the increase in the diameter will increase the hardness of the catheter, this risk is higher in thick catheters. Vaidyanathan et al. reported a bladder perforation case that developed after the placement of a 22F silicon catheter. In this case, they accepted the bladder wall inflammation related to multiple sclerosis and a hard 22F silicon catheter as preliminary factors for the perforation.¹³ Furthermore, although the catheter placed in our case was an 18F soft rubber catheter, we consider that the bladder wall perforation was caused by the bladder wall thinning after TUR-BT.

Computed tomography (CT) and retrograde cystography are the main imaging methods in the bladder perforation.¹⁴ Since the catheter was observed out of the bladder in USG in our case, the diagnosis of the bladder perforation was directly made, and CT or retrograde cystography was not considered necessary.

Although there are those who support emergency laparotomy in the treatment of the bladder perforation, there are also authors who support that the conservative treatment must be applied primarily.^{5,15} While especially retroperitoneal perforations are mostly treated conservatively, a surgical operation is mostly needed in intraperitoneal perforations.^{1,6} Moreover, there are those who prefer the conservative approach in the intraperitoneal perforation. People supporting the conservative approach usually report the fact that a dramatical improvement occurs after the urine drainage in the patient is a supported finding in terms of the conservative approach.^{11,12} The catheter balloon which was inflated out of the bladder in our case was deflated by USG vision and reinflated after it was placed in the bladder. A significant improvement was observed in the complaints of the patient after urine drainage. Moreover, it was identified in the physical examination that severe sensitivity in the abdomen decreased. Therefore, we applied the conservative treatment to the patient.

Source of Finance

During this study, no financial or spiritual support was received neither from any pharmaceutical company that has a direct connection with the research subject, nor from a company that provides or produces medical instruments and materials which may negatively affect the evaluation process of this study.

Conflict of Interest

No conflicts of interest between the authors and / or family members of the scientific and medical committee members or members of the potential conflicts of interest, counseling, expertise, working conditions, share holding and similar situations in any firm.

Authorship Contributions

Ideas/Concept: Erhan Demirelli, Ercan Öğreden, Ural Oğuz; **Design:** Erhan Demirelli, Ural Oğuz; **Control/Supervision:** Orhan Yalçın; **Data Collection and/or Processing:** Erhan Demirelli, Özkan Özen, Mehmet Karadayı; **Analysis and/or Interpretation:** Erhan Demirelli, Ural Oğuz; **Literature Review:** Erhan Demirelli, Mehmet Karadayı; **Writing the Article:** Erhan Demirelli; **Critical Review:** Orhan Yalçın, Ural Oğuz; **Materials:** Özkan Özen.

REFERENCES

- Cusano A, Abarzua-Cabezas F, Meraney A. Spontaneous bladder perforation unrelated to trauma or surgery. *BMJ Case Rep* 2014 Jun 12. pii: bcr2014204161. Doi: 10.1136/bcr-2014-204161.
- Armenakas NA, Pareek G, Fracchia JA. Iatrogenic bladder perforations: longterm followup of 65 patients. *J Am Coll Surg* 2004;198(1):78-82.
- Compløj E, Dechet CB, Mian M, Trenti E, Palermo S, Lodde M, et al. Perforation during TUR of bladder tumours influences the natural history of superficial bladder cancer. *World J Urol* 2014;32(5):1219-23.
- Bozgeyik Z, Kocakoc E, Aglamis S, Ogur E. Perforation of the urinary bladder wall by Foley catheter. *JBR-BTR* 2013;96(4):210-1.
- Jambet S, Facy O, Landreau P, Duperron C, Kretz B. Intraperitoneal rupture of the bladder after urinary catheterization. *Clin Pract* 2011;1(4):e109.
- Mitchell T, Al-Hayek S, Patel B, Court F, Gilbert H. Acute abdomen caused by bladder rupture attributable to neurogenic bladder dysfunction following a stroke: a case report. *J Med Case Rep* 2011;5:254.
- Kivlin D, Ross C, Lester K, Metro M, Ginsberg P. A case series of spontaneous rupture of the urinary bladder. *Curr Urol* 2015;8(1):53-6.
- Farraye MJ, Seaberg D. Indwelling foley catheter causing extraperitoneal bladder perforation. *Am J Emerg Med* 2000;18(4):497-500.
- Reisman EM, Preminger GM. Bladder perforation secondary to clean intermittent catheterization. *J Urol* 1989;142(5):1316-7.
- Khavari R, Bayne AP, Roth DR. A report of an iatrogenic bladder rupture in a normal healthy child during voiding cystourethrography. *Urology* 2010;75(3):684-6.
- Merguerian PA, Erturk E, Hulbert WC Jr, Davis RS, May A, Cockett AT. Peritonitis and abdominal free air due to intraperitoneal bladder perforation associated with indwelling urethral catheter drainage. *J Urol* 1985;134(4):747-50.
- Spees EK, O'Mara C, Murphy JB, Michigan S, Newton CG. Unsuspected intraperitoneal perforation of the urinary bladder as an iatrogenic disorder. *Surgery* 1981;89(2):224-31.
- Vaidyanathan S, Hughes PL, Mansour P, Soni BM. Burrowing of urinary bladder wall by the tip of a size 22 Fr silicone foley catheter in an adult male patient with multiple sclerosis and suprapubic cystostomy: should caution be exercised in using a size 22 Fr silicone foley catheter for long-term drainage of neuropathic bladder? *Cases J* 2008;1(1):25.
- Alhamzawi HH, Abdelrahman HM, Abdelrahman KM, El-Menyar A, Al-Thani H, Latifi R. Delayed presentation of traumatic intraperitoneal rupture of urinary bladder. *Case Rep Urol* 2012;2012:430746.
- Craggs B, Michielsen D. Conservative treatment of an intraperitoneal bladder perforation. *Cent European J Urol* 2011;64(1):47-9.