

Metastatic Carcinoma of Temporomandibular Joint: Clinical and Imaging Features of a Case

Temporomandibular Eklem Metastatik Karsinomu: Bir Olgunun Klinik ve Radyografik Özellikleri

Meryem ETÖZ,^a
Elif TARIM ERTAŞ,^a
Halil ŞAHMAN,^a
Yıldırım ŞİŞMAN,^a
Ganime ÇOBAN^b

^aDepartment of Maxillofacial Radiology,
Erciyes University Faculty of Dentistry,

^bDepartment of Pathology,
Erciyes University Faculty of Medicine,
Kayseri

Geliş Tarihi/Received: 23.05.2012

Kabul Tarihi/Accepted: 12.09.2012

Yazışma Adresi/Correspondence:

Meryem ETÖZ
Erciyes University Faculty of Dentistry,
Department of Maxillofacial Radiology,
Kayseri,
TÜRKİYE/TURKEY
meryemetoz@hotmail.com

ABSTRACT A 40 year-old man applied to our clinic complaining of a non-healing tooth abscess for the duration of more than 2 months. Extra oral examination of the patient revealed a painful firm expansion in the right parotis region with ipsilateral palpable fixed submandibular lymph nodes. There was no sign of acute abscess with respect to the dentition in intra oral examination. A panoramic radiograph of the patient showed an undefined radiolucent area at the ramus of the mandible above the mandible foramen and lytic areas within an enlarged right mandibular condyle. A subsequent magnetic resonance imaging and computed tomography scan of the lesion were consistent with malignancy. In this study, we present a very unusual and unique case of metastasis in the temporomandibular joint which was the first clinical manifestation of inguinal region malignancy in the patient. Interpretation of conventional radiographs with application of advanced imaging modalities plays crucial role in determining malignant lesions of jaws.

Key Words: Neoplasm metastasis; mandible; temporomandibular joint

ÖZET 40 yaşında erkek hasta 2 aydır iyileşmeyen diş apsesi şikâyeti ile kliniğimize başvurmuştur. Hastanın ağız dışı muayenesinde sağ parotis bölgesinde palpasyonda sert kıvamlı, ağırlı ekspansiyonu ve aynı taraf submandibular bölgede sert kıvamlı, fiks lenf düğümleri tespit edildi. Ağız içi muayenesinde diş kaynaklı akut apse bulgusu mevcut değildi. Panoramik radyografita litik alanlar içeren genişlemiş kondil başı ile birlikte mandibular ramusu tutan ve foramen mandibula üzerinde sınırları belirsiz radyolüsent alanlar görüldü. Magnetik rezonans ve bilgisayarlı tomografi görüntüleri malin lezyon lehine değerlendirildi. Bu çalışmada, çok sıradışı ve eşsiz bir olgu olan inguinal bölge malignitesinin ilk klinik bulgusu olan temporomandibular eklem metastazı sunuldu. Radyografların yorumlanması ve ileri görüntüleme teknikleri ile desteklenmesi malign lezyonların tespit edilmesinde önemli bir role sahiptir.

Anahtar Kelimeler: Tümör metastazı; mandibula; temporomandibüler eklem

Türkiye Klinikleri J Dental Sci 2014;20(1):66-70

Transfer of diseased cells from an organ or other part of the body to another location which is not directly related with it is described as metastasis and it is generally an inherent feature of a malignant tumor.¹

Regional lymph nodes are more predominantly involved compared to distant organs and oral structures are rarely affected from a metastasizing tumor which originates in a distant location.^{2,3} It has been reported that almost 1% of oral cancers within soft tissues and jaws are metastases of primary tumors of other parts of the body.⁴ The reason why metastasis in the

jaws is rarely detected may be due to lack of symptoms, omitting the maxilla and mandible during skeletal surveys and missing the examination of the jaws entirely at autopsy.⁵ Clinical findings of a metastatic tumor mimics common dentoalveolar complaints as toothache, osteomyelitis, temporomandibular joint disorder, trigeminal neuralgia, periodontal problems or other benign conditions. In addition, involvement of the inferior alveolar nerve of a malignant tumor may present altered sensation which is known as the numb chin syndrome (NCS) in the literature.⁴

In this study, we present a very unusual and unique case of metastasis in the temporomandibular joint (TMJ) which was the first clinical manifestation of inguinal region malignancy in the patient.

CASE REPORT

A 40-year-old male patient applied to our clinic complaining of a tooth abscess which had been present for two months and had not recovered despite treatment with antibiotics. As for his family history, we learned that his mother had died from pancreatic cancer. The patient had been suffering for a long time from exhaustion and backache problems. In the extra oral examination a solid, painful nodule was detected in the right retromandibular area. A solid, fixed lymph node was detected in the right submandibular region (Figure 1). Physical examination of TMJ revealed that maximum interincisal opening and lateral movements were in the range of normal limits. Intraoral examination revealed lack of tooth-related acute abscess but root remnants were observed in the right second molar and the left second molar regions; profound caries was observed in the right third molar tooth. A panoramic radiograph of the patient showed an irregular radiolucent area causing enlargement in the right mandibular condyle. In addition, bone destruction was observed in the condylar neck of the right TMJ to the sigmoid notch (Figure 2). A malign lesion infiltrating the masseter muscle and the infratemporal fossa, extending from the right caput mandibulae to the ramus, and causing damage to the bone structure was detected in the patient's

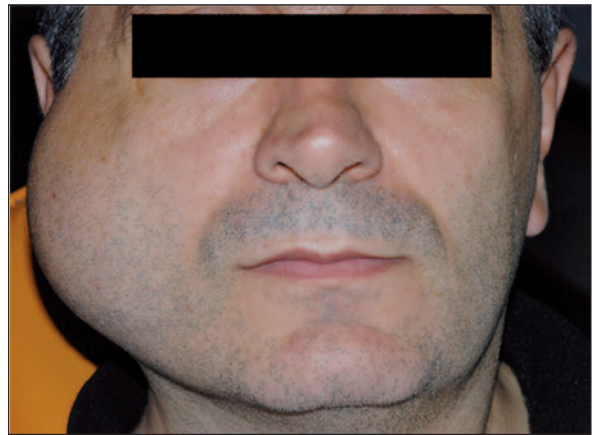

FIGURE 1: Extraoral view of the patient revealed significant swelling of the right cheek.

(See color figure at

<http://www.turkiyeklinikleri.com/journal/dis-hekimligi-bilimleri-dergisi/1300-7734/>)

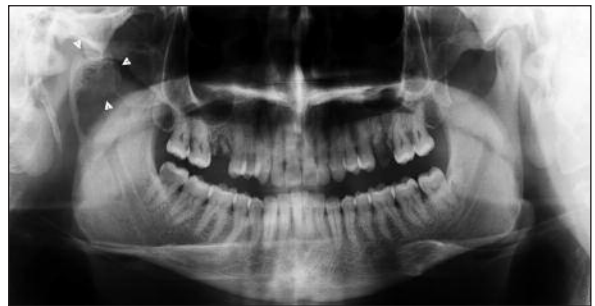

FIGURE 2: Panoramic radiograph revealed border of the enlarged condylar head (arrow heads).

computer tomography (CT) and magnetic resonance imaging (MRI) (Figure 3-6). The patient was informed about the lesion and referred to the ENT clinic. The histopathological diagnosis of the lesion was identified as malign epithelial tumor (Figure 7A, B). A soft tissue mass with 14x10 dimensions which considered to be the primary tumor was detected in the inguinal region with positron emission tomography. In the case presented here, TMJ metastasis was the first sign of the underlying disease, malign epithelial tumor of the inguinal region. Unfortunately, the patient died one year after diagnoses due to widespread bone and bone marrow metastasis.

DISCUSSION

In the maxillofacial region, metastatic tumors with hard tissue lesions occur more often than those

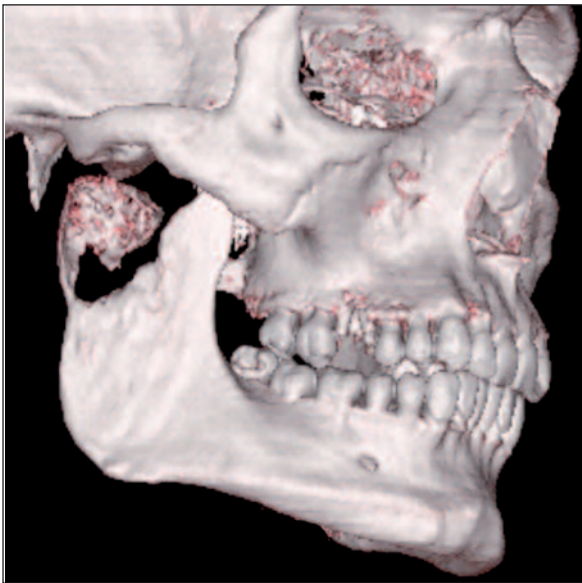

FIGURE 3: Three-dimensional reconstruction image revealed TMJ metastasis affected the condyle and ramus of the right mandible.

(See color figure at

<http://www.turkiyeklinikleri.com/journal/dis-hekimligi-bilimleri-dergisi/1300-7734/>)

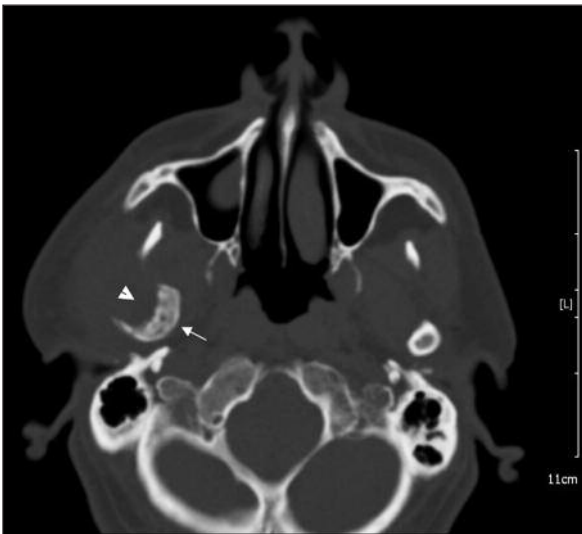

FIGURE 4: Axial CT scan (in bone window) revealed crescent shaped condyle with bone production (arrow) and destruction (arrow head).

with soft tissue lesions.^{3,6} The lung and kidney are the most frequent focus of metastases to the oral soft tissues, while the breast is the most frequent focus for the jaw bones.⁷⁻⁹ The primary location of the tumor varies between genders; in females breast cancer is the most common cause of metastatic oral cancer, while lung and prostate cancer, respectively are the most common cause in males.

Also, the primary site differs with age. The adrenal gland is the most common primary location in the first decade and bone is the most common primary location in the second decade of life. In increasing age groups, the breast was reported to be the primary site for women and the lung and the prostate, respectively, were reported to be the primary sites for men.⁹

The mandibular molar region is the most frequently affected location in the maxillofacial area in terms of metastatic tumors.⁹ However, of all the

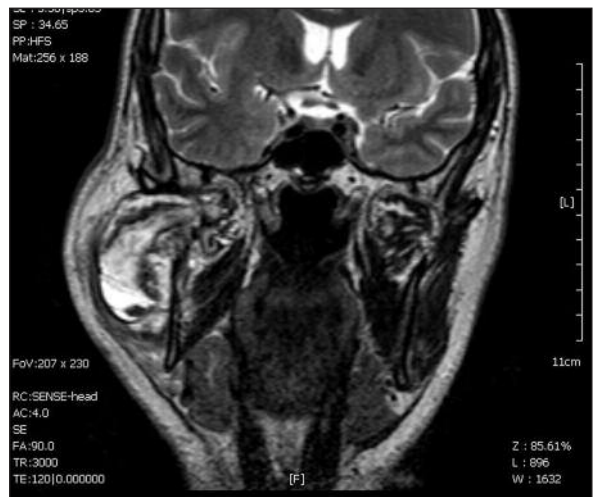

FIGURE 5: MRI (T2 weighted image, coronal view) revealed the malign tumor infiltrating the masseter, lateral pterygoid muscle and causing destruction in the mandible.

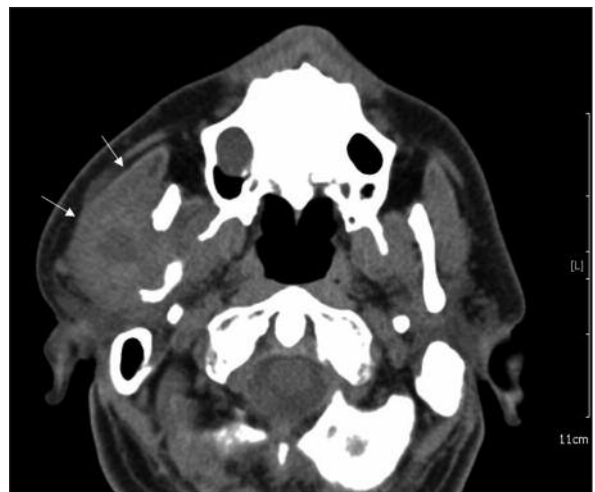


FIGURE 6: Axial CT scan (in soft tissue window) revealed malignant lesion infiltration to the masseter muscle (arrows).

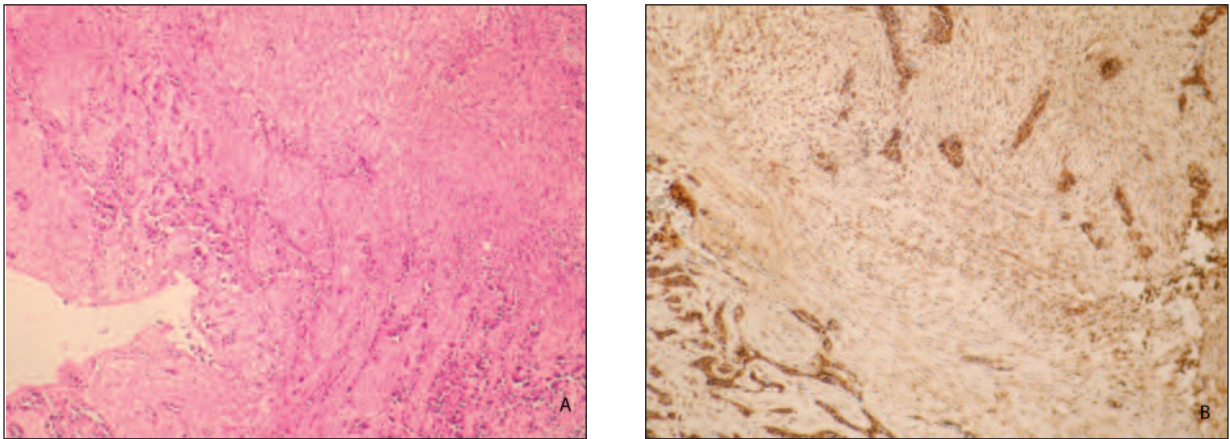


FIGURE 7: A) Tumoral cells form cords in the fibrotic stroma with Hematoxylin-eosin stain, original augmentation 20X. **B)** Pathological anatomy. Immunohistochemistry, positive staining in the tumoral structure with vimentin, original augmentation 20X.

(See color figure at <http://www.turkiyeklinikleri.com/journal/dis-hekimligi-bilimleri-dergisi/1300-7734/>)

metastatic cancers and tumors in this area, metastasis to the whole maxillomandibular complex constitutes only 1% of all cases.¹⁰ In the present case, the ramus and condylar region of the mandible were both widely affected by overlapping symptoms. The clinical symptoms of a mandibular metastasis include reflecting pain in the molar region and less frequently in the TMJ region. The pain may be misdiagnosed as an osteomyelitis or as trigeminal neuralgia in the jaws.¹¹ The rapid development of swelling, trismus, parasthesia and possible pathological fracture are other reported clinical manifestations in the literature.⁹ In the present case, according to the initial clinical and radiographical findings, differential diagnosis may include avascular necrosis of mandible, idiopathic condylar resorption, osteomyelitis or bisphosphonate related necrosis of jaws or primary tumor of the condylar region. One of the most common symptom of a malignant metastatic tumor within mandible may be altered feel of sensation of inferior alveolar nerve.⁹ NCS is a sensory neuropathic condition consisting of numbness of the chin in the distribution of the mental nerve and the branches of the mandibular division of the trigeminal nerve.¹² This finding may be the first sign of an initial cancer or could be an indication of the spread of an already established tumor.¹² Our patient had experienced pain and swelling without paresthesia as the metastatic tumor had been located above the mandible foramen.

It has been reported that more than 80% of malignant tumors have been seen as radiolucent and/or lytic areas in radiographs while fewer tumors may be seen as mixed or radiopaque lesions. However 5.4% of tumors did not reveal any pathological changes in the bones of the affected jaws and the exact diagnosis was only made following surgical examination. For this reason, lack of radiographic findings does not eliminate the probability of small metastatic cumulations in the jaws.^{9,13} In the present case, the radiographic appearance was obvious which was probably due to the late stage of the disease. Although the crucial role of advanced imaging with CT and MRI has been implicated, radiographical findings should be supported with correct clinical aspect as in some circumstances advanced imaging techniques may fail to recognize malignant conditions.¹⁴

Conventional imaging alone might be insufficient due to possible artifacts or anatomical variations. In order to reveal early findings of metastasis such as further radiographic examination osseous scintigraphy, single photon emission computed tomography and CT are important options.^{11,15,16}

In this patient the primary tumor was detected with single photon emission computed tomography and TMJ metastasis was the first sign of the malign epithelial tumor of the inguinal region.

Early findings of metastatic tumors in the maxillofacial region eventually lead to the discovery of an unknown malignant lesion.⁹ In the present case the persistent symptoms of the disease had been misdiagnosed with dental infections which may be considered as the possible reason for the relatively wider and more invasive lesion. A

metastatic tumor may be accompanied with overlapping symptoms. Dental symptoms should be carefully evaluated both in a clinical and advanced radiological manner to detect possible early metastatic malignant disease and to increase survival rate. Advanced imaging modalities should be applied to suspicious cases to prevent misdiagnosis.

REFERENCES

1. Dorland WA. Dorland's Illustrated Medical Dictionary. 30th ed. Philadelphia, PA: Elsevier Saunders; 2003. p.1138.
2. Anil S, Lal PM, Gill DS, Beena VT. Metastasis of thyroid carcinoma to the mandible. Case report. Aust Dent J 1999;44(1):56-7.
3. Hirshberg A, Buchner A. Metastatic tumours to the oral region. An overview. Eur J Cancer B Oral Oncol 1995;31B(6):355-60.
4. Orhan K, Bayndr H, Aksoy S, Seker BK, Berberoğlu A, Ozan O. Numb chin syndrome as a manifestation of possible breast cancer metastasis around dental implants. J Craniofac Surg 2011;22(3):942-5.
5. Rohrer MD, Colyer J. Mental nerve paresthesia: symptom for a widespread skeletal metastatic adenocarcinoma. J Oral Surg 1981; 39(6):442-5.
6. Reyes Court D, Encina S, Levy I. Prostatic adenocarcinoma with mandibular metastatic lesion: case report. Med Oral Patol Oral Cir Bucal 2007;12(6):E424-7.
7. Bodner L, Sion-Vardy N, Geffen DB, Nash M. Metastatic tumors to the jaws: a report of eight new cases. Med Oral Patol Oral Cir Bucal 2006;11(2):E132-5.
8. Yasar F, Oz G, Dolanmaz D, Akgünlü F. Mandibular metastasis in a patient with pulmonary adenocarcinoma. Dentomaxillofac Radiol 2006;35(5):383-5.
9. Hirshberg A, Leibovich P, Buchner A. Metastatic tumors to the jawbones: analysis of 390 cases. J Oral Pathol Med 1994;23(8):337-41.
10. Rubin MM, Jui V, Cozzi GM. Metastatic carcinoma of the mandibular condyle presenting as temporomandibular joint syndrome. J Oral Maxillofac Surg 1989;47(5):507-10.
11. Glaser C, Lang S, Pruckmayer M, Millesi W, Rasse M, Marosi C, et al. Clinical manifestations and diagnostic approach to metastatic cancer of the mandible. Int J Oral Maxillofac Surg 1997;26(5):365-8.
12. Narendra H, Ray S. Numb chin syndrome as a manifestation of metastatic squamous cell carcinoma of esophagus. J Cancer Res Ther 2009;5(1):49-51.
13. Akan H. [Imaging of temporomandibular joint]. Türkiye Klinikleri J Radiol-Special Topics 2008;1(1):29-37.
14. Sasaki M, Yamazaki H, Aoki T, Ota Y, Sekiya R, Kaneko A. Bilateral numb chin syndrome leading to a diagnosis of Burkitt's cell acute lymphocytic leukemia: a case report and literature review. Oral Surg Oral Med Oral Pathol Oral Radiol Endod 2011;111(3):e11-6.
15. Akarslan ZZ, Kocabay C, Akar V, Gültekin G, Akyürek N. [B-Cell lymphoma lesions localized on the mandible: Case report]. Türkiye Klinikleri J Dental Sci 2008; 14(1):52-6.
16. Gündüz ŞG, Coşkun HŞ. [Use of molecular diagnostics in clinical oncology: Head and neck cancers]. Türkiye Klinikleri J Med Oncol-Special Topics 2011;4(2):26-31.