

Protective Role of Nigella Sativa Oil on Experimental Liver Injury in Rats

RATLARIN DENEYSEL KARACİĞER HASARI ÜZERİNDE ÇÖREKOTU YAĞININ KORUYUCU ROLÜ

Mustafa ZERİN, MD,^a A. Ziya KARAKILÇIK, MD,^a Yaşar NAZLIGÜL, MD,^b Muharrem BİTİREN, MD,^c H. İlyas ÖZARDALI, MD,^c Davut MUSA^d

Departments of ^aPhysiology, ^bInternal Medicine, ^cPathology, Faculty of Medicine, ^dDepartment of Biology, Faculty of Arts and Science, University of Harran, ŞANLIURFA

Abstract

Objective: Carbon tetrachloride (CCl₄) is a hepatotoxic agent used to make experimental hepatic injury. Nigella Sativa Oil (NSO) may decrease the oxidation of lipids and lipoproteins by scavenging free radicals in cellular components. Therefore, the aim of the present study was to investigate the possible protective role of NSO on activities of enzymes and on injury of the liver tissue in rats.

Material and Methods: This study was carried out on sixty Wistar albino rats divided into equally three groups. The first group was received only physiologic saline (0.9% NaCl) as a control, the second group was intraperitoneally (IP) injected carbon tetrachloride (0.15 mL/kg-body weight) and the third group was injected CCl₄ (0.15 mL/kg) plus NSO (1 mL/kg-body weight). All treatments were received three times in a week for a period of the seven weeks.

Results: While plasma activities of aspartate aminotransferase (AST), alanine aminotransferase (ALT), alkaline phosphatase (ALP) and gamma glutamyl transferase (GGT) were statistically increased (p< 0.05 to p< 0.01) with CCl₄ injection. The levels of AST, ALT and ALP were statistically decreased (p< 0.01, p< 0.05 and p< 0.05, respectively) with the treatments of NSO. Histopathologically, the liver sections of rats treated with NSO showed reduction in liver damage.

Conclusion: Based upon these results, NSO may play a protective role in the diminution of hepatic cellular injury produced by CCl₄.

Key Words: Liver, injury, enzymes, carbon tetrachloride, nigella sativa, rats

Özet

Amaç: Karbon tetraklorür, deneysel karaciğer hasarı oluşturmak için kullanılan hepatotoksik bir ajandır. Çörekotu yağı ise hücrel bileşenlerdeki serbest radikalleri tutarak lipid ve lipoproteinlerin oksidasyonunu azaltabilir. Bu nedenle, sunulan çalışmanın amacı ratların karaciğer doku hasarı ve enzimleri üzerinde çörekotu yağının olası koruyucu rolünü araştırmaktır.

Gereç ve Yöntemler: Çalışma, 3 eşit gruba ayrılan 60 adet Wistar albino cinsi rat üzerinde yürütüldü. Birinci gruba sadece fizyolojik serum verildi ve kontrol grubu olarak kullanıldı. İkinci gruba intraperitoneal (IP) olarak karbon tetraklorür (0.15 mL/kg) enjekte edildi; üçüncü gruba ise IP karbon tetraklorür ve oral olarak çörekotu yağı (1 mL/kg) verildi. Tüm uygulamalar 7 hafta süre ile haftada 3 kez uygulandı.

Bulgular: Aspartat aminotransferaz (AST), alanin aminotransferaz (ALT), alkalın fosfataz (ALP) ve gamma glutamil transferaz (GGT) düzeyleri karbon tetraklorür enjeksiyonu ile istatistiksel olarak yükselirken tedavi grubunda AST, ALT ve ALP düzeyleri azaldı. Çörekotu yağı uygulaması ile ratların karaciğer hasarında azalma gözlemlendi.

Sonuç: Karbon tetraklorür ile oluşturulan karaciğer hücrel hasarının azaltılmasında çörekotu yağı koruyucu bir rol oynayabilir.

Anahtar Kelimeler: Karaciğer hasarı, enzimler, karbon tetraklorür, çörekotu, rat

Türkiye Klinikleri J Med Sci 2004, 24:598-602

The liver is especially sensitive to carbon tetrachloride (CCl₄) commonly used as an experimental model for the liver injury. CCl₄ is one of

the most important prooxidant substance causing the hepatic cellular injury, and it is metabolized to haloalkane radicals initiated cellular damage by mechanisms of covalent binding and lipid peroxidation.¹⁻⁵ Haloalkane radicals cause the oxidative stress and damage of lipids, lipoproteins and other cellular components such as enzymes, nucleic acids and proteins.^{2,4} Antioxidant substances prevent oxidative damage caused by free radicals in cellular components.⁶⁻⁸

Geliş Tarihi/Received: 28.10.2003 Kabul Tarihi/Accepted: 16.09.2004

The abstract of this study was presented at the Turkish National Congress of Physiological Sciences.

Yazışma Adresi/Correspondence: Mustafa ZERİN, MD
Department of Physiology,
Faculty of Medicine, University of Harran, ŞANLIURFA

Copyright © 2004 by Türkiye Klinikleri

It has been reported that *Nigella Sativa* Oil (NSO) could diminish the CCl_4 -induced hepatotoxicity, the doxorubicin-induced cardiotoxicity and the harmful effects of some chemicals.⁹⁻¹⁷ Abnormal activities of some enzymes are usually indicative of the hepatic cellular injury in animals and humans.^{2,4,7,18,19} Interrelationships between protective effects of the NSO and harmful effects of CCl_4 have been investigated, and it has been reported that there is protective and antioxidative role of NSO.^{9-11,20} Therefore, the present study was designed to investigate the effects of NSO on activities of functional liver enzymes in blood plasma and on the liver injury generated by CCl_4 in rats.

Material and Methods

Animals and treatments: This study was carried out on 60 Wistar albino rats weighing 200-250 g body wt. Rats were bought from Research Center of Experimental Animal. All rats fed rodent pellets and drinking water ad-libitum. The animals were randomly divided into three equal groups containing twenty rats, housed in cages at room temperature during the study.

The first group was used as control, and only placebo (physiological saline, 0.9%) was injected intraperitoneally (IP). The second group was injected IP CCl_4 (0.15 mL/kg-body weight) dissolved in olive oil. The third group was injected IP CCl_4 0.15 mL/kg, and NSO (1 mL/kg-body weight) was received by gastric gavages. CCl_4 was diluted with olive oil (1/4, v/v). All treatments were administered three times in a week for a period of 7 weeks.

Mortality rates were among 5-20% that are similar to results of the investigation performed by using this model.³ After 24 h, last dose was administered, the blood samples were taken and the animals were sacrificed under ether anesthesia. The abdomen was opened; the liver was removed and fixed in formaldehyde (10%, v/v) for histopathological examination. Olive oil was provided from Sigma Chemical Co. (St. Louis, MO, USA). CCl_4 was purchased from Merck AG (Darmstadt, Germany).

Obtaining of plasma and enzyme analysis: The blood of all animals was taken by cardiac puncture 24 h after the last application of CCl_4 and

NSO. Whole blood samples were collected in the heparinized tubes (Beckon Dickinson Vacuntainer System, Cedex, France), subsequently centrifuged at 1500 x g, for 15 min in a Heraeus Inst, Mega Fuge 1.0, and their plasma was removed into disposable pipettes. In plasma samples, the activities of aspartate aminotransferase (AST), alanine aminotransferase (ALT), alkaline phosphatase (ALP) and gamma glutamyl transferase (GGT) were determined by an autoanalyser with commercially available kits (Hitachi[®] Autoanalyzer, New York, USA).

Histopathological examinations: The liver specimens were embedded in paraffin for histological examination and taken 4 μ serial sections. The sections were stained with hematoxylin and eosin (H&E) and Masson trichrome stain for evaluation of the fibrosis. The histological analyses were performed unawares from group separations by light microscopy. The grading of liver damage was made according to Manna et al. four severity grades: 0 (none), no fibrosis and normal liver architecture; I (mild), fatty degenerations around portal areas, fibrosis increased in portal areas and sinusoidal space and regular liver architecture; II (moderate), thin fibrous septa present connecting portal areas and pseudolobules seen in frequently; III (severe), thick fibrous septa and collagen bands accompanied by pseudolobules.²¹

Statistical analysis: Data are expressed as means \pm SD. Statistical analysis was performed with SPSS 9.0 for Windows. Kruskal Wallis and Mann Whitney U tests were used for analysis of variance (ANOVA) and post hoc test, respectively. Differences on statistical analysis of data were considered significant at $p < 0.05$.

Results

The values of AST, ALT, ALP and GGT are shown in Table 1. While the activities of AST, ALT, ALP and GGT were increased ($p < 0.01$, $p < 0.01$, $p < 0.05$ and $p < 0.05$, respectively) with the CCl_4 injection. The levels of these enzymes (except for ALP) in control group were lower ($p < 0.01$, $p < 0.05$, $p < 0.05$ and $p < 0.05$, respectively) than that of CCl_4 and CCl_4 plus NSO groups (Table 1).

Histopathological findings of the liver tissues revealed that CCl₄ induced necrotic, fibrotic and cirrhotic changes. Animals treated with NSO showed significant decreases compared with CCl₄ group (Table 2).

Analysis of the liver specimens of control animals showed no evidence histopathologically (Figure 1A). The effect of CCl₄ on the rat liver biopsies showed typical fibrotic and cirrhotic appearance (Figure 1B). The liver sections obtained from animals treated with NSO showed consistent reduction in liver damage. Collagen bands connecting central regions with portal areas and pseudolobules were not seen. These specimens showed more regular liver architecture, in which only thin fibrous bands were seen to connect portal areas (Figure 1C).

Discussion

In vivo and in vitro experiments demonstrate that the antioxidants play protective roles against free radicals.^{9,10,22,23} CCl₄ is metabolized in mixed function oxidase system utilizing the nicotinamide adenine dinucleotide phosphate (NADPH)-cytochrome P-450 electron transport chain at the level of the hepatic smooth endoplasmic reticulum and may be occur the hemolytic cleavage during formation of the haloalkane free radicals such as trichloromethyl (CCl₃) radical and trichloro-

methyleperoxy (CCl₃OO) radical.^{1,3} Moreover, the liver is an important target organ for CCl₄ and the hepatocytes may damage by haloalkane free radicals produced during biotransformation of CCl₄. Haloalkane free radicals may be bind to subcellular macromolecules and can react with free amino groups on proteins and then the macromolecules may lose their physiological functions.^{1,2,4} It has been reported that haloalkane free radicals were held to be responsible for CCl₄-hepatotoxicity and caused the oxidative damage of unsaturated lipids in some cellular components of hepatic tissues. Damage of these components may be an important factor in the ethiopathogenesis of liver diseases. Thus, the AST, ALT and ALP may be mobilized into blood plasma, and serum levels of these enzymes may increase. High levels of AST, ALT, ALP and GGT in serum are usually indicative for hepatitis in experimental animals.^{2,4,5,21}

The activities of AST and ALT were statistically increased, but ALP activity was not affected by CCl₄-injection. On the other hand, the values of the AST and ALT were statistically decreased. ALP levels were similar between control and CCl₄ treated groups (Table 1). Administration of vitamins A, C, E protects the rats from some harmful effects of CCl₄.^{3,5,20,21} Interactive relations between antioxidants and CCl₄ may change the toxicity of this hepatotoxic agent. NSO is known as an antioxidant

Table 1. The enzyme activities (U/L) in control, CCl₄ and NSO-groups.

Groups	n	AST	ALT	ALP	GGT
Control	19	115.37 ± 25.32	72.21 ± 16.67	228.95 ± 51.06	2.50 ± 0.89
CCl ₄	16	344.63 ± 63.13 ^b	122.38 ± 13.10 ^a	245.06 ± 60.80 ^a	3.14 ± 0.89 ^a
CCl ₄ + NSO	17	238.80 ± 53.86 ^{b, d}	106.20 ± 16.60 ^{a, c}	186.80 ± 35.58 ^{a, c}	3.25 ± 0.95 ^c

Statistical significant according to control group, ^ap < 0.05; ^bp < 0.01, Statistical significant according to CCl₄-group, ^cp < 0.05; ^dp < 0.01.

Table 2. Histopathological grading in the liver tissues of control, CCl₄ and NSO-groups.

Groups	n	Histopathological Grading			
		0	I	II	III
Control	19	19	0	0	0
CCl ₄	16	0	0	5	11
CCl ₄ + NSO	18	0	9	5	4

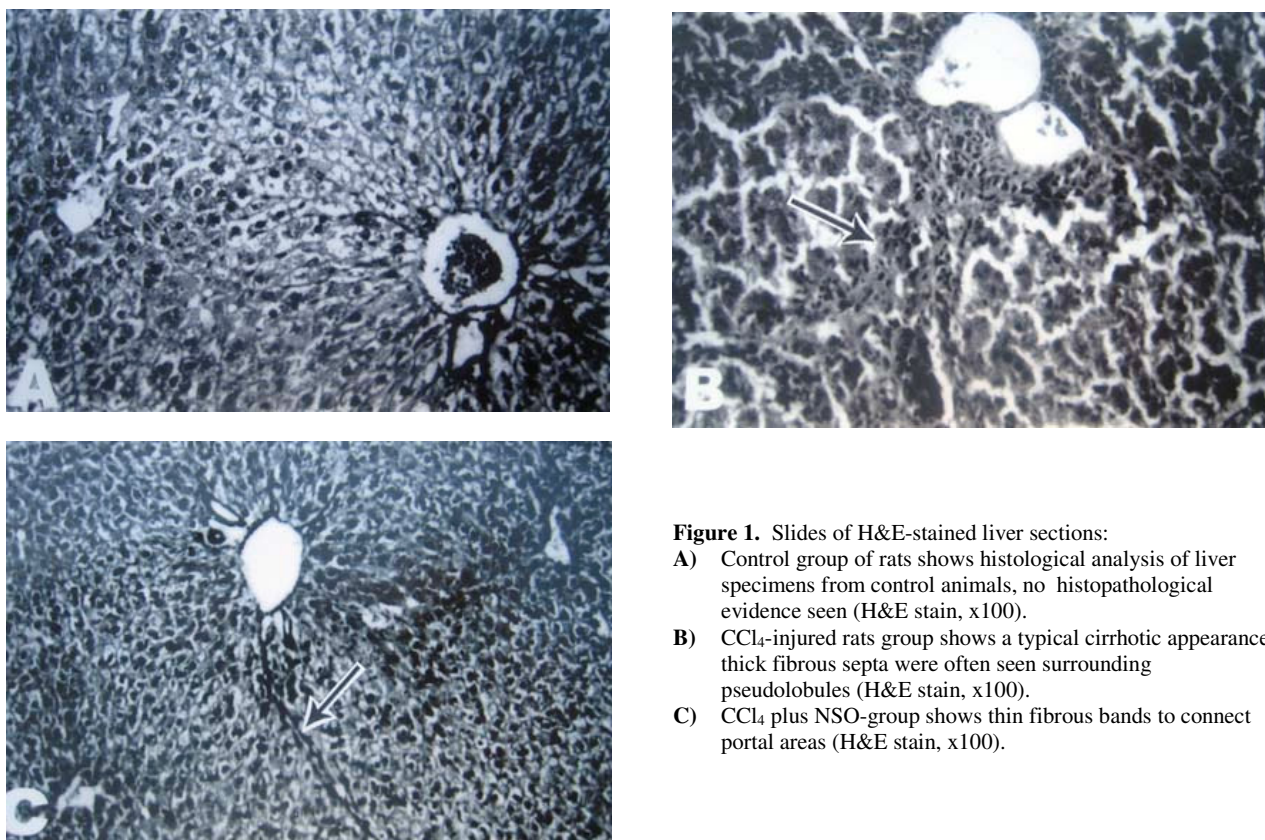


Figure 1. Slides of H&E-stained liver sections:

- A) Control group of rats shows histological analysis of liver specimens from control animals, no histopathological evidence seen (H&E stain, x100).
- B) CCl₄-injured rats group shows a typical cirrhotic appearance, thick fibrous septa were often seen surrounding pseudolobules (H&E stain, x100).
- C) CCl₄ plus NSO-group shows thin fibrous bands to connect portal areas (H&E stain, x100).

ability to inhibit oxidative processes of lipids and lipoproteins in cell membranes.² Thus, NSO may play a role in indication of hepatic cellular injury produced by CCl₄. While the activities of AST, ALT, ALP and GGT enzymes were statistically increased with injections of CCl₄; the values of these enzymes were statistically decreased with the administration of NSO. Our results are in generally agreement with results of the investigations performed using antioxidants and hepatotoxic substances.^{10,23}

Histopathological observations of liver tissues revealed that CCl₄ induced necrotic, fibrotic and cirrhotic changes. These histopathological changes were significantly decreased by NSO treatment. Histological analysis of liver specimens from control animals showed no evidence of histopathological alterations. The effect of CCl₄ on rat liver biopsies showed usually a typical fibrotic and cirrhotic appearance. Some biopsies showed varieties of degree of hepatic degenerations. The protective effects exerted by the NSO against CCl₄-induced

liver injury was confirmed by conventional histological examination.^{9,10} Liver sections obtained from animals treated with CCl₄ plus NSO showed consistent reduction of liver necrosis, fibrosis, and the cirrhotic process was clearly reduced in many treated livers. Collagen bands connecting central regions with portal areas and pseudolobules were no seen. In addition, occasionally cell injury, coagulative necrosis, inflammatory infiltration and centrilobular fatty metamorphosis were always observed. Intralobular necrosis, comprising all single cell and cell groups, including piece-meal and bridge necrosis were seen. Fatty degeneration within hepatocytes was present especially in the centrilobular zone of the liver. Periportal tract and intralobular variable numbers of inflammatory cells consisting of granulocytes, round cells were observed. Masson trichrome stain, in particular, showed more regular liver architecture, in which only thin fibrous bands were seen to connect portal areas. In conclusion, these histopathological results of the present study suggest that NSO can diminish

liver injury induced by CCl₄.

According to these results, NSO may play an important role in prevention of hepatic cellular injury produced by CCl₄. Indeed, NSO is known for their antioxidant activities in the inhibition the oxidative processes of lipids and lipoproteins in cell membranes.¹¹ These results show that NSO can partially diminish the increase in levels of the enzymes from the liver in plasma. In addition, it was showed that NSO significantly decreased the necrotic and fibrotic changes in the liver. Therefore, NSO may be administered for the purpose of preventive and corrective treatment in toxicity of CCl₄. Thus, NSO may play an important role in preventive indication of hepatic cellular injury and fibrosis produced by CCl₄. However, there is a need for more detailed studies in order to assess possible relationships between NSO and CCl₄-hepatotoxicity.

REFERENCES

1. Biasi F, Albano E, Chiarotto E, et al. In vivo and in vitro evidence concerning the role of lipid peroxidation in the mechanism of hepatocyte death due to carbon tetrachloride. *Cell Biochem Funct* 1991;9:111-8.
2. Comporti M. Biology of diseases: Lipid peroxidation and cellular damage in toxic liver injury. *Lab Invest* 1985; 53(6):599-623.
3. Knook DL, Bosma A, Seifert WF. Role of vitamin A in liver fibrosis. *J Gastroentero Hepatol* 1995;10(1):47-9.
4. Miao S, Bao-En W, Annoni G, Esposti SD, Biempica L, Zern M. Two rat models of hepatic fibrosis: A morphometric and molecular comparison. *Lab Invest* 1990; 63(4):467-75.
5. Parola M, Leonarduzzi G, Biasi F, et al. Vitamin E dietary supplementation protects against carbon tetrachloride-induced chronic liver damage and cirrhosis. *Hepatology* 1992;16(4):1014-21.
6. McPherson A. Selenium, vitamin E and biological oxidation. In: Cole DJ, Garnsworthy PJ, eds. *Recent Advances in Animal Nutrition*. Oxford: Butterworth and Heinemann's; 1994. p.3-30.
7. Murray RK, Granner DK, Mayes PA, Rodwell VW. *Harper's Biochemistry*. 22nd Norwalk: Mc Graw-Hill; 1988. p.574-6.
8. Sies, H, Stahl, W. Antioxidant functions of vitamins: Vitamin C and E, β -carotene and other carotenoids. *Ann NY Acad Sci* 1992;669:7-21.
9. Mansour MA. Protective effect of thymoquinone and desferrioxamine against hepatotoxicity of carbon tetrachloride in mice. *Life Sci* 2000;66(26):2583-91.
10. Nagi MN, Alam K, Badary OA, Al-Shabanah OA, Al-Sawaf HA, Al-Bekairi AM. Thymoquinone protects against carbon tetrachloride hepatotoxicity in mice via an antioxidant mechanism. *Biochem Mol Biol Int* 1999;47(1):153-9.
11. Burits M, Bucar F. Antioxidant activity of *Nigella sativa* essential oil. *Phytother Res* 2000;14:323-8.
12. El-Dakhkhny M, Barakat M, Abd El-Halim M, Aly SM. Effects of *Nigella Sativa* Oil on gastric secretion and ethanol-induced ulcer in rats. *J Ethnopharmacol* 2000;72:299-304.
13. Enomoto S, Asano R, Iwahori Y, et al. Hematological studies on black cumin oil from the seeds of *Nigella sativa* L. *Biol Pharm Bull* 2001;24(3):307-10.
14. Hanafy MSM, Hatem ME. Studies on the antimicrobial activity of *Nigella sativa* seed (black cumin). *J Ethnopharmacol* 1991;34(2-3):275-8.
15. Salem ML, Hossain MS. Protective effect of black seed oil from *Nigella sativa* against murine cytomegalovirus infection. *Int J Immunopharmacol* 2000; 22:729-40.
16. Swamy SM, Tan BK. Cytotoxic and immunopotentiating effects of ethanolic extract of *Nigella sativa* L. seeds. *J Ethnopharmacol* 2000;70(1):1-7.
17. Zerin M, Karakılıç Z, Arslan O, Vural H. Effects of vitamin C and E on erythrocyte osmotic fragility (EOF) and some hematological parameters in experimental aflatoxicosis of rabbits. *Turkiye Klinikleri J Med Sci* 2002;20(1):11-5.
18. Hassall E, Israel DM, Gunesakaran TM, Steward D. Halothane hepatitis in children. *J Pediatr Gastroenterol Nutr* 1990;11:553-7.
19. Ray DC, Drummond GB. Halothane hepatitis. *Br J Anaesth* 1991;67:84-99.
20. Turkdogan MK, Agaoglu Z, Yener Z, Sekeroglu R, Akkan HA, Avci ME. The role of antioxidant vitamins (C and E), selenium and *Nigella sativa* in the prevention of liver fibrosis and cirrhosis in rabbits: New hopes. *Dtsch Tierarztl Wochenschr* 2001;108(2):71-3.
21. Manna Z, Guopei S, Minuk GY. Effects of hepatic stimulator substance, herbal medicine, selenium/vitamin E, and ciprofloxacin on cirrhosis in the rat. *Gastroenterology* 1996;110:1150-5.
22. Houghton PJ, Zarka R, Heras BDL, Hoult JRS. Fixed oil of *Nigella sativa* and thymoquinone inhibit eicosanoid generation in leucocytes and membrane peroxidation. *Planta Med* 1995;61(1):33-6.
23. Nagi MN, Mansour MA. Protective effect of thymoquinone against doxorubicin-induced cardiotoxicity in rats: A possible mechanism of protection. *Pharmacol Res* 2000;41(3):281-9.