

Shaken Baby Syndrome: Case Report

Sarsılmış Bebek Sendromu

Feyza KOÇ,^a
Sadık AKŞİT,^a
Tuncer TURHAN,^b
Yusuf ERŞAHİN,^b
Arda TOMBA,^c
Oya HALICIOĞLU,^a
Aslı ASLAN,^a
Güldane KOTUROĞLU,^a
Cahide AYDIN,^d
Saniye ÇETİN,^d
Ender ŞENOL,^e
Ahmet ÇELİK,^f
Sinan KARA^g

Departments of
^aPediatrics,
^bNeurosurgery,
^cSocial Worker,
^dChild Psychiatry,
^eForensic Medicine,
^fPediatric Surgery,
^gOrthopedics,
Ege University Faculty of Medicine,
İzmir

Geliş Tarihi/Received: 06.06.2011
Kabul Tarihi/Accepted: 25.01.2012

Yazışma Adresi/Correspondence:
Feyza KOÇ
Ege University Faculty of Medicine,
Department of Pediatrics, İzmir,
TÜRKİYE/TURKEY
feyzauymaykoc@yahoo.com

doi: 10.5336/medsci.2011-25176

Copyright © 2012 by Türkiye Klinikleri

ABSTRACT Shaken baby syndrome (SBS) is a serious type of physical abuse characterized by subdural hematoma and retinal hemorrhage. This syndrome is frequently seen in children younger than 2 years of age. Most of the time it results in death or severe neurological damage. In these cases, external visible injuries are generally absent; often there no history of shaking or trauma. Clinical symptoms and findings are nonspecific. Therefore, most of the cases are missed when SBS is not considered in the differential diagnosis. In this article, we reported two SBS cases admitted to our hospital with a history of head trauma and convulsions, resulting in death in one case.

Key Words: Shaken baby syndrome; child abuse; hematoma, subdural

ÖZET Sarsılmış bebek sendromu (SBS) fiziksel istismarın subdural hematoma ve retinal kanama ile karakterize ciddi bir tipidir. Bu sendrom sıklıkla 2 yaşından küçük çocuklarda görülür. Olguların çoğu ölüm veya ciddi nörolojik hasarla sonuçlanır. Bu olgularda genellikle dışarıdan görülebilen yaralanmalar olmadığı gibi, genellikle sarsılma veya travma öyküsü de yoktur. Klinik belirti ve bulgular nonspesifiktir. Böylece ayırıcı tanıda SBS düşünülmediğinde olguların çoğu atlanır. Bu makalede hastanemize kafa travması ve konvülsiyonla başvuran, bunlardan biri ölümlü sonuçlanan, iki SBS olgusunu sunduk.

Anahtar Kelimeler: Sarsılmış bebek sendromu; çocuk istismarı; hematoma, subdural

Türkiye Klinikleri J Med Sci 2012;32(6):1781-5

Shaken baby syndrome (SBS) was first described in 1974 by a radiologist, John Caffey.¹ This syndrome is a serious type of physical abuse characterized by subdural and retinal hemorrhage. SBS is frequently seen in children younger than 2 years of age, but may be seen in children up to 5 years of age.^{2,3} Most of the time it results in death or severe neurologic sequelae.

In these cases, external visible injuries are generally absent, clinical symptoms and findings are nonspecific and not consistent with the history given by the parents.⁴ Infants with SBS are generally admitted to the emergency department with irritability, lethargy, vomiting, seizures, apnea, poor feeding and coma.^{4,5} The cases of SBS may be missed when it is not considered in the differential diagnosis.

The incidence of SBS in USA has been reported 15-26 cases 100,000 person-years and yearly 50,000 cases of SBS have been estimated.⁶⁻⁸ However, no SBS cases have been reported in the Turkish literature until 2000s. To our knowledge, a total of 9 SBS cases have been reported from Turkey in the last 10 years.⁹⁻¹¹ Under-recognition and under-reporting of these cases may be responsible for this picture. Here, we reported two SBS cases admitted to our hospital with a history of head trauma and convulsions to emphasize the need of consideration of SBS in the differential diagnosis of children with head trauma.

CASE REPORTS

CASE 1

A previously healthy 17-month-old male infant was admitted to the emergency unit due to convulsions and unconsciousness. According to the history obtained from the stepfather, the child worsened immediately after falling down from the seat about 40 cm high when playing.

On admission to the hospital, the patient had no spontaneous respiration and Glasgow Coma score was 4. On examination, there were no external visible injuries. The pupils were anisocoric. The left pupil was dilated and had no light reflex. Fundus examination revealed extensive bilateral retinal hemorrhages. Metabolic parameters including urine organic acids, serum amino acids, ammonia, lactic acids and blood gases, complete blood count with platelet counts, electrolytes, liver function tests and complete coagulation profile including prothrombin time (PT), activated partial thromboplastin time (APTT), fibrinogen level, Von Willebrand Factor were within normal limits. Skeletal survey including humeri, forearms, hands, femurs, lower legs, feet, chest, ribs, thorax (ribs, thoracic and upper lumbar-spine), pelvis, lumbosacral-cervical vertebrae and skull was negative. Cranial tomography (CT) revealed acute subdural hematoma in the left frontotemporal area with midline shift and cerebral edema (Figure 1). The patient was diagnosed as SBS on the basis of subdural hematoma and retinal hemorrhages.

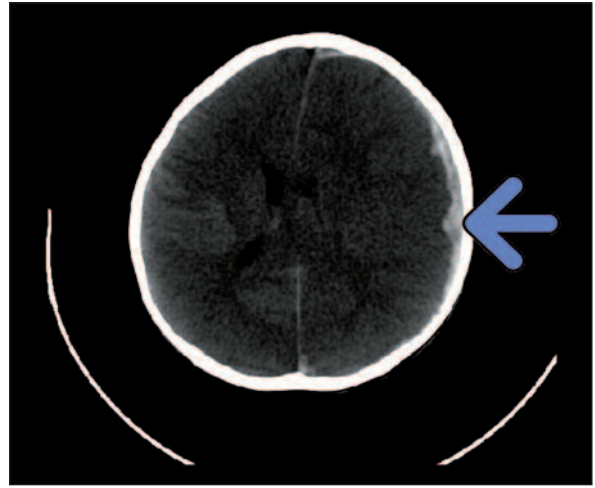


FIGURE 1: Computerized tomography revealed acute subdural hematoma in the left fronto-temporal area with midline shift and cerebral edema.

(See for colored form <http://tipbilimleri.turkiyeklinikleri.com/>)

The patient was urgently transferred to neurosurgery clinic and temporofrontal decompression craniotomy was performed. After the surgery, clinical picture did not improve and the patient died on the fifth day of the hospitalization. The case was reported to social service department.

The social history taken from the mother revealed that her family was from the low socioeconomic class and she had 7 siblings. She had married twice. Our patient was from her first marriage. She was 17 years old when the child was born. Her second marriage was not happy because of domestic violence. Her husband was alcoholic and once he hit the child when he was crying. In the interview with the stepfather, he admitted that he shook the baby before the event. The stepfather has been charged.

CASE 2

A previously healthy 4.5-month-old male infant was admitted to the emergency unit due to new-onset seizure. According to the history obtained from the mother, he bumped his head to the go-cart and he had convulsions one day after this accident. According to the history obtained from the father, he bumped his head to a toy.

During the admission to the hospital, his general condition was good and he was conscious. There were multiple ecchymosis on the right zy-

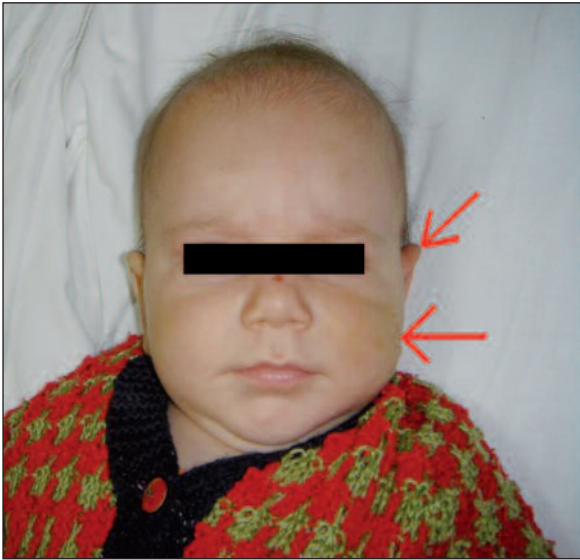

FIGURE 2: In the Case 2, there were multiple ecchymoses on the right zygomatic bone and the left ear.

(See for colored form <http://tipbilimleri.turkiyeklinikleri.com/>)

gomatic bone and the left ear (Figure 2). Neurological examination was within normal limits. Ophthalmic examination revealed bilateral retinal hemorrhages. Laboratory findings such as complete blood count with platelet counts, metabolic parameters (urine organic acids, serum amino acids, ammonia, lactic acids and blood gases), electrolytes, liver function tests and complete coagulation profile (PT, APTT, fibrinogen and Von Willebrand factor) were also within normal limits. Skeletal survey including humeri, forearms, hands, femurs, lower legs, feet, chest, ribs, thorax (ribs, thoracic and upper lumbar-spine), pelvis, lumbosacral-cervical vertebrae and skull was negative. CT revealed acute subdural hemorrhage in the right fronto-temporal area (Figure 3). The patient was diagnosed as SBS due to subdural and retinal hemorrhages. The patient had no problem in the clinic and was discharged after one week.

Social service department was informed about the case. The past social history was obtained from parents. The father was physically abused by his father during his childhood. There was domestic violence at home. In the first interview, the parents did not mention anything about shaking or other trauma. However, during the history taken from

the parents separately, the statements between parents were conflicting. In the second interview, the father admitted that he was frustrated and violently shook the baby when he cried. The baby was placed in the foster care by the social service. Legal process is continuing on this case. He still does not have any neurologic sequelae one year after the discharge.

DISCUSSION

SBS is a severe form of child abuse mostly seen in children less than 2 years of age and occurs due to shaking the children vigorously. External evidence of SBS is minimal or absent. On the physical examination of the first case, we could not find any evidence of physical trauma. In the second case, we detected ecchymosis on his cheek. In a Turkish study published by Yağmur et al. reported four SBS cases and only one of them had external clinical evidence.⁹ In another study by Becker et al., no external physical findings were detected in 3 of the 5 children with SBS.¹²

There are generally nonspecific clinical findings in SBS cases. Infants with SBS present with irritability, lethargy, vomiting, seizures, bulging fontanel, increased head size and coma. Chronic form of SBS has also been described where infants may also have failure to thrive, altered eating and

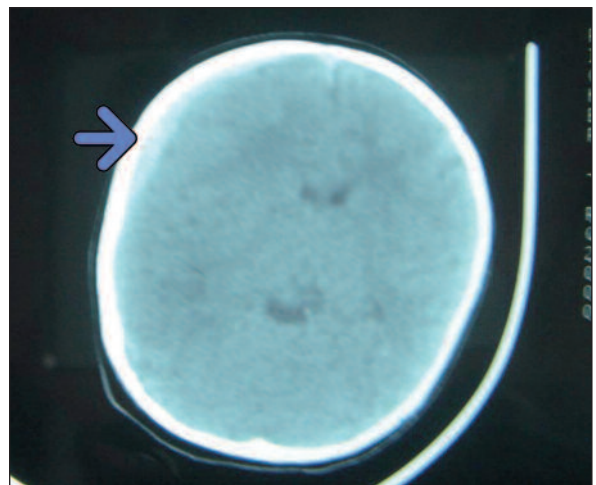


FIGURE 3: Computerized tomography revealed acute subdural hemorrhage in the right fronto-temporal area.

(See for colored form <http://tipbilimleri.turkiyeklinikleri.com/>)

sleeping patterns and chronic neurological symptoms.^{4,5} The first case was admitted to hospital because of new-onset seizures and coma. The second case also presented with seizures. In the literature, there are a number of SBS cases presented with new-onset seizures.^{10,11,13} However, several studies reported that many cases were admitted to hospital in coma.^{12,14,15}

There are numerous family risk factors in child abuse such as poor family, young mother, stepfather/mother, domestic violence, unemployment, drug-alcohol addiction and family disruption.¹⁶ Moreover, implausible, changing, inconsistent histories are strong indicators for child abuse.¹⁷ This is why a detailed family interview is definitely required in order to diagnose child abuse. There were also several social risk factors for child abuse in our cases.

In our second case, the parents have fabricated different trauma stories. Through detailed family interviews, we revealed that both of the babies were shaken. In a study conducted on 52 patients, it was reported that parents of 5 SBS cases confessed that they had shaken their babies at the beginning.¹⁸ In another study, parents of 5 cases admitted that they had shaken their babies on the later interviews.¹²

It was reported that 65% of the children under one year of age who were admitted to hospital due to cranial trauma were victims of child abuse.¹⁹ Therefore, detailed history of trauma should be taken from the family and the eye-witnesses. Families often describe a minor trauma, or even do not mention about it. Our first case was in coma at the admission and the stepfather reported that patient fell down from 40 cm height. Our second case had convulsions following a minor trauma story. However, in our cases, the history of trauma told by the parents was not enough to explain the severity of clinical findings. In this respect, it was in favor of SBS. Serious injuries such as skull fracture, cerebral edema, intraocular hemorrhage, subdural hemorrhage and serious clinical manifestations are not compatible with short-range height falls. In most studies, it has been noted that severe head injury is only seen when the child falls more than 150

cm height.²⁰⁻²² In a study, Johnson et al. investigated 72 children admitted to hospital with accidental falls from heights of 50 cm to 3 m.²³ They pointed out that serious head trauma may occur when the child falls down from the height of 150 cm or more; otherwise, serious injuries are unlikely.

In both of our cases, we detected subdural hemorrhage on CT and retinal hemorrhage on fundus examination. The presence of both subdural and retinal hemorrhages is pathognomonic for the diagnosis of SBS.^{24,25} Subdural hemorrhage is the most frequently seen intracranial hemorrhage in SBS. In some cases, subarachnoid hemorrhage may be seen alone or together with subdural hemorrhage.^{12,14} Retinal hemorrhage is found in 75-90% of the SBS cases.^{26,27} In SBS cases, most of the time retinal hemorrhages are numerous, multilayer and bilateral.²⁵ In a study, presenting 4 SBS case reports, both subdural and retinal hemorrhages were observed in 2 children, while only subdural hemorrhage was seen in a child.⁹ In another study, all of five children who had retinal hemorrhages were diagnosed with SBS.¹² However, one of these five children had subdural hemorrhage and four of them had subarachnoid and diffuse intraparenchymal hemorrhages. SBS cases with only retinal hemorrhages have also been reported.^{12,28} However, some diseases such as accidental trauma, birth trauma, coagulation disorders, infections (encephalitis, meningitis), metabolic/genetic disorders (Glutaric aciduria Type I, Ehlers Danlos syndrome) should be considered in the differential diagnosis.

One third of the SBS cases die while one third may recover with major sequelae.^{4,5} Our first case has been admitted with severe clinical findings and died. Fortunately, our second case recovered without sequelae and is being followed-up. In a study conducted on 52 children with SBS, it has been reported that 20 of the children died. However, there was no information about the long term follow-up of the other cases.¹⁸ In another study, 60% of the children with SBS admitted to hospital in coma either lost their lives or developed mental retardation, quadriplegia or severe motor retardation. In the same study, it has been also reported that SBS

cases admitted to hospital with mild symptoms and without severe cerebral damage displayed mild neurological symptoms and epilepsy in the follow-up period.²⁹

In conclusion, in the literature, a few SBS cases have been reported from Turkey as compared to many developed countries in the world. Although true incidence of SBS is not known yet, most of the cases admitted to the emergency departments with head trauma seem to be overlooked in our country. Therefore, education of the health profession-

als is utmost important for the diagnosis of these cases, as well as the education and support of the families from low socioeconomic groups to prevent child abuse. In addition, when the clinical picture does not support an accident in children presenting with intracranial hemorrhage, an extensive investigation including social assessment, ophthalmoscopic evaluation by an experienced specialist, skeletal survey, complete coagulation profile for bleeding disorders and screening for glutaric aciduria is needed for the differential diagnosis of SBS.

REFERENCES

- Caffey J. The whiplash shaken infant syndrome. *Pediatrics* 1974;54(4):396-403.
- Ludwig S, Warman M. Shaken baby syndrome: a review of 20 cases. *Ann Emerg Med* 1984;13(2):104-7.
- Bruce DA, Zimmerman RA. Shaken impact syndrome. *Pediatr Ann* 1989;18(8):482-4, 486-9, 492-4.
- Committee on Child Abuse and Neglect, American Academy of Pediatrics. Shaken baby syndrome: rotational cranial injuries-technical report. *Pediatrics* 2001;108(1):206-10.
- Matschke J, Voss J, Obi N, Görndt J, Sperhake JP, Püschel K, et al. Nonaccidental head injury is the most common cause of subdural bleeding in infants <1 year age. *Pediatrics* 2009;124(6):1587-94.
- Newton AW, Vandeven AM. Unexplained infant and child death: a review of sudden infant death syndrome, sudden unexplained infant death, and child maltreatment fatalities including shaken baby syndrome. *Curr Opin Pediatr* 2006;18(2):196-200.
- Dias MS, Smith K, DeGuehery K, Mazur P, Li V, Shaffer ML. Preventing abusive head trauma among infants and young children: a hospital-based, parent education program. *Pediatrics* 2005;115(4):e470-7.
- Barlow KM, Thomson E, Johnson D, Minns RA. Late neurologic and cognitive sequelae of inflicted traumatic brain injury in infancy. *Pediatrics* 2005;116(2):e174-85.
- Yagmur F, Asil H, Canpolat M, Per H, Coskun A. [Short distance falls and shaken baby syndrome: case report]. *Turkiye Klinikleri J Med Sci* 2010;30(2):766-71.
- Yagmur F, Asil H, Per H, Aslan D, Coskun A. [Shaken baby syndrome & 3 cases]. *Adli Tıp Dergisi* 2010;24(1):42-9.
- Tüzün B, Üçsel R, Alkan N, Çıtak A, Fincancı RS. [Shaken baby syndrome: relationship between child abuse and convulsions in infancy]. *Adli Tıp Bülteni* 2000;5(3):168-72.
- Becker JC, Liersch R, Tautz C, Schlueter B, Andler W. Shaken baby syndrome: report on four pairs of twins. *Child Abuse Negl* 1998; 22(9):931-7.
- Altınok D, Saleem S, Zhang Z, Markman L, Smith W. MR imaging findings of retinal hemorrhage in a case of nonaccidental trauma. *Pediatr Radiol* 2009;39(3):290-2.
- Arun Babu T, Venkatesh C, Mahadevan S. Shaken baby syndrome. *Indian J Pediatr* 2009;76(9):954-5.
- Gruber TJ, Rozzelle CJ. Thoracolumbar spine subdural hematoma as a result of nonaccidental trauma in a 4-month-old infant. *J Neurosurg Pediatr* 2008;2(2):139-42.
- Brown J, Cohen P, Johnson JG, Salzinger S. A longitudinal analysis of risk factors for child maltreatment: findings of a 17 year prospective study of officially recorded and self-reported child abuse and neglect. *Child Abuse Negl* 1998;22(11):1065-78.
- Aksit S, Koc F. [Child abuse and neglect]. *Ege Pediatr Bülteni* 2008;15(2):123-33.
- Brion D, Shelton D. Perparator accounts in infant abusive head trauma brought about by a shaking event. *Child Abuse Negl* 2009; 29(12):1347-58.
- Billmire ME, Myers PA. Serious head injury in infants: accident or abuse? *Pediatrics* 1985; 75(2):340-2.
- Williams RA. Injuries in infants and small children resulting from witnessed and corroborated free falls. *J Trauma* 1991;31(10): 1350-2.
- Helfer RE, Slovis TL, Black M. Injuries resulting when small children fall out of bed. *Pediatrics* 1977;60(4):533-5.
- Lyons TJ, Oates RK. Falling out of bed: a relatively benign occurrence. *Pediatrics* 1993; 92(1):125-7.
- Johnson K, Fischer T, Chapman S, Wilson B. Accidental head injuries in children under 5 years of age. *Clin Radiol* 2005;60(4): 464-8.
- Caffey J. On the theory and practice of shaking infants. Its potential residual effects of permanent brain damage and mental retardation. *Am J Dis Child* 1972;124(2):161-9.
- Levin VA. Retinal hemorrhage in abusive head trauma. *Pediatrics* 2010;126(5):961-70.
- Kivlin JD, Simons KB, Lazoritz S, Ruttum MS. Shaken baby syndrome. *Ophthalmology* 2000;107(7):1246-54.
- Morad Y, Kim YM, Armstrong DC, Huyer D, Mian M, Levin AV. Correlation between retinal abnormalities and intracranial abnormalities in the shaken baby syndrome. *Am J Ophthalmol* 2002;134(3):354-9.
- Healey K, Schrading W. A case of shaken baby syndrome with unilateral retinal hemorrhage with no associated intracranial hemorrhage. *Am J Emerg Med* 2006; 24(5):616-7.
- Sinal SH, Ball MR. Head trauma due to child abuse: serial computerized tomography in diagnosis and management. *South Med J* 1987;80(12):1505-12.