






Cartilaginous Metaplasia in Uterine Leiomyoma

 Burak KARADAĞ^a,
 Gül ALKAN BÜLBÜL^a,
 Betül ÇELİK^b,
 Tangül BULUT^b,
 Barış MÜLAYİM^a

Clinics of

^aObstetrics and Gynecology,

^bPathology,

Antalya Training and Research Hospital,
Antalya, TURKEY

Received: 09 Nov 2018

Received in revised form: 21 Feb 2019

Accepted: 23 Feb 2019

Available online: 05 Mar 2019

Correspondence:

Burak KARADAĞ

Antalya Training and Research Hospital,
Clinic of Obstetrics and Gynecology,

Antalya, TURKEY

drburakkaradag@gmail.com

ABSTRACT Metaplasia is the reversible replacement of a single adult mesenchymal or epithelial cell by another type of adult cell. Metaplasia in adipose tissue is the most commonly reported type of metaplasia, while metaplasia in a leiomyoma is rarely reported. Cartilaginous metaplasia is also rarely seen. Although metaplasia in cartilaginous areas is rare, it may appear in a uterine leiomyoma. The present study reports a case of cartilaginous metaplasia in a uterine leiomyoma.

Keywords: Cartilaginous metaplasia; leiomyoma; metaplasia

Metaplasia is a term used to define the reversible replacement of one adult cell type (mesenchymal or epithelial) by a different adult cell type. Metaplasia may be an adaptive process in which cell types that are better able to resist the adverse environment replace cell types that are sensitive to stress. Metaplasia does not emanate from a change in the phenotype of a differentiated cell type. It is the process of reprogramming stem cells that exist in normal tissues or undifferentiated mesenchymal cells that are present in connective tissues. These precursor cells differentiate through a new pathway, resulting in a metaplastic change.¹

Leiomyoma is the most prevalent benign tumor of the female reproductive system. These tumors are classified as monoclonal and arise from myometrium.² Genetic and growth factors play a pivotal role in the etiology of leiomyoma.³ Since metaplasia in leiomyoma is not as frequent, its incidence and prevalence cannot clearly be estimated. However, the presence of adipose metaplasia in leiomyoma is rather well documented.⁴ In addition, cartilaginous and osseous metaplasia cases are extremely rare.⁵⁻⁷ This case report presents a leiomyoma in which the relevant histopathological examinations showed a cartilaginous metaplasia.

CASE REPORT

A 39-year-old woman with an obstetric score of gravida 1, parite 1, live birth 1, and abortion 0 presented with a 5-year history of secondary infertility. No significant issues were found in her clinical history other than a caesarean section. Her menstrual history was also normal. Neither the hor-

monal assessment of the couple nor the semen analysis of the woman's partner elicited a reason for the couple's infertility. In addition, no remarkable findings were detected during the pelvic examination, and no abnormalities were found in the routine hematological and biochemical assays. The ultrasound examination revealed a mixed echogenic lesion distorting the uterine cavity that measured 3x3 cm and 3x4 cm in the left ovarian anechoic cyst (Figure 1). An operation was planned due to her infertility history during the previous five-year period and the lack of any possible reason for her infertility other than a uterine leiomyoma. Informed consent was obtained before surgery. The patient underwent a successful laparoscopic myomectomy and left ovarian cystectomy. The patient was observed on two subsequent follow-up visits and discharge on the second postoperative day due to the lack of any morbidity.

PATHOLOGICAL FINDINGS

Specimen submitted for pathology laboratory consisted of left ovarian cystectomy which revealed follicle cyst and gray white nodular tumor which was 3.5x2x2 cm in diameter. The cut surface, which had a whorled, firm appearance without any necrosis or hemorrhage, was randomly sectioned. A benign leiomyoma with multiple small islands of mature cartilage circumvented by smooth muscle bundles was uncovered during microscopic examination (Figure 2). The maximum size of the cartilage islands was 1 mm, and the overall size of the focus was 8 mm (Figure 3). No other cartilaginous or mesenchymal foci were found throughout the leiomyoma.

DISCUSSION

Metaplasia is the reversible replacement of a mature post-mitotic cell type with another cell type. Metaplasia may be encountered in tissues that have been exposed to chronic trauma, infection, or abnormal hormonal stimulation. Different parts of the body develop in the embryonic stage due to specific genes in which encoding transcription factors are activated. The process is built up through a

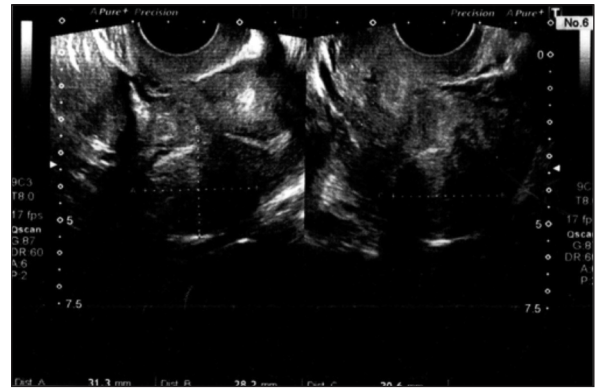


FIGURE 1: Ultrasound picture shows mixed echogenic lesion measuring 3x3 cm in uterine corpus.

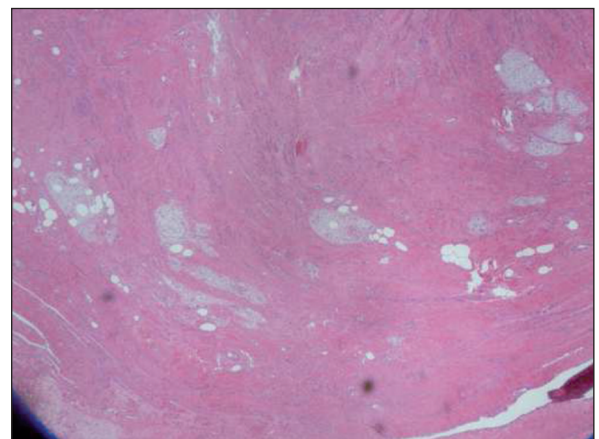


FIGURE 2: Tissue section (H&E x100): Benign leiomyoma with multiple small islands of mature cartilage surrounded by smooth muscle bundles.

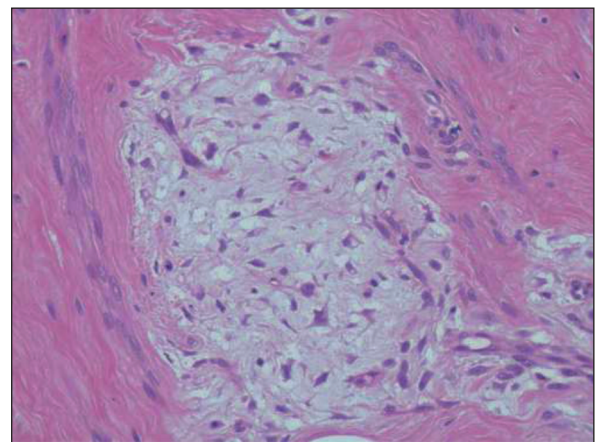


FIGURE 3: Tissue section (H&E x200).

hierarchy of developmental changes based on the response of the cells to the substances excreted by the adjacent cells, inducing the activation of the relevant genes. Many parts of the body are closely

associated with specific tissue types. Wherever a tissue is retained by cell turnover, stem or progenitor cells may insist on adult life. These cells maintain the same codes within the embryonic primordia. If the code is changed in response to a mutation or epigenetic or environmental factors, the type of tissue produced by the stem/progenitor cells will also change. The first change only occurs in one or a few cells; however, if the new tissue type has a growth advantage over the old, it can expand and become a macroscopic focus of metaplasia.⁸

Leiomyoma is seen in the uterus, small intestine, and esophagus by and large. Within the uterus, it is overwhelmingly seen during the body's active reproductive life. Endocrine, genetics, and growth factors are believed to be responsible for the etiology of leiomyoma. Moreover, fibroids are monoclonal, and approximately 40% have chromosomal abnormalities, including translocation between chromosomes 12 and 14, deletions of chromosome 7, and the trisomy of chromosome 12. Endocrine factors, such as estrogen and progesterone, appear to promote the development of fibroids. Aromatase activity is increased and progesterone receptors are unregulated in leiomyomas. Furthermore, growth factors, including transforming growth factor- β (TGF- β) and epidermal growth factor (EGF), are locally released from smooth muscle cells and fibroblasts and seem to expand the leiomyomas by stimulating the production of an extracellular matrix.³ Secondary endocrine or hydrophobic changes also occur, but metaplasia in leiomyoma is seldomly observed.⁹

Yamadori et al. reported a uterine leiomyoma with a focus of fatty and cartilaginous differentiation in a 58-year-old female. The researchers indicated that the leiomyoma was located in the posterior uterine wall and had a maximum diameter of approximately 15 cm.⁵ Kotru et al. reported a pure cartilaginous metaplasia in a uterine leiomyoma after a 25-year-old female patient underwent laparoscopic tubal ligation during medical termination. Tumor size was 2 cm and mature hyaline cartilage occupying more than 90% of leiomyoma. However, Kotru could not identify any other meta-

plastic elements.⁶ Our patient has been the second case that is reported in the current literature with pure cartilaginous metaplasia observed in uterine leiomyoma. The incidence cannot be estimated due to the fewer number of cases in the literature. The possible reasons for the limited number of cases might not only be that mesenchymal metaplasias are rarely observed, but also the inadequate amount of collected leiomyoma specimens for pathological analysis of metaplasia.

Chander previously reported an osteoid metaplasia within leiomyoma in a 49 year-old premenopausal woman suffering with abnormal bleeding and abdominal pain, who underwent hysterectomy with a pre-diagnosis of degenerated submucosal leiomyoma. This report is considered as the first case in the literature with osteoid metaplasia that is observed in uterine leiomyoma. Densely calcified mixed exogenous lesions with dimensions of 27x18 mm were observed in patient's preoperative ultrasonographic examination.⁷ In this regard, in addition to calcified focal areas in the tumor, osteoid metaplasia should be taken into consideration for differential diagnosis. In contrary, in our patient's preoperative ultrasonographic examination, we did not observe such signs pointing a cartilaginous metaplasia. Thus, it is believed that ultrasonographic monitoring is not sufficient for diagnosis of cartilaginous metaplasia uterine leiomyoma.

Cartilaginous metaplasia was also reported in leiomyoma of the soft tissues, but there is a few studies reporting cartilaginous metaplasia in endometrium.¹⁰ According to Sethi et al. the multipotent cells present in normal endometrial stroma can show metaplastic transformation into various elements, including the cartilage.¹¹ Chronic endometritis can also lead to the proliferation of mesenchymal cells that have the inherent feature of metaplasia and can differentiate into chondroblasts or osteoblasts.¹² Similar hypothesis might be raised due to the mesenchymal metaplasia observed in uterine leiomyoma. In largest number of cases with lipomatous differentiation of uterine leiomyomas, it was proposed that uterine lipomatous neo-metaplasia may be originated from peri-capillary

pluripotential mesenchymal cells.⁴ It seems to be reasonable that these pluripotent cells can also differentiate into other mesenchymal tissue such as cartilage or bone. Although the mechanism of metaplasia in uterine leiomyoma is not fully understood, it is quite possible that increased estrogen, progesterone and local growth factors may stimulate the pluripotent mesenchymal stem cells to transform into adipose and chondrotic cells. Another hypothesis for chondrotic metaplasia seen in the endometrial stroma is “housing of the fetal remnants”.¹³ In fact, this hypothesis is mainly applied to the endometrial stroma. However, is not reliable to explain the chondrotic metaplasia using the theory of the housing of uterine remnants since it does not seem to be possible that these remnants can be implanted into leiomyoma without rupturing the myometrium.

Overall, although the cartilaginous areas are rarely seen, it may appear in uterine leiomyoma. The purpose of the present case report was to highlight and document a scarce histopathological

property in uterine leiomyoma. There is need of more controlled studies to elucidate the pathophysiological mechanisms of mesenchymal metaplasia and clinical it clinical significance.

Source of Finance

During this study, no financial or spiritual support was received neither from any pharmaceutical company that has a direct connection with the research subject, nor from a company that provides or produces medical instruments and materials which may negatively affect the evaluation process of this study.

Conflict of Interest

No conflicts of interest between the authors and / or family members of the scientific and medical committee members or members of the potential conflicts of interest, counseling, expertise, working conditions, share holding and similar situations in any firm.

Authorship Contributions

Literature Review: Burak Karadağ.; **Data Collection and/or Processing:** Betül Çelik, Tangül Bulut; **Writing the Article:** Gül Alkan Bülbül; **Critical Review:** Barış Mülayim.

REFERENCES

- Slack JM. Metaplasia and transdifferentiation: from pure biology to the clinic. *Nat Rev Mol Cell Biol.* 2007;8(5):369-78. [[Crossref](#)] [[PubMed](#)]
- Rackow BW, Taylor HS. Submucosal uterine leiomyomas have a global effect on molecular determinants of endometrial receptivity. *Fertil Steril.* 2010;93(6):2027-34. [[Crossref](#)] [[PubMed](#)] [[PMC](#)]
- Berek JS. Uterine fibroids. In: William H. Parker, ed. *Berek & Novak's Gynecology.* 15th ed. Philadelphia: Lippincott Williams & Wilkins; 2012. p.438-69.
- Sieński W. Lipomatous neometaplasia of the uterus. Report of 11 cases with discussion of histogenesis and pathogenesis. *Int J Gynecol Pathol.* 1989;8(4):357-63. [[Crossref](#)] [[PubMed](#)]
- Yamadori I, Kobayashi S, Ogino T, Ohmori M, Tanaka H, Jimbo T. Uterine leiomyoma with a focus of fatty and cartilaginous differentiation. *Acta Obstet Gynecol Scand.* 1993;72(4):307-9. [[Crossref](#)] [[PubMed](#)]
- Kotru M, Gupta R, Aggarwal S, Sharma S, Bhatia A. Cartilaginous metaplasia in uterine leiomyoma. *Arch Gynecol Obstet.* 2009; 280(4):671-3. [[Crossref](#)] [[PubMed](#)]
- Chander B, Shekhar S. Osseous metaplasia in leiomyoma: a first in a uterine leiomyoma. *J Cancer Res Ther.* 2015;11(3):661. [[Crossref](#)] [[PubMed](#)]
- Slack JM. Metaplasia and somatic cell reprogramming. *J Pathol.* 2009;217(2):161-8. [[Crossref](#)] [[PubMed](#)]
- Tavassoli F, Devilee P. Mesenchymal tumours and related lesions. In: Hendrickson MR, Tavassoli FA, Kempson RL, McCluggage WG, Haller U, Kubik-Huch RA, eds. *World Health Organization Classification of Tumours.* Pathology and Genetics of Tumours of the Breast and Female Genital Organs. 1st ed. Lyon: IARC Press; 2003. p.233-44.
- Khalluf E, DeYoung BR, Swanson PE. Soft tissue leiomyoma with cartilaginous metaplasia: report of an unusual phenomenon. *Int J Surg Pathol.* 1994;1(4):235-8. [[Crossref](#)]
- Sethi S, Bhatnagar S, Sethi S. Heterotopic chondroid tissue in the uterus. *Indian J Pathol Microbiol.* 2008;51(4):568-9. [[Crossref](#)] [[PubMed](#)]
- Cayuela E, Perez-Medina T, Vilanova J, Alejo M, Cañadas P. True osseous metaplasia of the endometrium: the bone is not from a fetus. *Fertil Steril.* 2009;91(4):1293.e1-4. [[Crossref](#)] [[PubMed](#)]
- Tyagi SP, Saxena K, Rizvi R, Langley FA. Fetal remnants in the uterus and their relation to other uterine heterotopia. *Histopathology.* 1979;3(4):339-45. [[Crossref](#)] [[PubMed](#)]