

An Oropharyngeal Non-Hodgkin Lymphoma Case Misdiagnosed and Mistreated on Infection¹

HATALI TANI KONAN VE ENFEKSİYON NEDENİYLE YANLIŞ TEDAVİ EDİLEN OROFARİNGEAL NON-HODGKİN LENFOMA VAKASI

Özlem ÜÇOK*, Kaan OYSUL**, Tuncer ÖZEN***, Cahit ÜÇOK****, Kemal KARAKURUMER*****, Ömer GÜNHAN*****

- * Yrd.Doç.Dr., GATA Oral Diagnoz ve Radyoloji AD,
 ** Yrd.Doç.Dr., GATA Radyasyon Onkolojisi AD,
 *** Doç.Dr., GATA Oral Diagnoz ve Radyoloji AD,
 **** Doç.Dr., Ankara Üniversitesi Dişhekimliği Fakültesi Ağız, Diş, Çene Hastalıkları ve Cerrahisi AD,
 ***** Prof.Dr., GATA Oral Diagnoz ve Radyoloji AD,
 ***** Prof.Dr., GATA Patoloji AD, ANKARA

Summary

Purpose: A case of an oral non-Hodgkin's lymphoma presenting an extraction socket which fails to heal and does not respond to conventional treatment is reported.

Case Report: A thirty-four-year old Caucasian man had tooth extraction with toothache and headache complaints. Three months after extraction an ulceration on the hard palate developed and the mass on the palate progressed superiorly to the nasal cavity despite medical therapies and led to protrusion in the left eye. As visual impairment started he was referred to Gülhane Military Medical Academy. The transnasal biopsy of the mass revealed extranodal NK/T cell non-Hodgkin Lymphoma. He underwent chemotherapy and radiotherapy.

Conclusion: In this rare oropharyngeal case, emphasis goes to the prime importance of starting advanced diagnostic modalities to avoid therapeutic delays.

Key Words: Non-Hodgkin lymphoma, oropharyngeal lesion, head and neck, radiotherapy-chemotherapy

Türkiye Klinikleri J

Hodgkin's Disease (HD) is a malignancy of the haematopoietic system that predominantly affects old descends and young adults with males being affected more frequently than females. The commonly affected origins include liver, spleen, lungs, bone and bone marrow. Although extranodal primary sites are unusual, systemic involvement may result from disease progression. The most common extranodal site is the spleen and hepatic involvement. The region of Waldeyer's ring is often uninvolved in patients with HD (1).

Özet

Amaç: Diş çekimini takiben, konvansiyonel tedaviye cevap vermeyen, klinik görünümü; iyileşmeyen çekim boşluğu ve periodontal lezyon ile karakterize olan bir non-Hodgkin lenfoma olgusu rapor edilmiştir.

Olgu Sunumu: Baş ve diş ağrısı şikayetleri ile diş çekimi yaptırmış olan 34 yaşındaki erkek hastada, çekimden üç ay sonra sert damakta bir kitle oluşmuştur. Bu kitle uygulanan medikal tedaviye rağmen nasal kaviteye doğru gelişerek sol gözde protrüzyona neden olmuştur. Hasta bu durum sonucunda oluşan görme şikayetleri nedeniyle Gülhane Askeri Tıp Akademisi'ne sevk edilmiştir. Kitleye uygulanan transnasal biyopsi neticesinde ekstranodal NK/T non-Hodgkin Lenfoma tanısı konulmuştur. Hastanın kemoterapi ve radyoterapisi devam etmektedir.

Sonuç: Ender görülen bu orofaringeal vaka, tedavideki gecikmeyle birlikte gelişmiş diagnostik seçeneklerin önemini vurgulamaktadır.

Anahtar Kelimeler: Non-Hodgkin lenfoma, orofarengal lezyon, baş ve boyun, radyoterapi-kemoterapi

Hodgkin's Disease (HD) and non-Hodgkin's lymphoma (NHL) often involve the head and neck region. Non-Hodgkin's lymphomas (NHL) arising in extranodal sites often have a natural history which differs from primary nodal disease. Several series of patients with lymphomas involving Waldeyer's ring (nasopharynx, base of tongue, tonsil, oropharyngeal wall) and/or other extranodal head and neck sites have been reported (2, 3). Lymphoma arising within the oral cavity accounts for less than 5% of all oral malignancies, and

approximately 85% of the lesions involve the tonsils and the palate (4). NHL is most commonly seen in an older age group than in patients with HD, oral males are commonly affected than females. Predisposing conditions include various congenital and acquired immunodeficiency states. The majority of patients with NHL have advanced disease at the time of the presentation. Whereas 98% of HD presents as nodal disease, 60% of all extranodal presenters occur in the head and neck. Extranodal areas predisposed for developing lymphoma are those areas normally rich in lymphoid tissue such as Waldeyer's ring (5). Other primary sites in the extra cranial head and neck include the parotid gland, palate, gingival, lachrymal gland, eyelid, conjunctiva and paranasal sinuses (6).

Recognition of the typical patterns and appearances of these diseases is important to the practicing radiologist who interprets images of this regions because lymphoma is the second most common neoplasm in the head and neck and is the most common etiology for a unilateral neck mass in patients between 21 and 40 years of age. Diagnostic imaging plays an important role in suggesting the diagnosis, treatment planning, and evaluation for recurrence following treatment (3).

The imaging findings of extranodal head and neck lymphomas are essentially in distinguishable from those of the more common squamous cell carcinoma. The diagnosis may be suggested if the pharyngeal lesion is associated with large, homogeneously enhancing lymph nodes that don't have central necrosis. The high concentration of lymph nodes in the tongue base and palatine tonsil make the areas liked sites for developing lymphoma (1).

Localized NHL's of the head and neck are generally treated with radiotherapy with or without chemotherapy, although the results of treatment of localized NHL's with chemotherapy alone appear to be favourable. It is unclear if and when combined modality therapy should be used (7).

Case Report

A thirty-four-year old Caucasian man referred to a clinic for evaluation of his condition because

of toothache and headache complaints. Three months after extraction a wound on the hard palate developed and the mass on the palate progressed superiorly to the nasal cavity despite medical therapies and led to protrusion in the left eye. As visual impairment started he was referred to the Gülhane Military Medical Academy. The transnasal biopsy of the mass revealed extranodal NK/T cell NHL (Figure 1). In this presentation, a patient was presented who transferred to Oral Diagnosis and Radiology Department of Gülhane Military Medical Academy due to the dental consultation (Figure 2-4). T₁W MRI sequence following gadolinium DTPA showed peripheral enhancement with mass. There is homogenous appearance to mass with evidence of necrosis. T₂W MRI sequence following gadolinium DTPA showed increased signal intensity which is filling nasopharyngeal lumen, sinuses, palate and orbita.

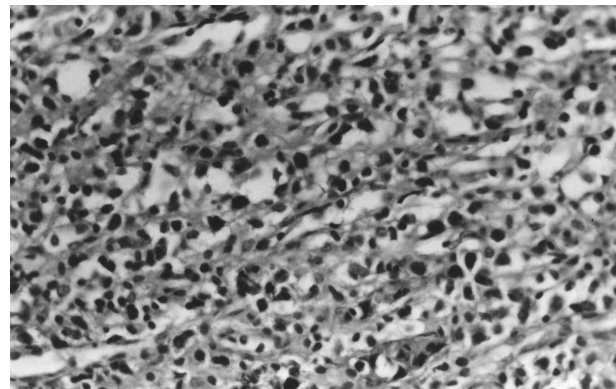


Figure 1. Diffuse atypical large lymphoid cells infiltration (Hex400).

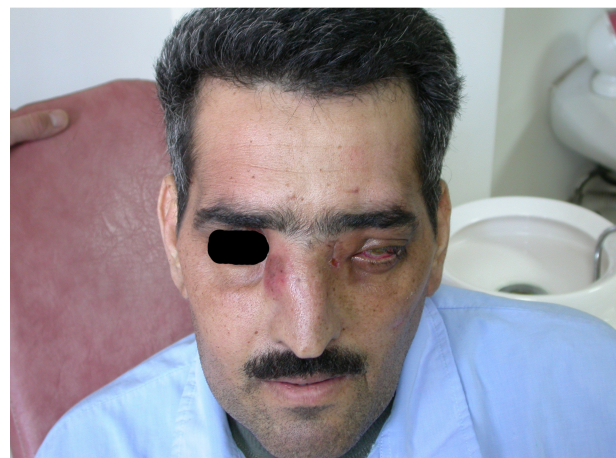

Figure 2. Clinical photograph shows protrusion in the left eye.

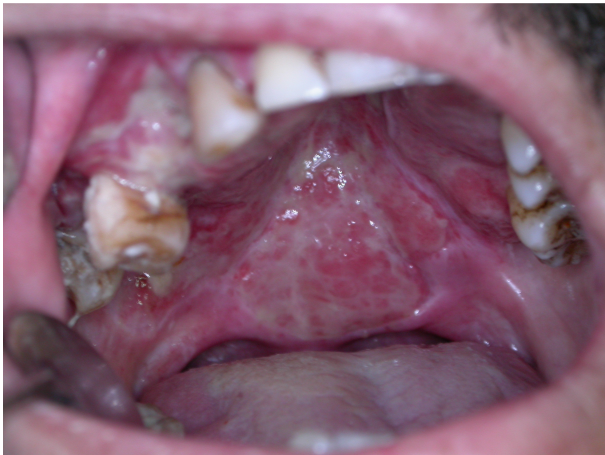

Figure 3. Clinical photograph shows exophytic NHL lesions arising from maxillary sixth molar extraction sites and hard palate.

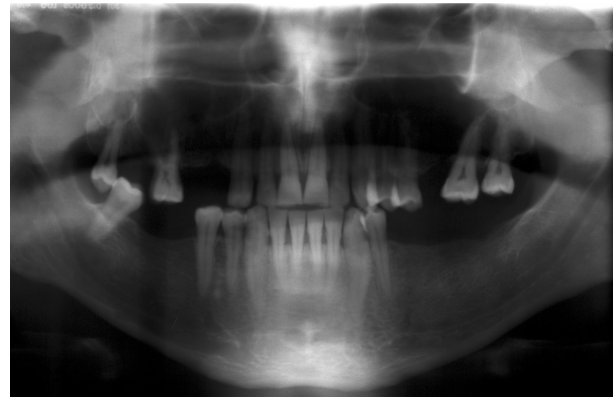

Figure 4. Panoramic radiograph shows NHL lesions arising from maxillary sixth molar extraction sites.

There is deep invasion of soft tissue structures. Axial post-contrast MRI showed an enlarged homogeneously enhancing lymph node, which is typical of a lymphomatous lymph node (Figure 5-8). The patient underwent chemotherapy and radiotherapy. The treatment and the follow up process with multiple departments are continuing.

Discussion

In most countries between 25 and 35% of NHL cases occur extra-nodally and in 3% of these

cases the initial presentation may be in the oral cavity. Around 100 cases of mandibular NHL have been described in the literature (8). Although oral lesions of NHL are often a component of more widely disseminated disease, at times, as in this case, the lymphoma presents in the oral cavity as the first identifiable evidence of the disease also reported like Parrington and Punnia-Moorthy (9).

Oral lesions appear as nontender swellings commonly affecting the vestibule, gingiva or posterior hard palate and develop slowly,

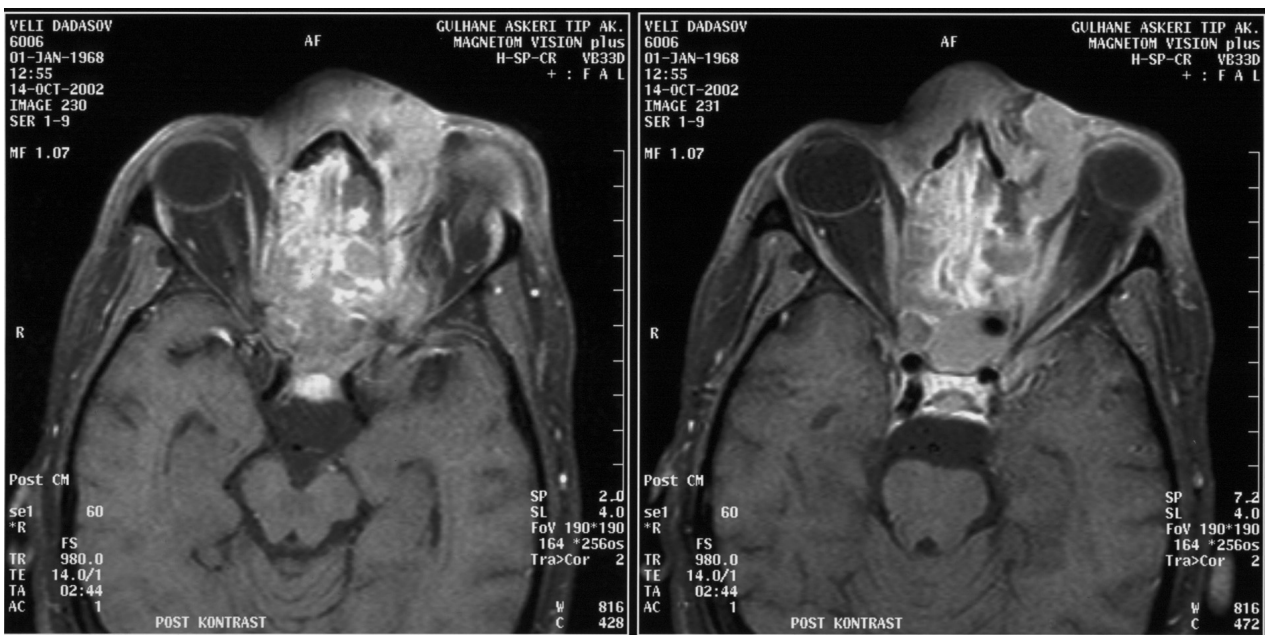

Figure 5. Axial T1 weighted, contrast enhanced MR images showing the disease which involved all paranasal sinuses, orbita, nasal cavity and hard palate.

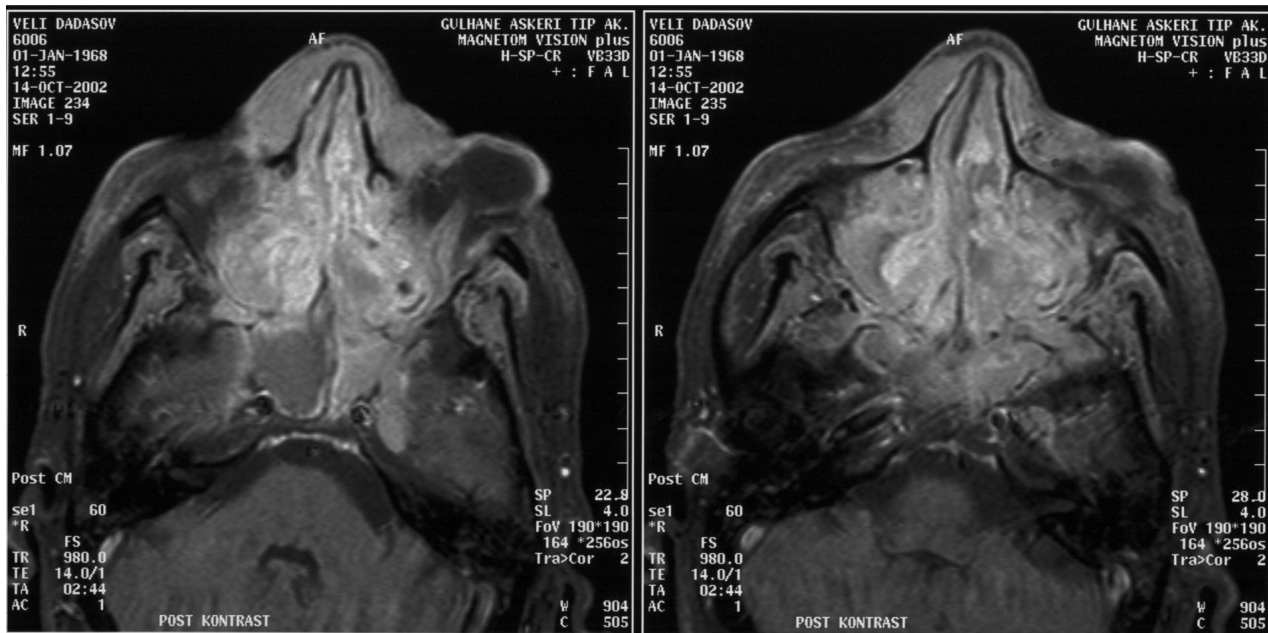


Figure 6. Axial T1 weighted, contrast enhanced MR images showing the disease which involved all paranasal sinuses, orbita, nasal cavity and hard palate.

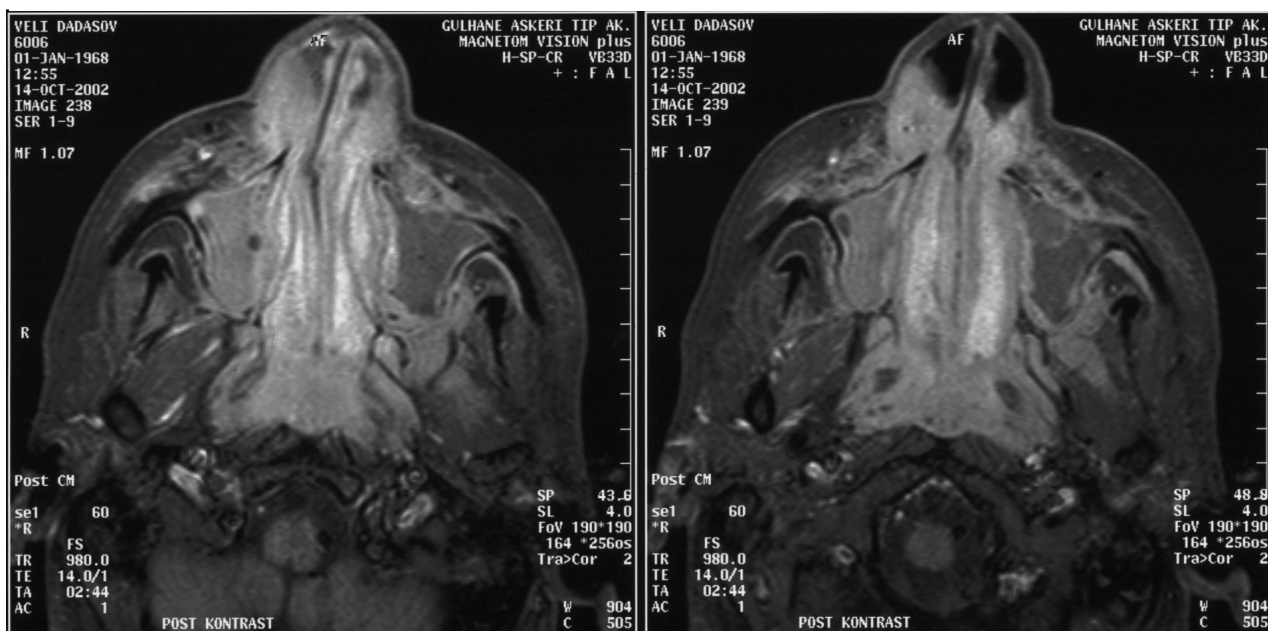


Figure 7. Axial T1 weighted, contrast enhanced MR images showing the disease which involved all paranasal sinuses, orbita, nasal cavity and hard palate.

mimicking a dental abscess of endodontic or periodontal origin (10). In contrast, a lesion arising in bone may present with a vague pain or discomfort which might be mistaken for toothache (9, 11, 12). The mass after tooth extraction on the hard palate was considered as a postoperative infection due to

tooth extraction in our case. Therefore a delay has been occurred in the diagnosis of the patient as (NHL), so still the management of the patient is remaining insufficient.

There is considerable evidence that lymphomas at specific sites are preceded by the

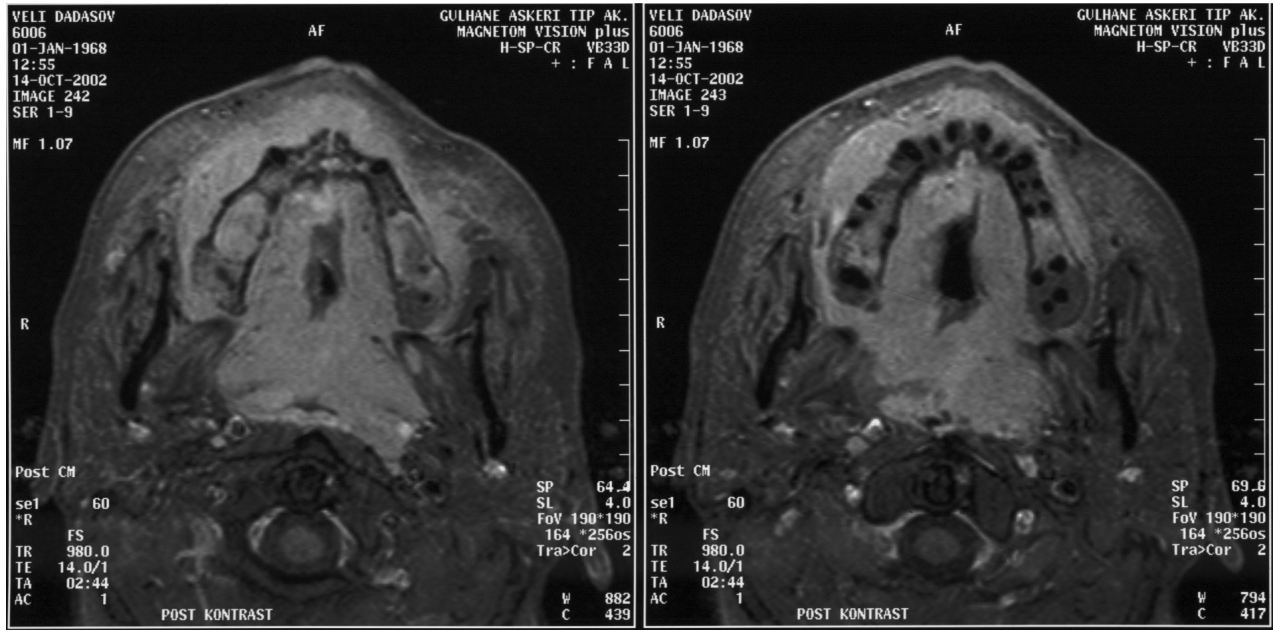


Figure 8. Axial T1 weighted, contrast enhanced MR images showing the disease which involved all paranasal sinuses, orbita, nasal cavity and hard palate.

presence of a local inflammatory process. It is speculated that inflammation increases the rate of cell division of lymphocytes, thereby increasing the chance of a malignant clone developing. The clinical features of oral lesions of NHL, and the radiographic appearance of an ill-defined or ragged radiolucency with loss of alveolar bone support, as in this case, may lead to confusion in diagnosis with infective processes such as osteomyelitis and other malignant conditions, for example squamous cell carcinoma or salivary gland tumours. Thus the importance of initial histological examination should not be underestimated (9).

Extra-nodal NHL of the oral cavity is a rare finding, however, patients with oral lesions of NHL commonly present at the dental clinic in the first instance. Any delay in diagnosis has important implications on the morbidity and mortality of the condition. Prompt diagnosis and rapid onset of treatment assure the best possible prognosis.

REFERENCES

1. Som P, Curtin HD: Head and Imaging, 3rd ed. St Louis, Mosby Inc, 1996, pp.521, 528
2. Jacobs C, Hoppe RT: Non-Hodgkin's lymphomas of head and neck extranodal sites. *Int J Radiation Oncology Biol Phys* 11: 357, 1985
3. Depena CA, Van Tassel P, Lee Y: Lymphoma of the head and neck. *Radiologic Clinics of North America* 28: 4, 1990

4. Eisenbud L, Sciubba J, Mir R, Sachs SA: Oral presentations in non-Hodgkin's lymphoma: A review of 31 cases. Part I. Data analysis. *Oral Surg Oral Med Oral Pathol* 56: 151, 1983
5. Nong DS, Fuller LM, Butler JJ: Extranodal NHL of the head and neck. *Am J Radiol* 123: 471, 1975
6. Menderhall NP: Lymphomas and related diseases presenting head and neck. *Management of head and neck cancer*. Philadelphia Pa: JB Lippincott, 1994, pp. 857
7. Ruijs CDM, Dekker AW, Van Kempen-Harteveld ML, Van Baarlen J, Hordijk GJ: Treatment of localized non-Hodgkin's lymphomas of the head and neck: *Cancer* 74: 703, 1994
8. Bacchaud JM, Coppin D, Douches J et al. Les lymphomes malins primitifs de la mandibule. *Etude des 3 cas et revue de la littérature*. *Rev Stomatol Chir Maxillofac* 93: 372, 1992
9. Parrington SJ, Punia-Moorty A: Primary Non-Hodgkin's lymphoma of the mandible presenting following tooth extraction. *Bri Dent J* 187: 468, 1999
10. Neville BW, Damm DD, Allen CM, Bouquot JE: *Oral and Maxillofacial Pathology*. Pennsylvania, WB Saunders, 1995, pp. 432
11. Griffin TJ, Hurst PS, Swanson J: Non-Hodgkin's lymphoma: A case involving four third molar extraction sites. *Oral Surg* 65: 671, 1988
12. Gusenbauer AW, Katsikeris NF, Brown A: Primary lymphoma of the mandible: Report of a case. *J Oral Maxillofac Surg* 48: 409, 1990

Geliş Tarihi: 25.03.2004

Yazışma Adresi: Özlem ÜÇÖK
GATA Dışhekimliği Bilimleri Merkezi
Oral Diagnoz ve Radyoloji AD,
Etilik, ANKARA
cucok@dentistry.ankara.edu.tr

[¶]The case report presented at 16th International Conference on Oral & Maxillofacial Surgery, Athens-Greece, 14-20 May 2003.