

# Fetal Intestinal Obstruction Associated with Prednisolone Use in Early Pregnancy: Case Report

## Erken Gebelikte Prednizolon Kullanımıyla İlişkili Fetal Barsak Obstrüksiyonu

Mine KANAT PEKTAŞ,<sup>a</sup>  
Ufuk YEŞİLDAĞER,<sup>a</sup>  
Cemile KURTTAY,<sup>a</sup>  
Afra KARAVELİOĞLU,<sup>b</sup>  
Didem BASKIN EMBLETON<sup>b</sup>

Departments of  
<sup>a</sup>Gynecology and Obstetrics,  
<sup>b</sup>Pediatric Surgery,  
Afyon Kocatepe University  
Faculty of Medicine, Afyonkarahisar

Geliş Tarihi/Received: 16.06.2013  
Kabul Tarihi/Accepted: 23.04.2014

*This case report was presented at  
11<sup>th</sup> National Congress of Gynecology and  
Obstetrics, 15-19 May 2013, Antalya*

Yazışma Adresi/Correspondence:  
Mine KANAT PEKTAŞ  
Afyon Kocatepe University  
Faculty of Medicine,  
Department of Gynecology and  
Obstetrics, Afyonkarahisar,  
TÜRKİYE/TURKEY  
minekanat@hotmail.com

**ABSTRACT** The present case report describes fetal intestinal obstruction which is associated with prednisolone use during the first four weeks of pregnancy. According to the Food and Drug Administration (FDA) classification system, prednisolone is a category C drug which may lead to cleft lip, cleft palate, stillbirth, neonatal cataract and adrenal gland suppression. A 28-year-old multiparous woman revealed that she conceived spontaneously while she was taking prednisolone (16 mg/day, orally) out of indication during an interval of 20 days after 15<sup>th</sup> day of the last menstrual period. Ultrasonographic examination showed dilated intestinal segments filling up the fetal abdomen at 32<sup>nd</sup> week of pregnancy. After the fetus was born at 34<sup>th</sup> week of pregnancy, laparotomy showed that the jejunum segment which was located distally to the ligament of Treitz was atretic and intestinal volvulus existed beyond the atretic segment.

**Key Words:** Embryonic development; intestinal atresia; prednisone sodium succinate

**ÖZET** Bu olgu sunumunda, gebeliğin ilk dört haftasında prednizolon kullanımıyla ilişkilendirilen fetal barsak obstrüksiyonu tanımlanmıştır. Teratojenite ile ilişkili Gıda ve İlaç Dairesi (FDA) sınıflandırmasına göre C kategorisinde bir ilaç olan prednizolon yarık dudak-damak, yenidoğan kataraktı, adrenal bez supresyonu ve ölü doğum gibi olumsuz perinatal sonuçlara yol açabilir. Yirmi sekiz yaşındaki multipar kadının, kilo almak amacıyla eczaneden reçetesiz olarak satın aldığı ve 16 mg metilprednizolon sodyum süksinat içeren ilacı, son adet tarihinin 15. gününden itibaren 20 gün boyunca, günde bir tane ağızdan aldığı ve aynı dönemde kendiliğinden gebe kaldığı belirlenmiştir. Gebeliğinin 32. haftasında yapılan ultrasonografi incelemesinde fetal abdomeni dolduran dilate barsak segmentlerinin saptanması ve doğum sonrası dönemde gerçekleştirilen laparotomide Treitz ligamentinin distalindeki jejunum segmentinde atrezi ve atrezik segmentin distalinde volvulus gözlemlendi.

**Anahtar Kelimeler:** Embriyonik gelişim; barsak atrezisi; prednizon sodyum süksinat

**Türkiye Klinikleri J Case Rep 2015;23(2):194-7**

**D**rug use in pregnancy is an issue of debate for the obstetricians and a matter of anxiety for all pregnant women. The reason is that potential teratogenic effects of most drugs are still undetermined. In fact, the utilization of drugs except iron, mineral and vitamin supplements are not recommended during pregnancy. However, the women with chronic diseases should use the prescribed drugs even if they got pregnant. Whenever a chronically ill woman has a pregnancy, the benefits of the prescribed drugs should be balanced against the potential perinatal risks that are related with the utilization of these drugs.<sup>1-3</sup>

doi: 10.5336/caserep.2013-36785

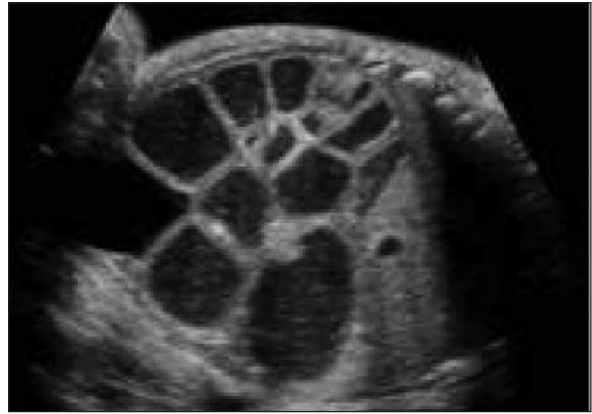
Copyright © 2015 by Türkiye Klinikleri

The present case report describes fetal intestinal obstruction which is associated with prednisone use during the first four weeks of pregnancy. Written informed consent was obtained from the reviewed subject.

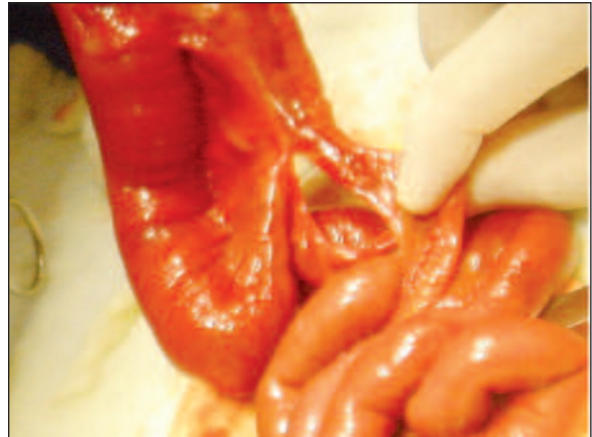## CASE REPORT

A 28-year-old multiparous woman (gravida 4, para 3) was admitted to the clinic for routine examination at 8th gestational week. It was learnt that she previously delivered three healthy children by vaginal route and there was no consanguinity in her marriage. The patient also revealed that she bought a drug consisting of methylprednisolone sodium succinate without prescription so that she could gain weight. According to the patient's history, she conceived spontaneously while she was taking prednisolone (16 mg/day) orally during an interval of 20 days after 15<sup>th</sup> day of the last menstrual period. Ultrasonographic examination showed a living embryo with crown-rump length of 16.7 mm (compatible with 8 weeks). Both the patient and her husband were informed about the probable adverse effects of prednisolone which was considered as a category C drug according to the Food and Drug Administration (FDA) classification system. First trimester screening for Down syndrome (nuchal translucency combined with serum free beta-HCG and PAPP-A measurements) performed at 12<sup>th</sup> gestational week yielded a risk of 1/1285.

The patient was lost to follow up till 32<sup>nd</sup> week of gestation. Ultrasonographic examination demonstrated dilated intestinal segments filling up the abdomen of a living fetus with normal amniotic fluid index (Figure 1). Despite the tocolysis with nifedipine, the patient delivered a baby girl weighing 2200 grams by vaginal route at 34<sup>th</sup> week of gestation. Although the newborn initially appeared normal, clinical symptoms complying with mechanical ileus (vomiting, irritability, abdominal distention, lack of bowel movements and flatulence) developed at the first day of life and emergency laparotomy was performed. It was observed that the jejunum segment which was located distally to the ligament of Treitz had undergone atresia and intestinal volvulus existed beyond the atretic intestinal segment.



**FIGURE 1:** Ultrasonographic examination demonstrated dilated intestinal segments filling up the abdomen of a living fetus at 32<sup>nd</sup> week of pregnancy.



**FIGURE 2:** The jejunum segment which was located distally to the ligament of Treitz had undergone atresia and intestinal volvulus existed beyond the atretic intestinal segment.

undergone atresia and intestinal volvulus existed beyond the atretic intestinal segment (Figure 2). After the involved intestinal segments were excised, ileostomy was opened and total parenteral nutrition was commenced.

## DISCUSSION

Teratology is the toxicology science which aims to investigate the fetal malformations that have an incidence varying between 3% and 10% within the population. Teratogenicity refers to the development of permanent structural malformations during embryogenesis whereas teratogens include hereditary factors, mutations, radiation, microor-

ganisms and chemical agents (including drugs) which cause fetal malformations. Drugs may exert teratogenic effects by means of damaging fetal DNA, impairing the uteroplacental perfusion, disturbing the tissue differentiation and inhibiting the uptake of minerals, vitamins and other compounds which are necessarily required for embryogenesis.<sup>4-6</sup>

Widely adopted classification systems for the definite and probable teratogenic effects of drugs can be listed as the FDA system, the Australian Drug Evaluation Committee (ADEC) System and the Teratogen Information System (TERIS). The FDA classification system is usually cited by the handouts of the prescribed drugs in Turkey. This classification system for teratogenicity risk consists of A, B, C, D and X categories.<sup>1-3</sup>

Category C specifies that animal reproduction studies have shown an adverse effect on fetus and there are no adequate and well-controlled studies in humans, but potential benefits may warrant its utilization in pregnancy in spite of potential risks.<sup>6</sup>

Prednisolone is the metabolically active form of prednisone which is a synthetic corticosteroid. Acting via suppression of immune system, prednisolone is commonly prescribed to treat chronic obstructive pulmonary diseases, inflammatory bowel diseases, allergic reactions, adrenocortical insufficiency, multiple sclerosis, nephritic syndrome, myasthenia gravis and migraine. Moreover, prednisolone is usually used to treat leukemia, lymphoma and multiple myeloma as well as recipients of tissue and organ transplantation. Hyperglycemia, weight gain, edema, visual disturbances, mental and emotional problems have been assigned among the side effects of prednisone.<sup>7</sup>

Prednisolone has been designated as a category C drug because it has been exhibited that prednisolone use during animal reproduction results in congenital anomalies such as cleft lip and cleft palate. In addition, observational data have manifested that prednisolone use during human pregnancy is associated with congenital anomalies such as cleft lip and cleft palate as well as adverse perinatal outcomes including stillbirth, neonatal

cataract, and neonatal adrenal gland suppression. However, to the best of our knowledge, fetal intestinal obstruction in association with prednisolone use in pregnancy has not been reported till date.<sup>6,7</sup> Previously published studies have concluded that prednisolone phosphate encapsulated in long-circulating liposomes may exert anti-tumor activity through the inhibition of tumor angiogenesis. It has been demonstrated that the anti-tumor activity of prednisolone is due to its anti-proliferative effects on angiogenic endothelial cells.<sup>8,9</sup>

The incidence of neonatal intestinal obstruction has been reported as 1/1500 live births. In fact, intestinal obstruction refers to the complete annihilation of intestinal lumen. Although obstruction can occur anywhere in the gastrointestinal tract, such an anomaly is most commonly present in the proximal jejunum (30%) and distal ileum (35%). Male and female babies are equally affected by this congenital malformation which may be accompanied with malrotation (23%), meconium peritonitis (8%), microcolon (3%), duplication cysts (3%), esophageal atresia (3%), volvulus, gastrochisis and placental vascular abnormalities.<sup>10-12</sup>

Small bowel obstruction is usually unassociated with chromosomal abnormalities. Although several familial cases have been described, no specific gene related with fetal intestinal obstruction has been identified. The etiopathogenesis of small bowel obstruction has not been clarified definitely. However, it has been proposed that any ischemic insult to the developing midgut may cause small bowel atresia.<sup>13,14</sup>

As for the present case, the consumption of prednisolone in the first three weeks of embryogenesis can be the underlying cause for fetal jejunal atresia and subsequent volvulus. It has been hypothesized that the anti-proliferative effects of prednisolone on angiogenic endothelial cells might have contributed to the interruption in the perfusion of developing intestinal tissues and, thus, led to the aforementioned small bowel malformations. The lack of consanguinity and the non-existence of any associated congenital anomaly or chromosomal abnormality further support this hypothesis.

The present case report proposes that fetal intestinal obstruction may be listed as one of the adverse perinatal outcomes associated with prednisolone use during the first four weeks of

pregnancy. Further research is warranted to confirm the probable role of prednisolone use in the emergence of fetal intestinal obstruction during the last trimester of pregnancy.

## REFERENCES

1. Bakker MK, Jentink J, Vroom F, Van Den Berg PB, De Walle HE, De Jong-Van Den Berg LT. Drug prescription patterns before, during and after pregnancy for chronic, occasional and pregnancy-related drugs in the Netherlands. *BJOG* 2006;113(5):559-68.
2. Hardy JR, Leaderer BP, Holford TR, Hall GC, Bracken MB. Safety of medications prescribed before and during early pregnancy in a cohort of 81,975 mothers from the UK General Practice Research Database. *Pharmacoepidemiol Drug Saf* 2006;15(8):555-64.
3. Schirm E, Meijer WM, Tobi H, de Jong-van den Berg LT. Drug use by pregnant women and comparable non-pregnant women in The Netherlands with reference to the Australian classification system. *Eur J Obstet Gynecol Reprod Biol* 2004;114(2):182-8.
4. Yanık FF. [Teratogenicity and the fetus]. *Türkiye Klinikleri J Gynecol Obst-Special Topics* 2011;4(4): 245-9.
5. Kadioğlu Duman M, Kalyoncu Nİ. [Drug choice in pregnancy and teratogenicity information services]. *Türkiye Klinikleri J Surg Med Sci* 2006;2(46):63-8.
6. Adam MP, Polifka JE, Friedman JM. Evolving knowledge of the teratogenicity of medications in human pregnancy. *Am J Med Genet C Semin Med Genet* 2011;157C(3):175-82.
7. Webster WS, Freeman JA. Prescription drugs and pregnancy. *Expert Opin Pharmacother* 2003;4(6):949-61.
8. Banciu M, Metselaar JM, Schiffelers RM, Storm G. Antitumor activity of liposomal prednisolone phosphate depends on the presence of functional tumor-associated macrophages in tumor tissue. *Neoplasia* 2008;10(2):108-17.
9. Banciu M, Metselaar JM, Schiffelers RM, Storm G. Liposomal glucocorticoids as tumor-targeted anti-angiogenic nanomedicine in B16 melanoma-bearing mice. *J Steroid Biochem Mol Biol* 2008;111(1-2):101-10.
10. Baglaj M, Carachi R, Lawther S. Multiple atresia of the small intestine: a 20-year review. *Eur J Pediatr Surg* 2008;18(1):13-8.
11. Iacobelli BD, Zaccara A, Spiridakis I, Girolandino C, Capolupo I, Nahom A, et al. Prenatal counselling of small bowel atresia: watch the fluid! *Prenat Diagn* 2006;26(3):214-7.
12. Wax JR, Hamilton T, Cartin A, Dudley J, Pinette MG, Blackstone J. Congenital jejunal and ileal atresia: natural prenatal sonographic history and association with neonatal outcome. *J Ultrasound Med* 2006;25(3):337-42.
13. Sweeney B, Surana R, Puri P. Jejunoileal atresia and associated malformations: correlation with the timing of in utero insult. *J Pediatr Surg* 2001;36(5):774-6.
14. Komuro H, Amagai T, Hori T, Hirai M, Matoba K, Watanabe M, et al. Placental vascular compromise in jejunoileal atresia. *J Pediatr Surg* 2004;39(11):1701-5.