

# Cavum Septum Pellucidum Which was Diagnosed After Septoplasty and Adenoidectomy Operation Under General Anesthesia: Case Report

## Genel Anestezi Altında Septoplasti ve Adenoidektomi Operasyonundan Sonra Tanı Konulan Cavum Septum Pellucidum

Onur HANBEYOĞLU,<sup>a</sup>  
Aykut URFALIOĞLU,<sup>b</sup>  
Sibel ÖZCAN,<sup>c</sup>  
Sertaç DÜZER<sup>d</sup>

Clinics of

<sup>a</sup>Anesthesiology and Reanimation,

<sup>c</sup>Ear, Nose and Throat,

Elazığ Training and Research Hospital,  
Elazığ

<sup>b</sup>Department of Anesthesiology and  
Reanimation,

Kahramanmaraş Sütçü Imam University  
Faculty of Medicine,  
Kahramanmaraş

<sup>d</sup>Department of Anesthesiology and  
Reanimation,

Firat University Faculty of Medicine  
Elazığ

Geliş Tarihi/Received: 06.01.2016

Kabul Tarihi/Accepted: 19.06.2016

Yazışma Adresi/Correspondence:

Sibel ÖZCAN

Firat University Faculty of Medicine,

Department of Anesthesiology and

Reanimation, Elazığ,

TURKEY/ TÜRKİYE

dr.sibelcozcan@gmail.com

**ABSTRACT** Cavum septi pellucidi (CSP), cavum vergae (CV) and cavum veli interpositi (CVI), which are congenital midline brain cysts which are rare, and still have controversial etiologies, developments and treatments. In this paper, it was aimed to introduce the case of detecting CSP cysts and applying medical treatment for the patients who developed loss of consciousness and loss of power in the left limbs, 6 hours after a septoplasty and adenoidectomy. As a result; One should take into account that CSP and CV cysts sometimes could become symptomatic, acute cerebrovascular events could occur during and after the surgical intervention, so that the one should be careful regarding the management of anaesthesia.

**Key Words:** Anesthesia, general; brain ischemia

**ÖZET** Cavum septi pellucidi (CSP), cavum vergae (CV) ve cavum veli interpositi (CVI), nadir konjenital orta hat beyin kistleri olup, ve hala etyolojisi, gelişmesi ve tedavisi hala tartışmalıdır. Bu yazıda, septoplasti ve adenoidektomiden 6 saat sonra sol bacakta güç kaybı ve bilinç kaybı gelişen hastada CSP kistinın tespiti ve uygulanan medikal tedavinin sunulması amaçlanmıştır. Sonuç olarak; cerrahi sırasında ve sonrasında semptomatik olabileceği ve akut serebrovasküler olaylar oluşabileceğinden CSP ve CVI kistleri dikkate alınmalıdır, bu yüzden anestezi uygulamasında dikkatli olmak gerekmektedir.

**Anahtar Kelimeler:** Anestezi, genel; beyin iskemisi

**Türkiye Klinikleri J Case Rep 2016;24(4):329-32**

Congenital midline brain cysts like cavum septa pellucidi (CSP), cavum vergae (CV) and cavum veli interpositi (CVI) are rare lesions and still have controversial etiologies, developments and treatments.<sup>1-6</sup> They rarely create significant neurological dysfunctions. These cysts usually carry no clinical importance.<sup>7,8</sup> Few cases have been reported in the literature that has gone in symptomatic expansion and treated.<sup>1-4,6,9</sup> In this case report, it was aimed to introduce the case of a loss of consciousness and strength in the left extremities, within the 6<sup>th</sup> hour following a septoplasty and adenoidectomy operation under general anesthesia and the identification of CSP et vergae with the examinations which is followed by medical treatment.

doi: 10.5336/caserep.2016-50029

Copyright © 2016 by Türkiye Klinikleri

## CASE REPORT

A 22 year old, 60 kg, 162 cm tall female patient, planned for nasal septum deviation and adenoidectomy after she applied to Otolaryngology clinic with her complaints has been diagnosed with nasal septum deviation and adenoid hypertrophy and planned for septoplasty and adenoidectomy operation. No specific feature observed in the preoperative anesthetic evaluation resume. Blood pressure (BP) was 110/70 mmHg and heart rate was measured 75/min. In the preoperative evaluation of patient, who was identified as American Society of Anesthesiology (ASA)-I, she was induced with thiopental 300 mg, 50 µg fentanyl, 30 mg of rocuronium. In maintenance, 2% sevoflurane, 40% O<sub>2</sub> + 60% dry air mixture continued. Hemodynamic changes during operation remained stable. The surgical procedure was completed in 40 minutes. She was extubated in 42<sup>th</sup> minutes when she had enough spontaneous breathing and then she opened her eyes in 43<sup>th</sup> minutes and taken into the recovery room. Once delivered to the patient room, within the sixth hour of recovery, because she suffered strength loss in her left upper and lower extremities and as loss of consciousness, she was evaluated by a neurologist and her brain computerized tomography (CT) has been assessed as normal. As symptoms persisted, a diffusion magnetic resonance imaging (MRI) was done and an acute ischemia was detected in the right temporo-frontoparietal, she was referred to neurology clinic in the tertiary center. There, with the taken control CT, a hypodense area (ischemic infarction) causing 9 mm of shift to the left in the midline structures, and deletion in the sulci and fissures extending to the right frontotemporoparietal cortex, and also cavum septum pellucidi et vergae variation were observed (Figures 1,2). She received 5000 unit bolus of heparin iv and 1000 unit/hr infusion for 12 hour and then continued with low molecular weight heparin and acetylsalicylic acid. She received 4x100 ml mannitol 20% as treatment of anti-edema for 3 days. The patient had normally carotid vertebral doppler ultrasonography and echocardiography. Vasculitis markers (ACA IGG,

ACA IGM, ACA IGA, ANCA P, ANCA C, ANTI-TISM, ds DNA, JO-1, ANTI-LA, ANTI RO) which were examined to explain the etiology were normal. She was discharged on the 10<sup>th</sup> day of treatment and physical therapy has been initiated for the loss of strength in the lower and upper extremities. At the clinic control, methylenetetrahydrofolate reductase (MTHFR) gene mutations of patient were negative but plasminogen activator inhibitor-1 (PAI-1) was heterozygous positive.

## DISCUSSION

CSP was first defined by Franciscus De Le Bon as an abnormal component of the ventricular system and was identified as the 5<sup>th</sup> ventricle. CV was first defined by Italian anatomist Vergae in 1851 and was later identified as the 6<sup>th</sup> ventricle.<sup>5,9</sup> Cavity wall contains glial fibers, astrocytes and subarachnoid cells.<sup>5,9</sup> The source of the liquid in the cavity is controversial. Some authors have suggested that these cells arise from residual subarachnoid fluid. There is also no common concept about the naming of this cavity. Some authors use the term "enlarged CSP and CV"; Some others use "CSP and CV cysts".<sup>1,2,4,9,10</sup> In this report we used the widely used "CSP cyst" term. CSP and CV are in fact the same structures, and they are two cavities, in relationship with a channel called aqueduct septa, one being in the anterior and the other in posterior.<sup>11</sup> While CSP intrauterine was observed in 85-100% in life and in premature, it was observed in adults as 15-20%.<sup>1,9,12</sup> CV incidence in adults is about 1-3% CSP is limited with the genu of the corpus callosum in rostral direction, and column fornix in caudal direction.<sup>1,6,10</sup> CV however; is limited with column fornix in rostral direction, and with trunk and splenium of corpus callosum in the caudal direction.<sup>2,7</sup> It's been reported that CSP cyst is seen more often in the literature, and CV cyst is rather less frequent, and usually reported in association with CSP.<sup>1,4,8,11</sup> There are a few isolated cases that have been reported as CVE cysts.<sup>2,5,10</sup> One can detect with an MRI if the cyst is CSP or CV or a combination of both. In the case introduced herein, in the MRI images, it can be seen that the cyst is a CSP with its localization and neighbor-

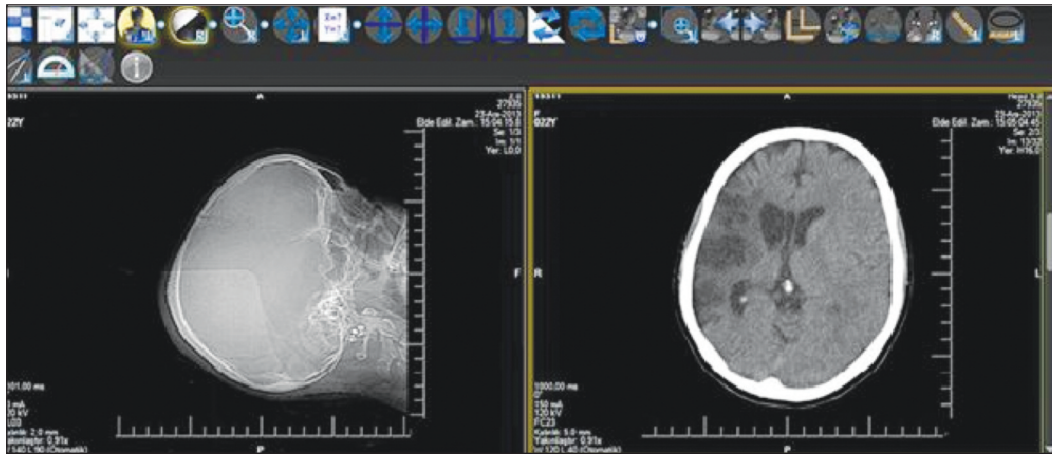


FIGURE 1: Brain computerized tomography of patient following a septoplasty and adenoidectomy surgery and the identification of cavum septi pellucidum.

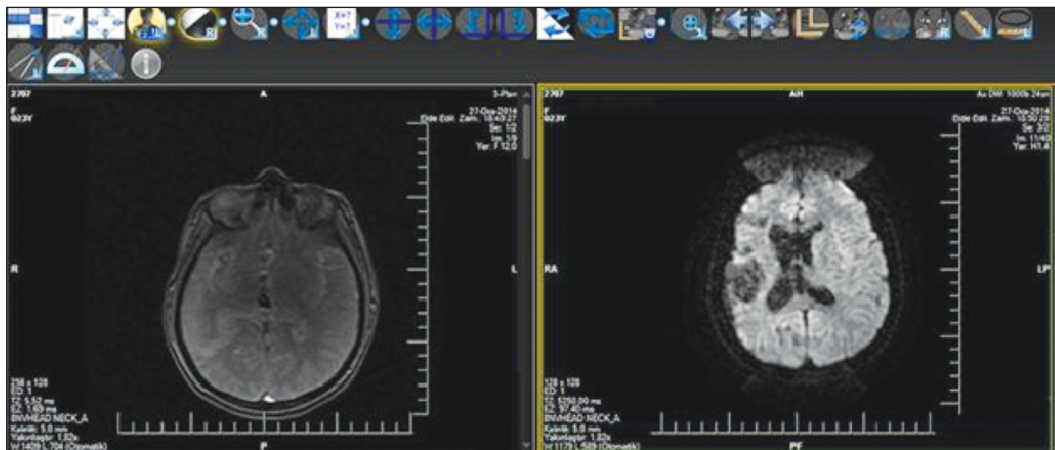


FIGURE 2: Diffusion magnetic resonans imaging of patient following a septoplasty and adenoidectomy surgery and the identification of cavum septi pellucidum.

hood. Shaw and Alvord in a study they conducted in an autopsy, have investigated the relationship between ventricular system and CV cysts.<sup>11</sup> The authors reported that they detected two types of CV cyst; 1 communicating (asymptomatic) and 2 non-communicating (symptomatic) types. At the same time they reported that due to the increase in intracranial pressure and local pressure effects of symptomatic CV cysts, they require surgical treatment. Donati has stated that in such cases, the most common signs and symptoms are headache, vomiting, sensorial and behavioral disorders, and papilledema.<sup>4</sup> In this case, the postoperative clinical assessment has revealed acute impairment of consciousness, and weakness in left arm and leg. CSP and CV cysts which are developmental midline

cysts, should be treated when they are symptomatic.<sup>1,2,4,5,7-9</sup> First time, two cases of symptomatic CSP cysts published with anastomosis of cyst and ventricular with transcallosal approach.<sup>5</sup> Treatment methods of these lesions which have been and still being applied are kiston-ventriculostomy with craniotomy, kiston-peritoneal shunt, and stereotactic kiston-shunt applications.<sup>1,6-9,13,14</sup> These methods provide several advantages and disadvantages relative to one another. Medical treatment was applied in the case presented here. The patient in the case was treated with acute ischemia, anti-edema and anticoagulant treatments and gained consciousness, and physical therapy has been initiated for the loss of strength in the lower and upper extremities.

Another interesting detail in this case is that in the interview done after the surgery, it's been found out that patient's mother also had a stroke incident nearly 15 years ago and there is presence of left hemiplegic sequelae accordingly. There could not be reached any other information about the mother here. In the literature, no information could be found related to CSP or CV that these formations do not cause stroke directly. But as in this case, the idea that the CSP cyst being effected by the intracranial pressure changes during the operation, and this contributing to the formation of a cerebrovascular ischemia and again, the patient's mother having a history of stroke at an early age, could suggest that a genetic coagulation defect. In this case (PAI-1) there was heterozygous positive. PAI-1 is a strong inhibitor of fibrinolysis. The human PAI-1 gene is SERPINE 1 and is located on chromosome 7 (7q21.3-q22). The following three genotypes of the PAI-1 are possible; 5G/5G normal, 4G/5G heterozygous, 4G/4G homozygous. Heterozygous form have increased PAI-1 activity and

homozygous form have significantly increased PAI-1 activity. 4G/5G polymorphism seems to be a useful marker of fibrinolytic activity and thrombogenic predisposition. Furthermore, there are indications suggesting a significant effects of this genotype on the risk of ischemic stroke in acute stressful diseases through synergy with other pro-coagulant factors.<sup>15</sup>

Although there are some studies about CSP in the literature, there is no study about anesthetic management in the patient with CSP. In this case routine general anesthesia was performed because there was no information about CSP, preoperatively. Although Cavum septi pellucidi et vergae variations are seen as normal congenitally, we think that one should be careful in anesthetic management considering that in some cases it can continue in the form of cysts in adulthood, can be identified with imaging techniques, and especially in the cases with identified family history preoperatively, during and after surgical intervention, acute cerebrovascular incidents might occur.

## REFERENCES

1. Bayar MA, Gökçek C, Gökçek A, Edebali N, Buharali Z. Giant cyst of the cavum septi pellucidi and cavum Vergae with posterior cranial fossa extension: case report. *Neuroradiology* 1996;38(Suppl 1):S187-9.
2. Behrens P, Ostertag CB. Stereotactic management of congenital midline cysts. *Acta Neurochir (Wien)* 1993;123(3-4):141-6.
3. Zhang X, Huang G, Ji T, Liu W, Gao Y, Li W. Sellar cysticercosis and septum pellucidum cyst: a case report and review of the literature. *Southeast Asian J Trop Med Public Health* 2014;45(3):584-7.
4. Donati P, Sardo L, Sanzo M. Giant cyst of the cavum septi pellucidi, cavum Vergae and veli interpositi. *Minim Invasive Neurosurg* 2003;46(3):177-81.
5. Donauer E, Moringlane JR, Ostertag CB. Cavum vergae cyst as a cause of hydrocephalus "almost forgotten"? Successful stereotactic treatment. *Acta Neurochir (Wien)* 1986;83(1-2):12-9.
6. Sencer A, Sencer S, Turantan I, Devencioglu O. Cerebrospinal fluid dynamics of the cava septi pellucidi and vergae. Case report. *J Neurosurg* 2001;94(1):127-9.
7. Nakajima Y, Yano S, Kuramatsu T, Ichiashi K, Miyao M, Yanagisawa M, et al. Ultrasonographic evaluation of cavum septi pellucidi and cavum Vergae. *Brain Dev* 1986;8(5):505-8.
8. Schwidde JT. Incidence of cavum septi pellucidi and cavum Vergae in 1,032 human brains. *AMA Arch Neurol Psychiatry* 1952;67(5):625-32.
9. Rossitch E Jr, Watkins RH. Developmental midline intracranial cysts. In: Wilkins RH, Rengachary SS, eds. *Neurosurgery Update II*. 1sted. New York: McGraw-Hill; 1991. p.289-90.
10. Sahinoglu Z, Uludogan M, Delikara M. Prenatal sonographic diagnosis of dilated cavum vergae. *J Clin Ultrasound* 2002;30(6):378-83.
11. Shaw CM, Alvord EC Jr. Cava septi pellucidi et vergae: their normal and pathological states. *Brain* 1969;92(1):213-23.
12. Heiskanen O. Cyst of the septum pellucidum causing increased intracranial pressure and hydrocephalus. Case report. *J Neurosurg* 1973;38(6):771-3.
13. Fratzoglou M, Grunert P, Leite dos Santos A, Hwang P, Fries G. Symptomatic cysts of the cavum septi pellucidi and cavum vergae: the role of endoscopic neurosurgery in the treatment of four consecutive cases. *Minim Invasive Neurosurg* 2003;46(4):243-9.
14. Nishijima Y, Fujimura M, Nagamatsu K, Kohama M, Tominaga T. Neuroendoscopic management of symptomatic septum pellucidum cavum vergae cyst using a high-definition flexible endoscopic system. *Neurol Med Chir (Tokyo)* 2009;49(11):549-52.
15. Tsantes AE, Nikolopoulos GK, Bagos PG, Tsiara CG, Kapsimali V, Travlou A, et al. Plasminogen activator inhibitor-1 4G/5G polymorphism and risk of ischemic stroke: a meta-analysis. *Blood Coagul Fibrinolysis* 2007;18(5):497-504.