

# A Rare Muscular Variation: The Occipito-Scapularis Muscle: Case Report

## Nadir Musküler Varyasyon: M. Occipito-Scapularis

Ragıba ZAĞYAPAN, MD,<sup>a</sup>  
Can PELİN MD,<sup>a</sup>  
Nüket MAS, MD<sup>b</sup>

<sup>a</sup>Department of Anatomy,  
Başkent University,  
Faculty of Medicine, ANKARA

<sup>b</sup>Department of Anatomy,  
Afyon Kocatepe University,  
Faculty of Medicine, AFYON

Geliş Tarihi/Received: 17.07.2006  
Kabul Tarihi/Accepted: 26.09.2006

Yazışma Adresi/Correspondence:  
Can PELİN, MD,  
Başkent University,  
Faculty of Medicine,  
Department of Anatomy, ANKARA  
can\_pelin@yahoo.co.uk

**ABSTRACT** Classically, it is known that the occipito-scapularis muscle is not present in humans and when present its shape, size or localization are variable. In the present case, unilateral presence of the occipito-scapularis muscle was determined during routine neck dissection of a 37-year-old male cadaver. This additional muscle originated from the superior angle of the scapula, just between the origins of the levator scapula and the rhomboideus minor muscles. Its fascicles ran parallel to each other superomedially with angles of 40-45° to the midline to insert on the occipital bone, just at the medial part of the superior nuchal line. Since a large number of diagnostic or surgical invasive procedures may be carried out on this region such a variation could be of clinical significance. In the present case, an unusual occipito-scapularis muscle at the neck region was investigated in a routine dissection, and its relations with the adjacent structures were evaluated.

**Key Words:** Surgical procedure; anatomy

**ÖZET** M. occipito-scapularis normal insan anatomik yapısında yer almamaktadır. Bulunduğu durumlarda ise şekil, boyut ve konum açısından çeşitli varyasyonlar gösterebilmektedir. Bu olguda 37 yaşındaki erkek kadavra üzerinde gerçekleştirilen rutin disseksiyon çalışması sırasında boyun bölgesi sol tarafında m. occipito-scapularis'in tek taraflı olarak varlığı gösterildi. Kasın scapula'nın angulus superior'undan, m. levator scapula ile m. rhomboideus minorün arasından başladığı, kas liflerinin birbirlerine paralel konumda orta hat ile 40-45° açı yaparak superomedial yönde ilerlediği ve linea nuchae superior'un hemen medial kısmında os occipitale'ye yapıştığı belirlendi. Boyun bölgesinde tanınal ya da cerrahi amaçla çok sayıda girişimin gerçekleştirildiği göz önünde bulundurulacak olursa bu tarz bir varyasyonun klinik açıdan önem taşıyacağı yadsınmaz. Bu olguda boyun sol tarafında normalde insanda bulunmaması gereken m. occipito-scapularis gözlenmiş ve komşu yapılarla ilişkisi değerlendirilmiştir.

**Anahtar Kelimeler:** Cerrahi prosedür; anatomi

**Türkiye Klinikleri J Med Sci 2008, 28:87-90**

The neck musculature is architecturally complex. More than 20 pairs of neck muscles play a role in head movements. Many muscles cross over two or more joints and have multiple attachments to different bones. In addition to ensuring movement or fixation, they also transmit loads to underlying bones and connective tissues. The muscles that are attached to the scapula protract the bone, hold it against the chest wall and act as an anchor for this bone allowing other muscles to use it as a fixed bone to produce the movements of the humerus. Neck muscles must also stabilize the head, neck, and thoracic segments relative to each other to maintain posture and resist undesirable perturbations. There are interindividual dif-

ferences in the number and location of tendinous insertions of the neck muscles, particularly of the scalens and longissimus capitis muscles. On the other hand, rhomboid muscles show significant variations in size and shape.<sup>1</sup> Occipito-scapularis is an additional neck muscle that normally does not exist in human beings. It often performs multiple tasks as architectural adaptations and functional optimization.<sup>1</sup>

Such variations have long received the attention of anatomists and clinicians for surgical approaches of the neck region. Additionally, the knowledge on occipito-scapularis muscle may ensure safe surgical procedures such as convenient flap thickness, satisfactory size, and reliable reconstructive procedure when it is present.<sup>2</sup>

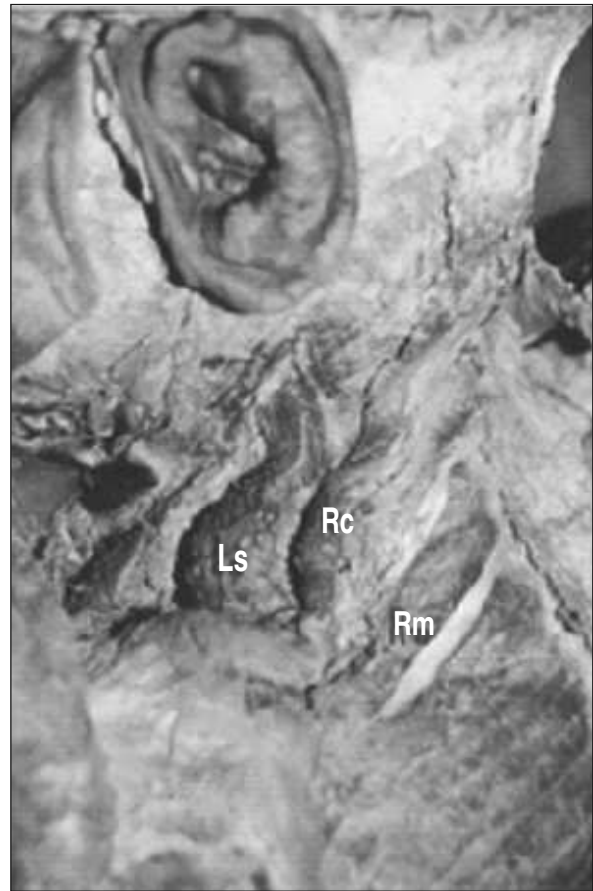
In the present case an unusual occipito-scapular muscle in the neck region was investigated in a routine cadaver dissection and its relations with adjacent structures were evaluated.

## CASE REPORT

During a routine dissection of a 37-year-old male cadaver, an additional muscle was detected at the neck region on the left side. It was a thick strap like muscle beneath the nuchal layer of deep cervical fascia. This additional muscle originated from the superior angle of the scapula, just between the origins of the levator scapula and the rhomboideus minor muscles (Figure 1). Its fascicles ran parallel to each other superomedially with angles of 40-45° to the midline to insert on the occipital bone, just at the medial part of the superior nuchal line (Figure 2). The lower end of the levator scapula overlapped the most of inferior fascicles of the muscle. Based on its localization and course in the neck region, that additional muscle was thought to be the occipito-scapular muscle (Figure 2). The muscle seemed to receive its blood supply from the transvers cervical branch of the subscapular artery and the dorsal scapular nerve innervated it.

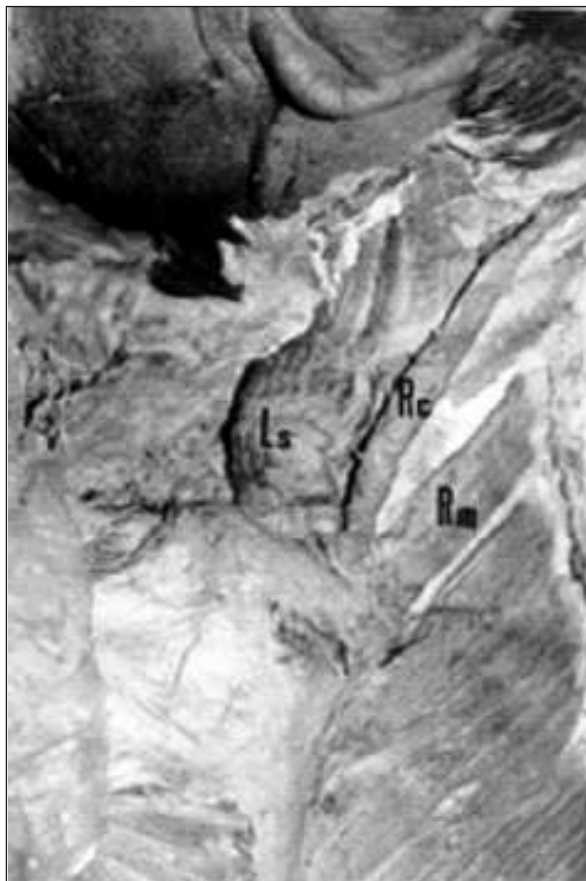## DISCUSSION

The anatomy of the suboccipital region and neck region is quite complex and may present a constellation of clinical and morphological chal-



**FIGURE 1:** Origin of the occipito-scapular muscle and its relation with the adjacent structures are shown. Ls: Levator scapula muscle, Rc: Occipito-scapular muscle, Rm: Rhomboideus minor muscle.

lenges to clinicians and surgeons. Numerous morphological variations in the neck region were observed and were reported up to date. Sternocleidooccipital, sternomastoid and cleidomastoid muscles, levator clavicula muscle are some examples for such variations.<sup>3,4</sup> These supernumerary muscles include platysma occipitalis, deltopectoral complex, latissimocondyloideus, pectorodorsalis, chondrohumeralis, and peroneus digiti quinti.<sup>5</sup> In addition to muscles that are not present in anatomical nomenclature, variations were also observed at the origin or insertion points.<sup>6</sup> In the earlier descriptions, this additional muscle was named as the occipito-scapularis and the rhomboideus-occipitalis or the rhomboideus capitis.<sup>7</sup> Comprehensive dissections of aneuploid (trisomy 18 and 13) neonates have also revealed numerous supernumerary muscles mainly in the



**FIGURE 2:** Insertion of the occipito-scapular muscle and its relation with the adjacent structures are shown. Ls: Levator scapula muscle, Rc: Occipito-scapular muscle, Rm: Rhomboideus minor muscle.

upper extremity that are not regularly present in the human.<sup>8</sup>

It is well known that the rhomboides capitis muscle is not normally present in man. As mentioned above, it was reported as an embryological anomaly in a case of Edwards' syndrome (18-trisomy), however such cases are few.<sup>7,8</sup> In dogs the rhomboides capitis muscle originated on the dorso-cranial border of the scapula, and inserted on the nuchal crest.<sup>9</sup> In the present case, the additional occipito-scapular (rhomboides capitis) muscle was observed on the left side arising from the superior margin of the scapula at the point of the superior angle, just between the levator scapula and rhomboides minor muscles. It originates mainly from the dorsal surface of the scapula as Rogawski mentioned in his study.<sup>7</sup> In the earlier descriptions, the muscle was named as

the occipito-scapularis and the rhomboides-occipitalis or capitis. Rogawski reported that the muscle was called rhomboides capitis which attached cranially to the occipital bone and caudally to the scapula.<sup>7</sup> In the present case, the scapula-occipitalis muscle was attached cranially to the occipital bone and was related to the splenius capitis muscle. The muscle was inserted caudally to the scapula and was closely related to the rhomboides minor and the levator scapulae muscles. In contrast to Rogawski's finding, the muscle was not related with the splenius capitis muscle caudally.<sup>7</sup>

Detailed anatomical knowledge of the neck region is of importance not only for surgical approaches, but also for a reliable diagnosis. Sometimes morphological asymmetries may be misdiagnosed as a mass in the region. Shpizner and Holliday in their study mentioned that patients with unilateral hypertrophy of the levator scapula muscle had undergone radical neck dissection. They also emphasized that a muscle with a normal structure could be perceived as a neck mass due to the atrophy of the muscle at the contralateral side.<sup>10</sup> In some cases as in our patient, the muscles that are not normally present, may be misdiagnosed as a mass. Levator scapula syndrome is defined with a pain at the upper medial angle of the scapula with movements that stretch the levator scapula. This syndrome is probably caused by bursitis at the region. Such a syndrome may be due to anatomic variations at the insertion of the levator scapula and the origin of the serratus anterior.<sup>6</sup> Presence of an additional muscle in the region such as occipito-scapularis may cause similar symptoms.

In surgical approaches, especially in flap surgery, presence of additional muscles may cause confusion. For instance in surgical dissections due to gingivobuccal sulcus tumors, the levator scapula muscle forms a part of the floor of the operative field, lying behind the scalenus posterior muscle and is used to construct the floor of the mouth.<sup>11</sup> Presence of an additional occipito-scapular muscle

close to the levator scapula may easily confuse the surgeon as it may be thought to be a part of the levator scapula. On the other hand, this additional muscle may be used as a flap instead of the levator scapula.

This case emphasizes that, though it is rare, the occipito-scapular muscle may exist in man. To have detailed information about its localization in the neck region is without doubt of importance for clinicians and for anatomists as well.

## REFERENCES

1. Kamibayashi LK, Richmond FJ. Morphometry of human neck muscles. *Spine* 1998;23:1314-23.
2. Williams PL, Bannister LH, Berry MM, Collins P, Dyson M, Dussek JE, et al. Muscle. In: Salmons S, ed. *Gray's Anatomy*. 38th ed. London, England: Churchill-Livingstone; 1995. p.808-13, 837-8.
3. Coskun N, Yildirim FB, Ozkan O. Multiple muscular variations in the neck region-case study. *Folia Morphol (Warsz)* 2002;61:317-9.
4. Rüdüsüli T. Demonstration of a musculus levator claviculae. *Surg Radiol Anat* 1995;17:85-7.
5. Aziz MA. Possible "atavistic" structures in human ane-uploids. *Am J Phys Anthropol* 1981;54:347-53.
6. Menachem A, Kaplan O, Dekel S. Levator scapulae syn-drome: An anatomic-clinical study. *Bull Hosp Jt Dis* 1993;53:21-4.
7. Rogawski KM. The rhomboideus capitis in man-correctly named rare muscular variation. *Okajimas Folia Anat Jpn* 1990;67:161-3.
8. Aziz MA. Muscular and other abnormalities in a case of Edwards' syndrome (18-trisomy). *Teratology* 1979;20:303-12.
9. Sharir A, Milgram J, Shahar R. Structural and functional anatomy of the neck musculature of the dog (*Canis familiaris*). *J Anat* 2006;208:331-51.
10. Shpizner BA, Holliday RA. Levator scapulae muscle asymmetry presenting as a palpable neck mass: CT evaluation. *AJNR Am J Neuroradiol* 1993;14:461-4.
11. Qureshi SS, Chaukar DA, Dacruz AK. A useful technique of reinforcing mucosal sutures after segmental man-dibulectomy with primary closure using levator scapulae muscle. *J Surg Oncol* 2005;89:34-5.