

CASE REPORT OLGU SUNUMU

DOI: 10.5336/dentalsci.2025-108216

# Root Canal Treatment and Endocrown Application of Molar Tooth with Excessive Substance Loss

## Aşırı Madde Kaybı Olan Molar Dişin Kök Kanal Tedavisi ve Endokron Uygulaması

İpek ERASLAN AKYÜZ<sup>a</sup>

<sup>a</sup>Erciyes University Faculty of Dentistry, Department of Endodontics, Kayseri, Türkiye

**ABSTRACT** Rehabilitation of endodontically treated teeth with excessive coronal material loss always poses a challenge for clinicians. The type of restorative materials used and an appropriate restoration that preserves tooth structure are factors that affect the longevity of endodontic treatment. Endocrowns have emerged as a practical and cost-effective technique for restoring severely damaged teeth. The use of endocrowns has further increased with the development of computer-aided design/computer-aided manufacturing technology, which allows the rapid and effective production of precision restorations. Laboratory-fabricated indirect porcelain or composite resin endocrowns rehabilitate mechanical and biological function while providing optimum aesthetics with minimal tooth preparation. This case report discusses the endodontic treatment, endocrown restoration, and rehabilitation of tooth number 46.

**Keywords:** Dental materials; dental caries; root canal treatment

**ÖZET** Aşırı koronal madde kaybı bulunan endodontik tedavi dişlerin rehabilitasyonu her zaman klinisyenler için bir zorluk oluşturmaktadır. Kullanılan restoratif materyallerin türü ve diş yapısını koruyan uygun bir restorasyon, endodontik tedavinin ömrünü etkileyen faktörlerdir. Endokronlar, ciddi şekilde hasar görmüş dişleri restore etmek için pratik ve uygun maliyetli bir teknik olarak ortaya çıkmıştır. Endokronların kullanımı, hassas restorasyonların hızlı ve etkili bir şekilde üretilmesine olanak tanıyan bilgisayar destekli tasarım/bilgisayar destekli üretim teknolojisinin gelişmesiyle daha da artmıştır. Laboratuvarda üretilen indirekt porselen veya kompozit rezin endokronlar, minimum diş preparasyonu ile optimum estetik sağlarken mekanik ve biyolojik işlevi rehabilite eder. Bu olgu sunumunda 46 numaralı dişin endodontik tedavisi ve endokron restorasyonu ile rehabilitasyonu ele alınmıştır.

**Anahtar Kelimeler:** Dental materyaller; diş çürüğü; kök kanal tedavisi

The primary factor contributing to the reduction in hardness and fracture resistance of teeth subjected to root canal treatment is the loss of structural integrity resulting from caries, traumatic forces, and cavity preparation, rather than dehydration or physical alterations in the dentin.<sup>1</sup> The type of restorative materials and an appropriate restoration that preserves the tooth structure affect the survival time of the tooth.<sup>2</sup> The quality and integrity of the remaining

tooth structure must be carefully preserved to provide a solid foundation for the restoration and increase the restored tooth's structural strength.<sup>3</sup> In cases where crown damage is excessive, the interproximal space is limited, and traditional rehabilitation with a post and crown is not possible due to insufficient ceramic thickness, endocrown restorations are performed as an alternative treatment method. Thanks to these restorations, macromechanical adhesion is achieved

**TO CITE THIS ARTICLE:**

Eraslan Akyüz İ. Root canal treatment and endocrown application of molar tooth with excessive substance loss. Türkiye Klinikleri J Dental Sci. 2025;31(3):475-80.

**Correspondence:** İpek ERASLAN AKYÜZ

Erciyes University Faculty of Dentistry, Department of Endodontics, Kayseri, Türkiye

**E-mail:** ipekemamak@hotmail.com

Peer review under responsibility of Türkiye Klinikleri Journal of Dental Sciences.

**Received:** 07 Jan 2025

**Received in revised form:** 05 Mar 2025

**Accepted:** 14 Mar 2025

**Available online:** 30 May 2025

2146-8966 / Copyright © 2025 by Türkiye Klinikleri. This is an open access article under the CC BY-NC-ND license (<http://creativecommons.org/licenses/by-nc-nd/4.0/>).



by adhesion to the inner surface of the pulp chamber and pulp walls, and micromechanical adhesion is achieved by using adhesive cement.<sup>1</sup> This technique is easy to apply, requires less clinical time than traditional crowns, is less costly because it involves fewer steps, is produced quickly, and is aesthetic.<sup>4</sup>

In an *in vitro* study assessing the fracture resistance of molars restored with mesio-occluso-distal (MOD) composite resin restorations or ceramic inlays, it was found that teeth restored with computer-aided design (CAD)/computer-aided manufacturing (CAM) ceramic restorations exhibited fracture strengths similar to those of unrestored, healthy teeth.<sup>5</sup> Furthermore, the use of CAD/CAM technology aligns with conservative, modern preparation designs and enables the fabrication of indirect restorations in a single visit.<sup>6</sup>

A growing variety of resin-ceramic materials, consisting of polymer and ceramic combinations for dental restorations, has recently become accessible. However, compared to other nanoceramic materials, Cerasmart (GC Corp., Tokyo, Japan) exhibits less opposing tooth wear.<sup>7</sup>

In this case report, root canal treatment and superstructure restoration (with endocrown-Cerasmart) of the necrotic mandibular molar tooth are described.

## CASE REPORT

A 19-year-old female patient visited Erciyes University Faculty of Dentistry Endodontics Clinic with spontaneous pain in tooth 46<sup>th</sup> clinical and radiological examination revealed previous composite restorations and secondary caries. The tooth did not show

any pain on percussion and palpation and responded negatively to both the electric pulp test (Parkell) and the cold test. Root canal treatment and an endocrown restoration were planned, with informed consent obtained. Initial intraoral photographs and radiographs were taken (Figure 1).

Local anesthesia was administered using 4% articaine with 1:100,000 epinephrine (Ultracaine® D-S, Sanofi-Aventis, Frankfurt, Germany) to ensure adequate pain control during the procedure. After removing decay on the mesial side of tooth 47, the cavity was etched with 37% phosphoric acid, followed by the application of an adhesive bonding system (3M ESPE, St. Paul, MN, USA). A sectional matrix system was used to ensure proper contour and contact, and the cavity was subsequently restored with a nanohybrid composite resin (3M ESPE) using an incremental layering technique. In the same session, before root canal treatment, the buccal and lingual cusps of tooth 46 were reduced, and a MOD cavity was prepared. Pre-endodontic composite build-up (3M ESPE) was completed for proper rubber dam isolation, which included adjacent teeth (Figure 2). Following the pre-endodontic composite build-up, rubber dam isolation was applied before initiating the root canal treatment to ensure a dry and contamination-free operative field.

## ROOT CANAL TREATMENT

The distal and mesial root canals' working length was measured using the M0 mode of the Ai-endodontic motor (Woodpecker, China) with K-type files No. 10 and 15 (Dentsply Sirona, Türkiye). Mesiobuccal, mesiolingual, and distal canals were prepared with

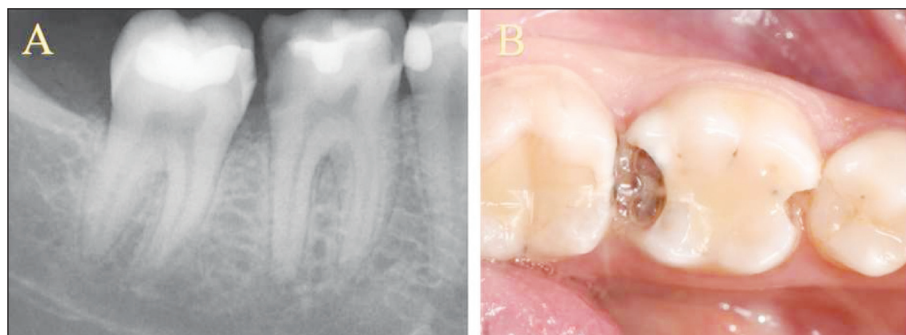


FIGURE 1: Initial radiography (A) and photograph (B)

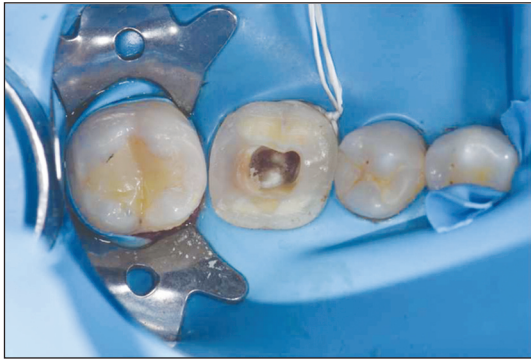

FIGURE 2: Isolation with rubberdam

OneCurve (25/0.6) files (Coltene Micro Mège, France). After each file change, canals were irrigated with 2.5% NaOCl. Following instrumentation, a final irrigation protocol was applied, consisting of 2.5% NaOCl, 17% EDTA (1 min), and saline as the final irrigation solution. Irrigation agitation was performed using the Ultra X ultrasonic device (Sifary Medical, China) in three cycles of 20 seconds each, with 2 mL of irrigant per cycle. After agitation, canals were dried with paper points. Mesio Buccal and mesio lingual canals were filled using the single-cone technique with AH Plus sealer (Dentsply

Sirona, Türkiye), while the distal canal was filled with the lateral condensation technique using the same sealer. The canal orifices and pulp chamber were sealed with a flowable composite resin (3M ESPE, St. Paul, MN, USA) to ensure an adequate seal and prevent microleakage.

#### CAVITY PREPARATION AND ENDOCROWN RESTORATION

An occlusal reduction of over 2 mm was performed, maintaining a cervical margin width of at least 2 mm and a pulp chamber depth of 3 mm. The prepared tooth, adjacent, and opposing teeth were scanned with a Cerec Primescan (Sirona Dental, Germany) to ensure proper closure and ideal restoration height (Figure 3A). The contact relationship of the designed restoration with adjacent teeth was then evaluated (Figure 3B).

The endocrown block, made from Cerasmart (A2) nano-hybrid ceramic (GC, Tokyo, Japan) using the CEREC Primemill (Sirona Dental, Germany), was fitted to tooth 46. The inner surface's fit with the pulp chamber and the outer surface's contact with adjacent teeth were evaluated (Figure 4).

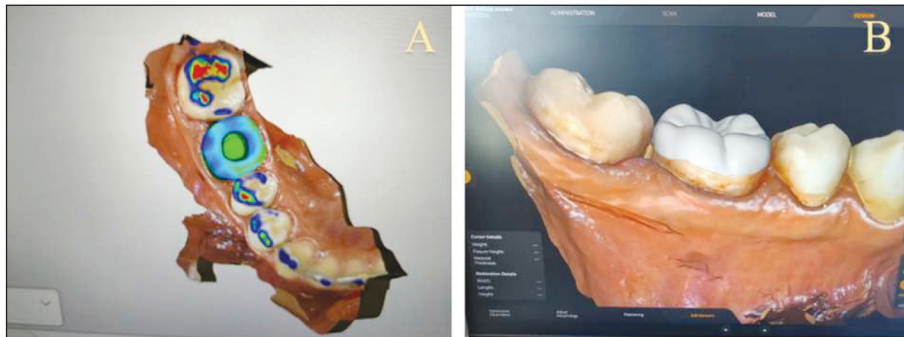


FIGURE 3: Analysis of restoration height (A), evaluation of contact relationship with adjacent. teeth (B)

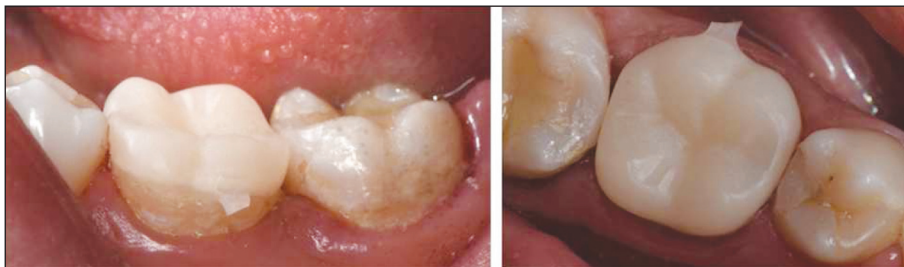

FIGURE 4: Evaluation of the contact relationship with adjacent teeth

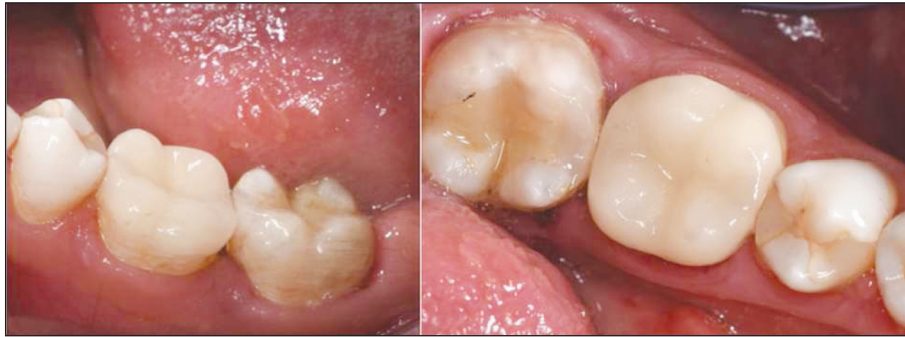

FIGURE 5: Final photographs

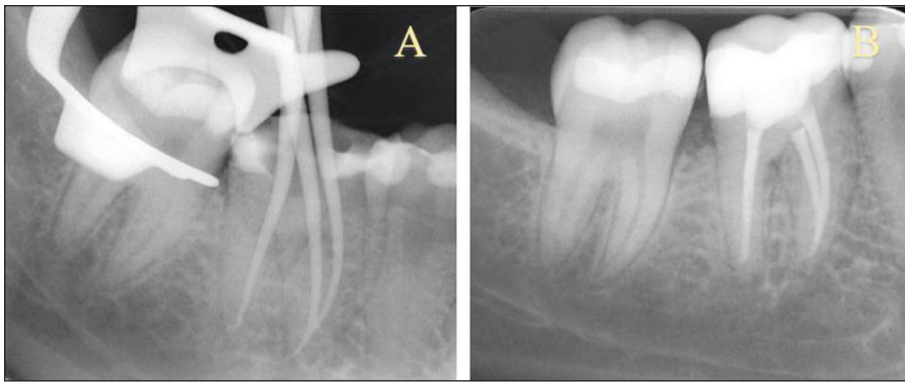


FIGURE 6: Master cone radiography (A), final radiography (B)

## CEMENTATION

After rubber dam isolation, adjacent teeth were covered with Teflon. The endocrown's inner surface was sandblasted for 15 seconds, air-dried, and coated with silane (Ultradent Products). The cavity and cervical margin were etched with 37% phosphoric acid (Imicryl Dental), rinsed, and dried. All procedures were completed in the same session, with no need for temporary sealing between steps. Bond (3M ESPE, St. Paul, MN, USA) was applied and air-dried, and self-adhesive resin cement (RelyX U200, 3M ESPE, Seefeld, Germany) was applied to the pulp chamber and block. Following a 2-second initial polymerization with an LED light-curing device (Woodpecker, China), excess cement was removed, and a final 40-second light cure was applied to all margins using the same device. Contact and occlusal height were verified, and final photographs were taken (Figure 5). In addition, the master cone in Figure 6A and the final

radiograph of tooth number 46 in Figure 6B are also shown.

Master cone radiography in Figure 6A and the final radiograph of tooth number 46 in Figure 6B are also shown.

## DISCUSSION

Endocrowns are monoblock restorations integrating the intraradicular post, core, and crown.<sup>8</sup> These restorations have demonstrated considerable potential as an effective solution for molars and premolars with significant loss of coronal structure.<sup>9</sup> The enamel and dentin tissue lost during full crown construction can be replaced by minimally invasive techniques in endocrown construction, preserving the remaining tooth structure. Additionally, it can receive support from the pulp chamber cavity without the need for additional preparation in the root canals, thus in-

creasing the stability and retention of the restoration.<sup>10</sup>

This case report describes the construction of an endocrown restoration, a more up-to-date approach, instead of a full crown restoration for a patient with excessive material loss in the mandibular molar tooth. Timely restoration of endodontically treated teeth significantly impacts their prognosis. Pratt et al. found that teeth restored with crowns within four months of root canal treatment were nearly 3 times less likely to be extracted than those restored later.<sup>11</sup>

Endocrowns offer a simpler, more cost-effective alternative to conventional post-and-core restorations, with improved aesthetics and reduced procedure time. Their adhesive technique minimizes marginal leakage and microbial penetration, enhancing the success of endodontic treatment.<sup>12</sup> Studies highlight their lower incidence of catastrophic failures, superior stress distribution, and increased fracture resistance compared to conventional crowns.<sup>13</sup> Moreover, as intracanal retention can weaken teeth and complicate re-treatment, endocrowns align with the principles of conservative restorative dentistry, preserving dental tissue and reducing the risks associated with posts.<sup>14</sup>

Hybrid ceramics, such as Cerasmart, offer significant advantages in endocrown restorations by providing an elastic modulus similar to dentin, which aids in stress absorption and reduces stress concentrations at the restoration interface.<sup>15</sup> This property enhances the biomechanical performance of endocrowns, contributing to their durability and clinical success. However, further long-term clinical studies are needed to comprehensively evaluate the longevity and failure modes of hybrid ceramic endocrowns, particularly in comparison to traditional ceramic materials like lithium disilicate. Additionally, while en-

docrowns are predominantly used for molars, expanding research into their applicability for premolars and anterior teeth is essential to determine their feasibility, functional performance, and aesthetic outcomes in different clinical scenarios.

There is a growing need for more evidence-based studies regarding fractures of endodontically treated teeth. While endocrowns show promise in restoring teeth with significant coronal structure loss, it is essential to consider the potential for fractures in these teeth, especially when subjected to long-term functional stress. Further studies exploring the fracture resistance of teeth restored with endocrowns compared to conventional crowns, particularly in different clinical situations and tooth types, would provide valuable insights into their performance and long-term durability. Additionally, understanding the specific failure modes and factors contributing to fracture in endodontically treated teeth will help refine the indications and techniques for using endocrowns, improving their success and longevity in clinical practice.

#### **Source of Finance**

*During this study, no financial or spiritual support was received neither from any pharmaceutical company that has a direct connection with the research subject, nor from a company that provides or produces medical instruments and materials which may negatively affect the evaluation process of this study.*

#### **Conflict of Interest**

*No conflicts of interest between the authors and / or family members of the scientific and medical committee members or members of the potential conflicts of interest, counseling, expertise, working conditions, share holding and similar situations in any firm.*

#### **Authorship Contributions**

*This study is entirely author's own work and no other author contribution.*

## REFERENCES

1. Chang CY, Kuo JS, Lin YS, Chang YH. Fracture resistance and failure modes of CEREC endo-crowns and conventional post and core-supported CEREC crowns. *J Dent Sci.* 2009;4(3):110-7. [\[Link\]](#)
2. Ferrari M, Vichi A, Mannocci F, Mason PN. Retrospective study of the clinical performance of fiber posts. *Am J Dent.* 2000;13(Spec No):9B-13B. [\[PubMed\]](#)
3. Assif D, Nissan J, Gafni Y, Gordon M. Assessment of the resistance to fracture of endodontically treated molars restored with amalgam. *J Prosthet Dent.* 2003;89(5):462-5. [\[PubMed\]](#)
4. Dietschi D, Duc O, Krejci I, Sadan A. Biomechanical considerations for the restoration of endodontically treated teeth: a systematic review of the literature, Part II (evaluation of fatigue behavior, interfaces, and in vivo studies). *Quintessence Int.* 2008;39(2):117-29. [\[PubMed\]](#)
5. Bremer BD, Geurtsen W. Molar fracture resistance after adhesive restoration with ceramic inlays or resin-based composites. *Am J Dent.* 2001;14(4):216-20. [\[PubMed\]](#)
6. Jedynakiewicz NM, Martin N. CEREC: science, research, and clinical application. *Compend Contin Educ Dent.* 2001;22(6 Suppl):7-13. [\[PubMed\]](#)
7. Laborie M, Naveau A, Menard A. CAD-CAM resin-ceramic material wear: a systematic review. *J Prosthet Dent.* 2024;131(5):812-8. [\[PubMed\]](#)
8. Sedrez-Porto JA, Rosa WL, da Silva AF, Münchow EA, Pereira-Cenci T. Endocrown restorations: a systematic review and meta-analysis. *J Dent.* 2016;52:8-14. [\[PubMed\]](#)
9. Govare N, Contrepois M. Endocrowns: a systematic review. *J Prosthet Dent.* 2020;123(3):411-418.e9. [\[Crossref\]](#) [\[PubMed\]](#)
10. Magne P, Carvalho AO, Bruzi G, Anderson RE, Maia HP, Giannini M. Influence of no-ferrule and no-post buildup design on the fatigue resistance of endodontically treated molars restored with resin nanoceramic CAD/CAM crowns. *Oper Dent.* 2014;39(6):595-602. [\[Crossref\]](#) [\[PubMed\]](#)
11. Pratt I, Aminoshariae A, Montagnese TA, Williams KA, Khalighinejad N, Mickel A. Eight-year retrospective study of the critical time lapse between root canal completion and crown placement: its influence on the survival of endodontically treated teeth. *J Endod.* 2016;42(11):1598-603. [\[PubMed\]](#)
12. El Elagra M. Endocrown preparation. *Int J Appl Dent Sci.* 2019;5(1):253-6. [\[Link\]](#)
13. Sevimli G, Cengiz S, Oruc MS. Endocrowns: review. *J Istanbul Univ Fac Dent.* 2015;49(2):57-63. [\[PubMed\]](#) [\[PMC\]](#)
14. Papalexopoulos D, Samartzi TK, Sarafianou A. A thorough analysis of the endocrown restoration: a literature review. *J Contemp Dent Pract.* 2021;22(4):422-6. [\[PubMed\]](#)
15. Gresnigt MM, Özcan M, van den Houten ML, Schipper L, Cune MS. Fracture strength, failure type and Weibull characteristics of lithium disilicate and multiphase resin composite endocrowns under axial and lateral forces. *Dent Mater.* 2016;32(5):607-14. [\[PubMed\]](#)