

# Giant Fibroepithelial Polyp of Vulva: Scientific Letter

## Vulvada Dev Fibroepitelyal Polip

Payam AHMEDMAULID,<sup>a</sup>  
Özgür S. KOTAN,<sup>b</sup>  
Zeynep ELMALİ<sup>c</sup>

Clinics of

<sup>a</sup>Pathology,

<sup>b</sup>Dermatology and Venereology,  
Gümüşhane State Hospital,

<sup>c</sup>Clinic of Gynecology and Obstetrics,  
Kelkit State Hospital,  
Gümüşhane

Geliş Tarihi/Received: 22.10.2015

Kabul Tarihi/Accepted: 20.01.2016

Yazışma Adresi/Correspondence:

Özgür S. KOTAN

Gümüşhane State Hospital,

Clinic of Dermatology and Venereology,

Gümüşhane,

TÜRKİYE/TURKEY

drokotan@hotmail.com

**ABSTRACT** Fibroepithelial polyp (FEP) is a flesh-colored pedunculated skin tag which has a predilection for axilla, neck, groin, eyelids and beneath breasts. This benign mesenchymal skin lesion is relatively uncommon in female genital tract. When observed in the female genital tract, it usually presents in vagina. Large vulvar cases are very rare. We present a 39 year old female patient who presented to the dermatology outpatient clinic with a slowly and continuously growing vulvar swelling. Physical examination revealed a pedunculated mass on the surface of right labium majoris which had a diameter of approximately 6 cm. The patient did not have any polypoid skin lesions at any other body region. She was referred to the gynaecology outpatient clinic. The mass was excised under general anesthesia and histopathologic examination was performed yielding the diagnosis of FEP. We present this rare case with its uncommon size and location with review of the literature.

**Key Words:** Neoplasms, fibroepithelial; vulva

**ÖZET** Fibroepitelyal polip (FEP), aksilla, boyun, bacak arası, gözkapağı ve memelerin alt kısmında görülme eğiliminde olan, ten renginde, pedüncüle bir deri ekidir. Bu benign, mezenkimal deri lezyonu, kadın genital traktında göreceli olarak seyrek gözlenir. Kadın genital traktında izlendiğinde, genellikle vajinada bulunur. Büyük boyutlu vulvar olgular çok nadirdir. Dermatoloji polikliniğine vulvada yavaş ve sürekli büyüyen şişlik ile başvuran 39 yaşında bir kadın hastayı sunmaktayız. Fizik muayenede sağ labium majoris yüzeyinde yerleşmiş, yaklaşık 6 cm çapında bir pedüncüle kitle izlendi. Hastanın vücudunda başka bir polipoid deri lezyonu izlenmedi. Hasta, jinekoloji polikliniğine yönlendirildi. Genel anestezi altında eksize edilen kitle, histopatolojik inceleme sonucunda FEP tanısını aldı. Sık görülmeyen boyut ve yerleşim yeri ile nadir olan bu olguyu literatür incelemesi ile birlikte sunmaktayız.

**Anahtar Kelimeler:** Neoplaziler, fibroepitelyal; vulva

**Türkiye Klinikleri J Dermatol 2016;26(3):148-51**

**M**esenchymal tumours of the vulvovaginal region range from benign to locally aggressive and malignant tumors. Benign tumors of the vulva are relatively uncommon, constituting a large spectrum of tumors such as angiofibroma, angiomyofibroblastoma, lymphangioma and schwannoma.<sup>1-3</sup> Fibroepithelial polyp (acrochordon, fibrolipoma, soft fibroma) is a benign neoplastic/hamartomatous polypoid mass of vulva.<sup>4</sup> Although it is a common cutaneous lesion which has a propensity for axilla, neck, groin, eyelids and chest, is relatively uncommon in female genital tract.<sup>4-6</sup> When seen in the female genital tract, it is usually seen in vagina.

doi: 10.5336/dermato.2015-48340

Copyright © 2016 by Türkiye Klinikleri

Vaginal FEPs are mostly associated with external hormone usage and pregnancy. Vulva is an uncommon location for FEP. It usually arises on hair bearing skin of labium majus.<sup>4</sup> The origin of a vulvar FEP is most probably a regressing nevus.<sup>4</sup> Small FEPs may resemble nevi while large lesions may present cosmetic problems. Large FEP of vulva is a very rare entity.<sup>7,8</sup>

There are three clinical types of FEPs: furrowed papules approximately 2 mm in width and height; filiform lesions, approximately 2 mm in width and 5 mm in height; and large bag-like protuberances. The term “acrochordon” is used for the smaller lesions whereas FEP is generally used for the latter.<sup>5</sup>

On cut section FEPs are soft and fleshy. The histological features vary with the clinical type. The larger, bag-like lesions are covered with stratified squamous epithelium and usually have a stroma composed of loosely arranged collagen with dilated vascular structures and a central core of adipose tissue.<sup>5</sup>

A 39 year old female patient presented to our dermatology outpatient clinic with a complaint of a vulvar mass.

### CLINICAL FINDINGS

Upon examination, she was referred to the gynaecology outpatient clinic. The patient admitted that she first noticed a bump on her vulva 2 years ago which has been growing gradually. History did not reveal any chronic diseases or previous operations. Physical examination revealed a pedunculated mass on her right labium majoris which has a diameter of approximately 6 cm (Figure 1). There was no tenderness or pain on palpation of the mass area. The patient did not have any accompanying polypoid mass on skin of any other body region. According to vaginal examination, uterus was in normal size and adnexes were non-palpable, bilaterally. Ultrasonography did not reveal any abnormalities in the internal genital tract. The patient had a high Body Mass Index (BMI) of 35.5 which indicated her to be categorised as obese. Complete blood count and biochemical analysis were in nor-

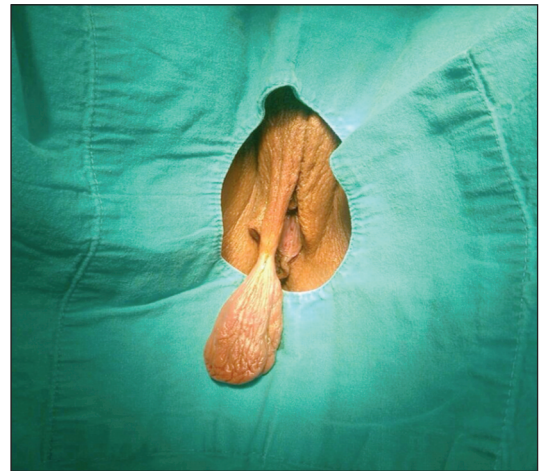


FIGURE 1: A flesh colored, large pedunculated mass on right labium majus.

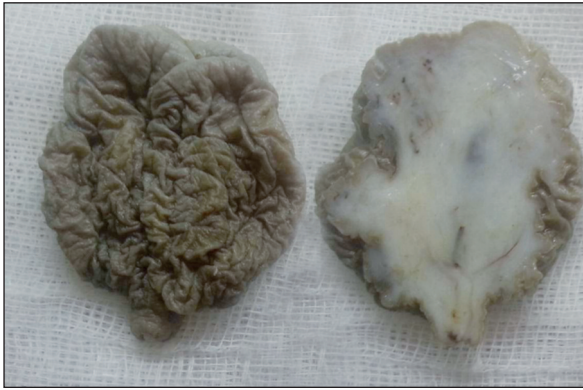mal range. Due to cosmetic reasons, the mass was excised under general anesthesia. The patient was discharged and the one-month gynecology outpatient clinic follow up was normal, without any post-operative complications.

### PATHOLOGICAL FINDINGS

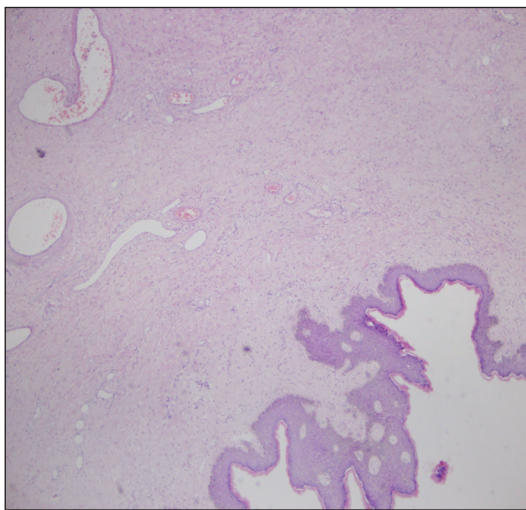
On pathologic macroscopic examination, the excisional skin biopsy revealed a tan colored polypoid mass which had a size of 5.5x4.5x3.5 cm with a pedicule of 8 mm length and 4 mm width. The cut surface was soft and fleshy, white in color with focal millimetric dark red areas (Figure 2). Histopathologic examination revealed a lesion layered with stratified squamous epithelium with loose, edematous and slightly fibrous stroma, which had dilated vascular formations and sparse fibroblast-like cells dispersed throughout. Scattered fat tissue was observed at the center of the stroma. There was no significant mitotic activity, cellular atypia or necrosis (Figures 3, 4). According to these histopathologic findings, the lesion had the diagnosis of a FEP.

### LITERATURE REVIEW

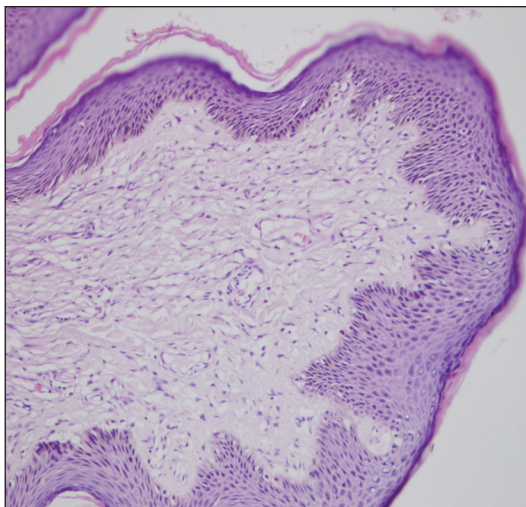
Acrochordon (fibroepithelial polyp, fibrolipoma, soft fibroma) is a common benign cutaneous lesion which has a predilection for axilla, neck, groin, eyelids and beneath breasts. There are three clinical types of acrochordons: furrowed papules ap-



**FIGURE 2:** A polypoid mass with a size of 5.5x4.5x3.5 cm. The cut surface was soft and fleshy, white in color with focal millimetric dark red areas.



**FIGURE 3:** Lesion layered with stratified squamous epithelium with dilated vascular formations (HE, x100).



**FIGURE 4:** Lesion with loose, edematous and slightly fibrous stroma (HE, x400).

proximately 2 mm in width and height; filiform lesions, approximately 2 mm in width and 5 mm in height; and large bag-like protuberances. The term “fibroepithelial polyp” (FEP) is generally used for the latter.<sup>5</sup>

FEPs are relatively uncommon in female genital tract. Although they are rare in female genital tract, they appear more common in vagina than in vulva where they occur rarely as observed in our case.<sup>4</sup> FEPs are benign tumours of the vulvar skin which have various stromal and epithelial component.<sup>9</sup> FEPs of the female genital tract are typically seen in women of reproductive age. They present as polypoid and exophytic masses.<sup>9</sup> FEPs rarely exceed 1-2 cm. There are a few reported cases of large fibroepithelial stromal polyps of the vulva, as seen in our case.<sup>7,8,10</sup>

FEPs of the vulva are thought to arise from a regressing nevus. Frequent irritation seems to be another important etiologic factor of these skin tags, especially in obese patients, as our patient. According to another opinion, FEPs raise on the aging skin, with many factors responsible for their development.<sup>4</sup> There are several studies which reveal that the vaginal FEPs are associated with external hormone usage and pregnancy. Larger vaginal lesions are observed to arise from the proliferation of mesenchymal cells within the hormonally sensitive subepithelial stromal layer of the lower genital tract. Hence, hormonal imbalances (e.g, high levels of estrogen and progesterone during pregnancy and external hormone usage) may facilitate the development of FEPs.<sup>4,8</sup> Our patient did not have a history of external hormone usage.

Obesity has been stated to propose a risk factor for the development of skin tags. Also in several studies FEPs have been stated to be an indicator of impaired glucose metabolism and diabetes mellitus type II.<sup>11</sup> Our patient was also obese with a BMI of 35 but she did not have a known history of diabetes.

FEPs don't cause any symptoms such as pain unless inflamed or irritated.<sup>12</sup> The larger FEPs may create cosmetic and mechanical problems. A large

lesion between the legs may result in discomfort. Excision is the curative treatment for symptomatic FEPs.<sup>13</sup>

FEPs of the vulvovaginal region are benign lesions. Occasionally, they may exhibit pseudosarcomatous features including hypercellularity, cytologic atypia and increased mitotic rate. Although these histopathologic features are worrisome, these lesions are still benign.<sup>4</sup> Although some of such described cases showed recurrence, none of the lesions that recurred had poor prognosis. There was no evidence of metastasis in any of the patients.<sup>13</sup>

When hypocellular like in our case, FEPs are easily recognized by histopathological interpretation. However FEPs with atypical mitoses or hypercellularity may create a suspicion of malignancy. Such cases might be misdiagnosed as malignancy and this may lead to overtreatment.<sup>13</sup>

Although fibroepithelial polyps are benign, a few of the cases in the literature recurred. Incomplete excision, pregnancy or multifocality have been stated as factors which are in relationship with recurrence.<sup>8,9</sup>

Histopathological examination is necessary to exclude malignant lesions such as aggressive angiomyxoma, angiofibroma and sarcoma as these rare malignant tumors of female genital tract also present as pedunculated polypous masses.<sup>9,14,15</sup>

We report this rare case of giant acrochordon (FEP) of labium majus and performed a review of the literature in order to highlight the important points such as diagnostic pitfalls that might arise in, and to accentuate the importance of histopathologic evaluation of this rare vulvar entity.

## REFERENCES

- Fletcher CDM. Fibroblastic-myo-fibroblastic tumors. In: Fletcher CDM, Unni KK, Mertens F, eds. WHO Pathology and Genetics of Soft Tissue and Bone. 1<sup>st</sup> ed. Lyon: IARC Press; 2002. p.73-4.
- Erdoğan AG, Balaban D, Koç K. [Circumscribed vulvar lenfangioma: case report]. *Turkderm* 2005;39(1):54-5.
- Yamashita Y, Yamada T, Ueki K, Ueki M, Sugimoto O. A case of vulvar schwannoma. *J Obstet Gynaecol Res* 1996;22(1):31-4.
- Wilkinson EJ, Xie D-L. Benign diseases of the vulva. In: Kurman RJ, ed. Blaustein's Pathology of Female Genital Tract. 5<sup>th</sup> ed. New York: Springer; 2002. p.74-5.
- Elder DE, Elenitsas R, Johnson BL, Ioffreda MD, Miller J, Miller OF. Fibroepithelial polyp. *Atlas and Synopsis of Lever's Histopathology of the Skin*. 2<sup>nd</sup> ed. Philadelphia: Lippincott Williams & Wilkins; 2007. p.65-6.
- Uçar MG, Şanlıkan F. Giant fibroepithelial polyp of vulva, a case report and brief review of literature. *Türkiye Klinikleri J Gynecol Obs* 2015;25(4):268-70.
- Chan MM, Yong TT, Sittampalam K. Giant labial fibroepithelial stromal polyp. *Malays J Pathol* 2013;35(1):91-4.
- Carter J, Elliott P, Russell P. Bilateral fibroepithelial polyp of labium minus with atypical stromal cells. *Pathology* 1992;24(1):37-9.
- Ostör AG, Fortune DW, Riley CB. Fibroepithelial polyps with atypical stromal cells (pseudosarcoma botryoides) of vulva and vagina. A report of 13 cases. *Int J Gynecol Pathol* 1988;7(4):351-60.
- Madueke-Laveaux OS, Gogoi R, Stoner G. Giant fibroepithelial stromal polyp of the vulva: largest case reported. *Ann Surg Innov Res* 2013;7:8.
- Bhargava P, Mathur D, Mathur DK, Malpani S, Goel S, Agarwal US, et al. Acrochordon, diabetes and associations. *Indian J Dermal Venereal Leprol* 1996;62(4):226-8.
- Menn JJ, Boberg J. Fibroepithelial polyps. An unusual case report. *J Am Podiatr Med Assoc* 1990;80(9):496-8.
- Song JS, Song DE, Kim KR, Ro JY. Cellular pseudosarcomatous fibroepithelial stromal polyp of the vagina during pregnancy: a lesion that is overdiagnosed as a malignant tumor. *Korean J Pathol* 2012;46(5):494-8.
- Laskin W, Fetsch J, Tavassoli F. Superficial cervicovaginal myofibroblastoma: fourteen cases of a distinctive mesenchymal tumour arising from the specialized subepithelial stroma of the lower female genital tract. *Hum Pathol* 2001;32(7):715-25.
- Vijaya C, Shetty A, Kumar SA, Lekha MB. Pedunculated vulval aggressive angiomyxoma: a diagnosis often overlooked. *JEMDS* 2014;3(4):815-9.