

34-Year-Old Male with Hashimoto's Thyroiditis and Primary Thyroid Lymphoma: Case Report

Hashimoto Tiroiditi ile Birlikte Primer Tiroid Lenfoması Olan 34 Yaşında Erkek Hasta

Birsen ÜNSAL KOYUNCU,^a
Hasan ALTUNBAŞ,^a
Elif İNANÇ GÜRER,^b
Ümit KARAYALÇIN^a

^aDivision of Endocrinology and Metabolism,

^bDepartment of Pathology, Akdeniz University Faculty of Medicine, Antalya

Geliş Tarihi/Received: 03.01.2012
Kabul Tarihi/Accepted: 22.04.2012

Yazışma Adresi/Correspondence:

Hasan ALTUNBAŞ
Akdeniz University Faculty of Medicine,
Division of Endocrinology and Metabolism, Antalya,
TÜRKİYE/TURKEY
haltunbas@akdeniz.edu.tr

ABSTRACT Primary thyroid lymphomas constitute only 3% of non-Hodgkin Lymphomas (NHLs) and 5% of all thyroid neoplasms. Thyroid lymphoma is seen more frequently in women; the mean and median ages are 65 and 75 years, respectively. It is highly curable without surgery. We report a 34-year-old man with primary thyroid lymphoma arising from Hashimoto's thyroiditis. The patient was admitted to the hospital for a growing mass on the left side of his neck within 2 months. MRI showed a 3 cm diameter, contrast-enhancing solid nodule at the left lobe adjacent to isthmus and bilateral cervical lymph nodes. The patient was referred to our hospital. A fine-needle aspiration biopsy (FNAB) showed a large number of atypical lymphocytes with necrosis. FNAB was suspicious for malignancy, and total thyroidectomy and left lateral neck dissection were applied. Pathology was reported as primary thyroid lymphoma. Surgery was followed by chemotherapy including rituximab, cyclophosphamide, doxorubicin, vincristine, and prednisolone. No relapse has been detected during next 15-months follow-up. This is very rare occurrence of primary non-Hodgkin's thyroid lymphoma arising from Hashimoto's thyroiditis in a young man.

Key Words: Thyroiditis, autoimmune; lymphoma, B-cell

ÖZET Primer tiroid lenfoması- non-Hodgkin Lenfomaların (NHL) %3'ünü ve tüm tiroid kanserlerinin yaklaşık %5'ini oluşturmaktadır. Kadınlarda tiroid lenfoması daha sık görülür, ortalama ve medyan yaş sırasıyla 65 ile 75' dir. Cerrahi tedavi yapmadan kür oranı yüksektir. Burada Hashimoto tiroiditi zemininde tiroid lenfoması gelişen 34 yaşındaki erkek hastayı sunduk. Hasta, hastaneye 2 ay içerisinde boynunun sol tarafında büyüyen kitle nedeniyle başvurmuş. Manyetik Rezonans görüntüleme ile istmusa komşu sol lobda 3 cm heterojen yoğun kontrast tutan solid nodül ve bilateral servikal lenf nodları tespit edilmiş. Hasta bu bulgularla hastanemize başvurdu. İnce iğne aspirasyon biyopsisi (İİAB)'nde nekroz taşıyan bir zeminde atipik görünümlü lenfosit hücreleri izlendi. İİAB sonucunun malignite şüpheli olması nedeni ile total tiroidektomi ve sol lateral boyun diseksiyonu yapıldı. Patolojisi tiroid lenfoması olarak rapor edildi. Cerrahi sonrası rituksimab, siklofosfamid, doksorubisin, vinkristin ve prednizolon içeren kemoterapi uygulandı. Onbeş aylık takibinde nüks izlenmedi. Hashimoto tiroiditinden kaynaklanan primer non-Hodgkin lenfoma genç erkeklerde nadir rastlanan bir durum olduğu için sunuldu.

Anahtar Kelimeler: Tiroiditler, otoimmün; lenfoma, B-hücreli

Türkiye Klinikleri J Endocrin 2013;8(1):39-42

Thyroid lymphomas constitute only 3% of all non-Hodgkin Lymphomas (NHLs) and approximately 5% of all thyroid neoplasms.¹⁻³ In the literature, the cases were reported in women more frequently.⁴⁻⁷ Median age at diagnosis is 65 to 75.^{7,8} The majority of patients have a history of Hashimoto's thyroiditis. The lymphoma develops after 20-

30 years from the beginning of thyroiditis.⁸ The majority of lymphomas are derived from B lymphocytes. Primary T-cell thyroid lymphomas are extremely rare. Clinical presentation is usually a rapidly growing thyroid mass. This mass grows rapidly which takes 1 to 3 months and it may cause obstructive symptoms such as dysphagia, dyspnea, and hoarseness.⁹

CASE REPORT

Thirty-four-year-old male patient who had a rapidly growing mass on the left side of the neck was admitted to the State Hospital. He had no history of hoarseness, shortness of breath, hypothyroidism, and any drug usage. Neck MRI showed approximately 3 cm intense, heterogeneous, contrast-enhancing solid mass at the left lobe adjacent to the isthmus and bilateral cervical and submandibular 2.5 to 3 cm lymph nodes. Thyroid function tests showed subclinical hypothyroidism [TSH 9.43 mIU/ml (0.27-4.2) and FT4 1.14 ng/dl (0.93-1.7)]. Anti-thyroglobulin antibody level was high 218 IU/ml (0-115). A fine-needle aspiration biopsy (FNAB) was done, and a large number of necrosis and atypical lymphocytes were found. Total thyroidectomy and left lateral neck dissection were applied. The pathology was reported as primary thyroid lymphoma. The patient was referred to us for chemotherapy and further management. FT3 1.25 pg/ml (1.8-4.6), FT4 0.35 ng/dl (0.93-1.7), TSH, 64 mIU/ml (0.27-4.2), anti-thyroglobulin antibody 218 IU/ml (0-115) were found, postoperatively. At histopathological examination of surgical specimens' the mass and lymph nodes, diffuse large cell lymphoma and Hashimoto's thyroiditis were reported (Figure 1, 2). Positive immunohistochemical staining of B-cell marker (CD 10, 20) were detected. A L-thyroxine therapy was started (100 µg/day). At the postoperative period, positron emission tomography (PET) showed a weak FDG uptake at thyroid area probably due to postoperative inflammation, and paratracheal, right axillary lymph nodes. In this state, rituximab, cyclophosphamide, doxorubicin, vincristine and prednisone chemotherapy were given to the patient totally eight cycles of chemotherapy was applied. After

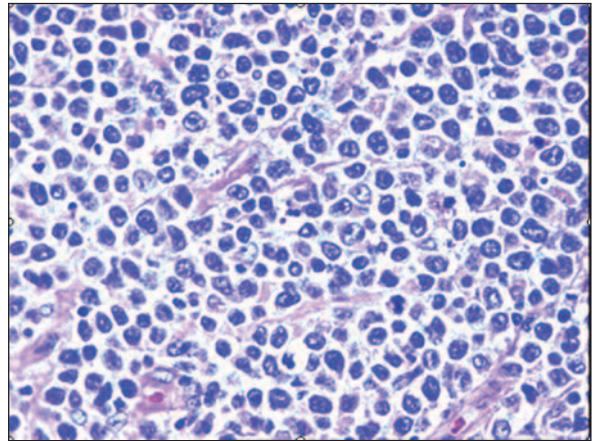


FIGURE 1: Diffuse large cell lymphoma (H&E×200).

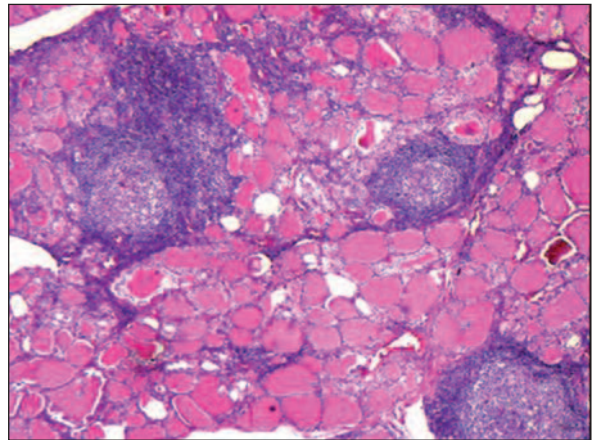


FIGURE 2: Thyroid, Hashimoto thyroiditis, lymphoid follicles with germinal center, Hurthle cells (H&E×100).

chemotherapy, the patient has been followed without any recurrence for 15 months.

DISCUSSION

Primary thyroid lymphoma is usually seen in patients with advanced age and Hashimoto thyroiditis. Very rare cases were reported under the age of 40.^{1,10} Our case, who is 34-year old man is probably one of the extremely rare cases of thyroid lymphoma and Hashimoto thyroiditis. Most patients suffer from a rapidly growing neck mass; in 30% of patients, dysphagia, stridor, hoarseness and feeling of pressure around the neck were seen.⁹ This mass typically grew rapidly in 1 to 3 months.

Ten percent of patients diagnosed with thyroid lymphoma suffer from fever, night sweats and weight loss. Nine percent of patients are hypothyroid while 10% of them are euthyroid.⁹⁻¹¹ A rapidly growing neck mass was the only complaint in our case and our patient was subclinically hypothyroid.

The vast majority of thyroid lymphomas are derived from B cells and the percentage from 60 to 80 percent of diffuse large B-cell lymphoma are considered to be.^{4,5,7,12} Thyroid lymphomas usually develop after 20-30 years from the beginning of Hashimoto's thyroiditis.⁹ Although the relationship between thyroid lymphoma and Hashimoto's thyroiditis is not understood clearly, Hashimoto thyroiditis is a well-known risk factor for thyroid lymphoma. Risk of thyroid lymphoma in patients with Hashimoto's thyroiditis is 60 times more frequent than non-thyroiditis patients.^{8,13,14} In a study conducted in Japan, the risk of development thyroid lymphoma in patients with chronic lymphocytic thyroiditis is 70-80 times more than normal population.¹⁴ Lymphocytes in Hashimoto's thyroid exposed to chronic antigenic stimulation were claimed to be caused by malignant transformation.¹⁵ Thyroid lymphomas may also occur after iodine supplementation and exposure to ionizing radiation.¹⁶ Although there are no specific and diagnostic laboratory abnormalities for thyroid lymphoma, approximately thirty percent of the patients has high serum IgA, IgM or IgG concentrations.⁸ In our case, there was subclinical hypothyroidism and high anti-thyroglobulin antibodies before the operation. Diffuse large B-cell lymphoma can be usually diagnosed after cytologic examination of material obtained by thyroid biopsy.⁹ An aspiration biopsy by a thick needle instead of fine needle was

suggested to obtain enough material by some authors.¹⁷ Given the frequent association with Hashimoto's thyroiditis, cytological diagnosis of small cell lymphomas are more difficult and may require immunohistochemical staining or flow cytometry.² Unfavorable prognostic factors of thyroid lymphoma are increased tumor size (≥ 10 cm), advanced stage of disease (\geq stage IE large), the presence of obstructive symptoms, the rapid growth of the tumor and the mediastinal involvement.¹ Five-year survival rate is 80%, 50%, and lower than 36% for stage IE, stage IIE, stage IIIE and IVE, respectively.¹⁸ Treatment plan depends on the histological type of thyroid lymphomas. Thyroid lymphomas are highly sensitive to both radiation and chemotherapy which consist of cyclophosphamide, doxorubicin, vincristine, and prednisone, but, the role of surgery in the treatment of this disease is limited, even in Stage IIE and IIIE lymphomas.^{5,6,12} Surgical resection for thyroid lymphoma is not superior to any chemo- or radiotherapy modality and surgery has some known risks as well.^{19,20}

Finally, primary thyroid lymphoma is seen more frequently in women and elderly which is in contrast to our young male patients. In our case, although our patient has high probability of being evaluated by clinically and cytologically as lymphoma, non-thyroid malignancy has been suspected because of patient's age and sex, and surgery have been performed and the lymphoma was diagnosed. If a patient presents with a rapidly growing mass in the thyroid, primary thyroid lymphoma should also be kept in mind, even among young and male patients, and means of diagnosis lymphoma from preoperative biopsy material should be investigated.

REFERENCES

1. Ansell SM, Grant CS, Habermann TM. Primary thyroid lymphoma. *Semin Oncol* 1999; 26(3):316-23.
2. Austin JR, el-Naggar AK, Goepfert H. Thyroid cancers. II. Medullary, anaplastic, lymphoma, sarcoma, squamous cell. *Otolaryngol Clin North Am* 1996;29(4):611-27.
3. Pasiaka JL. Anaplastic cancer, lymphoma, and metastases of the thyroid gland. *Surg Oncol Clin N Am* 1998;7(4):707-20.
4. Skarsgard ED, Connors JM, Robins RE. A current analysis of primary lymphoma of the thyroid. *Arch Surg* 1991;126(10):1199-203.
5. Junor EJ, Paul J, Reed NS. Primary non-Hodgkin's lymphoma of the thyroid. *Eur J Surg Oncol* 1992;18(4):313-21.
6. Logue JP, Hale RJ, Stewart AL, Duthie MB, Banerjee SS. Primary malignant lymphoma of the thyroid: a clinicopathological analysis. *Int J Radiat Oncol Biol Phys* 1992;22(5):929-33.

7. Wolf BC, Sheahan K, DeCoste D, Variakojis D, Alpern HD, Haselow RE. Immunohistochemical analysis of small cell tumors of the thyroid gland: an Eastern Cooperative Oncology Group study. *Hum Pathol* 1992;23(11):1252-61.
8. Pedersen RK, Pedersen NT. Primary non-Hodgkin's lymphoma of the thyroid gland: a population based study. *Histopathology* 1996;28(1):25-32.
9. Matsuzuka F, Miyauchi A, Katayama S, Narabayashi I, Ikeda H, Kuma K, et al. Clinical aspects of primary thyroid lymphoma: diagnosis and treatment based on our experience of 119 cases. *Thyroid* 1993;3(2):93-9.
10. Derringer GA, Thompson LD, Frommelt RA, Bijwaard KE, Heffess CS, Abbondanzo SL. Malignant lymphoma of the thyroid gland: a clinicopathologic study of 108 cases. *Am J Surg Pathol* 2000;24(5):623-39.
11. Kossev P, Livolsi V. Lymphoid lesions of the thyroid: review in light of the revised European-American lymphoma classification and upcoming World Health Organization classification. *Thyroid* 1999;9(12):1273-80.
12. Tsang RW, Gospodarowicz MK, Sutcliffe SB, Sturgeon JF, Panzarella T, Patterson BJ. Non-Hodgkin's lymphoma of the thyroid gland: prognostic factors and treatment outcome. The Princess Margaret Hospital Lymphoma Group. *Int J Radiat Oncol Biol Phys* 1993;27(3):599-604.
13. Holm LE, Blomgren H, Löwhagen T. Cancer risks in patients with chronic lymphocytic thyroiditis. *N Engl J Med* 1985;312(10):601-4.
14. Hyjek E, Isaacson PG. Primary B cell lymphoma of the thyroid and its relationship to Hashimoto's thyroiditis. *Hum Pathol* 1988;19(11):1315-26.
15. Pasiaka JL. Hashimoto's disease and thyroid lymphoma: role of the surgeon. *World J Surg* 2000;24(8):966-70.
16. Harach HR, Williams ED. Thyroid cancer and thyroiditis in the goitrous region of Salta, Argentina, before and after iodine prophylaxis. *Clin Endocrinol (Oxf)* 1995;43(6):701-6.
17. Burman KD, Ringel MD, Wartofsky L. Unusual types of thyroid neoplasms. *Endocrinol Metab Clin North Am* 1996;25(1):49-68.
18. Widder S, Pasiaka JL. Primary thyroid lymphomas. *Curr Treat Options Oncol* 2004;5(4):307-13.
19. Friedberg MH, Coburn MC, Monchik JM. Role of surgery in stage IE non-Hodgkin's lymphoma of the thyroid. *Surgery* 1994;116(6):1061-6.
20. Alzouebi M, Goepel JR, Horsman JM, Hancock BW. Primary thyroid lymphoma: the 40 year experience of a UK lymphoma treatment centre. *Int J Oncol* 2012;40(6):2075-80.