

ORIGINAL RESEARCH ORJİNAL ARAŞTIRMA

DOI: 10.5336/medsci.2023-100966

# Delayed Lower Trapezius Myocutaneous Flap for Reconstruction of Posterior Scalp Defects: A Retrospective Study

## Posterior Skalp Defektlerinin Rekonstrüksiyonunda Geciktirme Uygulanmış Alt Trapezius Miyokutanöz Flep: Retrospektif Çalışma

<sup>ID</sup> Ayhan Işık ERDAL<sup>a</sup>, <sup>ID</sup> Mert DORUK<sup>a</sup>, <sup>ID</sup> Serhat ŞİBAR<sup>a</sup>

<sup>a</sup>Gazi University Faculty of Medicine, Department of Plastic, Reconstructive and Aesthetic Surgery, Ankara, Türkiye

**ABSTRACT Objective:** The lower trapezius myocutaneous flap is useful for reconstructing posterior scalp defects. It is recommended that the skin island should not extend more than 10 cm below the inferior angle of the scapula. To design a flap that exceeds these limits and extends more caudally without compromising blood supply, we needed to make a modification and decided to apply a surgical delay procedure. In this study, we present our modified lower trapezius myocutaneous flap technique, in which the surgical delay is applied in the first session, and flap transfer is performed in the second session. **Material and Methods:** Patients who had reconstruction of scalp defect with delayed lower trapezius myocutaneous flap between January 2018 and December 2022 were analyzed retrospectively. Seven patients were included in the study. The demographic characteristics of the patients, the characteristics of the defects, the characteristics of the flaps, and the outcomes of the reconstruction were analyzed. **Results:** Of the 7 patients in the study, 5 were men, and 2 were women. The mean age of the patients was 56 years (range: 42-62 years). All defects were full-thickness scalp defects. All patients had uneventful wound healing and defect closure. There were no complications. **Conclusion:** A delayed lower trapezius myocutaneous flap can be used safely in posterior scalp defects close to the vertex.

**Keywords:** Trapezius flap; myocutaneous flap; superficial back muscles; scalp

**ÖZET Amaç:** Alt trapezius miyokutanöz flep, posterior skalp defektlerinin rekonstrüksiyonu için kullanışlı bir seçenektir. Deri adasının skapula inferior köşesinden 10 cm'den daha aşağıya uzanmaması önerilir. Bu sınırlılıkları aşarak ve kan akışını bozmadan kaudale doğru daha fazla uzanabilen bir flep tasarlamak için bir modifikasyona ihtiyaç duyduk ve cerrahi geciktirme prosedürünü uygulamaya karar verdik. Bu çalışmada, ilk seansta cerrahi geciktirmenin uygulandığı, ikinci seansta ise flep transferinin yapıldığı modifiye alt trapezius miyokutanöz flep tekniğimiz sunulmuştur. **Gereç ve Yöntemler:** Ocak 2018 ile Aralık 2022 tarihleri arasında cerrahi geciktirme uygulanmış alt trapezius miyokutanöz flep ile skalp defekti rekonstrüksiyonu yapılan hastalar retrospektif olarak incelendi. Çalışmaya 7 hasta dâhil edildi. Hastaların demografik özellikleri, defektlerin özellikleri, fleplerin özellikleri ve rekonstrüksiyon sonuçları analiz edildi. **Bulgular:** Çalışmaya dâhil edilen 7 hastanın 5'i erkek, 2'si kadındı. Hastaların ortalama yaşı 56 (aralık: 42-62) idi. Tüm defektler tam kat saçlı deri defektleriydi. Tüm hastalarda sorunsuz yara iyileşmesi ve defekt kapatılması gerçekleşti. Komplikasyon olmadı. **Sonuç:** Geciktirme uygulanmış alt trapezius miyokutanöz flep vertexe yakın posterior skalp defektlerinde güvenli kullanılabilir.

**Anahtar Kelimeler:** Trapezius flep; miyokutanöz flep; yüzeysel sırt kasları; saçlı deri

The triangular-shaped trapezius muscle has a wide structure, extending from the occiput to the 12<sup>th</sup> thoracic vertebra. It can be divided into three parts from cranial to caudal: descending (or superior), transverse (or middle), and ascending (or inferior). It is the most superficial muscle on the back. It covers the levator scapulae muscle, the rhomboid minor

muscle and rhomboid major muscle in the upper half of the thorax, and the latissimus dorsi muscle in the lower half of the thorax. The descending part elevates the scapula, the transverse part retracts the scapula, and the ascending part depresses the scapula. When the trapezius muscle is used as a flap, unlike most muscle flaps, the entire muscle is never harvested,

**Correspondence:** Ayhan Işık ERDAL

Gazi University Faculty of Medicine, Department of Plastic, Reconstructive and Aesthetic Surgery, Ankara, Türkiye

**E-mail:** ayhanerdal111@gmail.com



Peer review under responsibility of Türkiye Klinikleri Journal of Medical Sciences.

**Received:** 24 Dec 2023

**Received in revised form:** 25 Mar 2024

**Accepted:** 02 Apr 2024

**Available online:** 24 Apr 2024

2146-9040 / Copyright © 2024 by Türkiye Klinikleri. This is an open access article under the CC BY-NC-ND license (<http://creativecommons.org/licenses/by-nc-nd/4.0/>).

only a certain part is used as a flap. The transverse or ascending part can be used as a pedicled flap in head and neck reconstruction.<sup>1</sup> The upper trapezius myocutaneous flap (transverse part) and the lower trapezius myocutaneous flap (ascending part) were described by different authors at similar times.<sup>2-5</sup> The upper trapezius myocutaneous flap is supplied by the superficial cervical artery (superficial branch of the transverse cervical artery). The lower trapezius myocutaneous flap is supplied by the dorsal scapular artery (deep branch of the transverse cervical artery). The dorsal scapular artery lies deep to the levator scapulae and rhomboids. It always gives a branch to the lower trapezius muscle between the minor and major rhomboid muscles. The terminal branch of the dorsal scapular artery is the descending branch, which courses under the rhomboid major muscle. According to Mathes and Nahai classification, the trapezius muscle has a Type II pattern of circulation (one dominant vascular pedicle plus minor pedicles).<sup>6</sup>

The more caudal the flap is designed, the greater the distance from the pivot point, and the more the arc of rotation; thus, it can cover defects farther cranially. Therefore, the lower trapezius myocutaneous flap is more useful for scalp defects. However, in flaps harvested more caudally to cover more distant scalp defects, marginal necrosis may sometimes develop in the areas furthest from the pedicle. To avoid partial flap necrosis, it is recommended that the skin island should not extend more than 10 cm below the inferior angle of the scapula.<sup>7</sup> Another point to be considered in the design is that at least one-third of the skin island must be on the trapezius muscle.<sup>1</sup> We used the surgical delay to design a lower trapezius myocutaneous flap free from these limitations. Thus, we could design a more caudal skin island and reconstruct more distant points on the scalp with the help of the delay phenomenon.

This study aimed to present a two-session lower trapezius myocutaneous flap method, in which the surgical delay was applied in the first session, and flap transfer was performed in the second session.

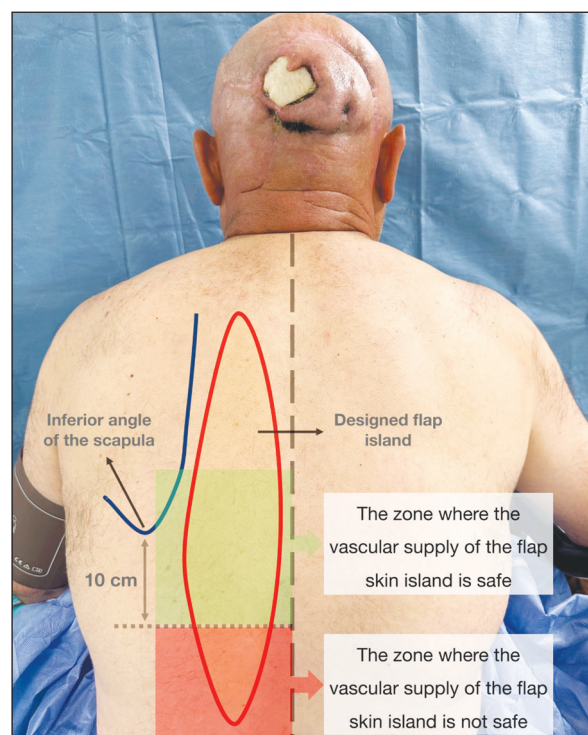
## MATERIAL AND METHODS

Medical records and digital images of patients who had reconstruction of scalp defect with delayed lower

trapezius myocutaneous flap between January 2018 and December 2022 were analyzed retrospectively. Seven patients were included in the study. The study was approved by the Gazi University Ethics Committee (date: January 9, 2024, no: 2024-167). Informed consent was obtained from all patients, and guiding principles from the Declaration of Helsinki were followed. The demographic characteristics of the patients, the characteristics of the defects, the characteristics of the flaps, and the outcomes of the reconstruction were analyzed.

## FLAP DESIGN AND SURGICAL DELAY OF LOWER TRAPEZIUS MYOCUTANEOUS FLAP

The midline, scapula borders, rhomboid muscles, trapezius muscle, and dorsal scapular artery trace were marked while the patient was upright with arms hanging at the sides. Vertically oriented myocutaneous flap borders were drawn, which included the lower part of the trapezius muscle and was sufficient to cover the defect area. In all cases, the caudal border of the flap was located more than 10 cm from the tip of the scapula (Figure 1).



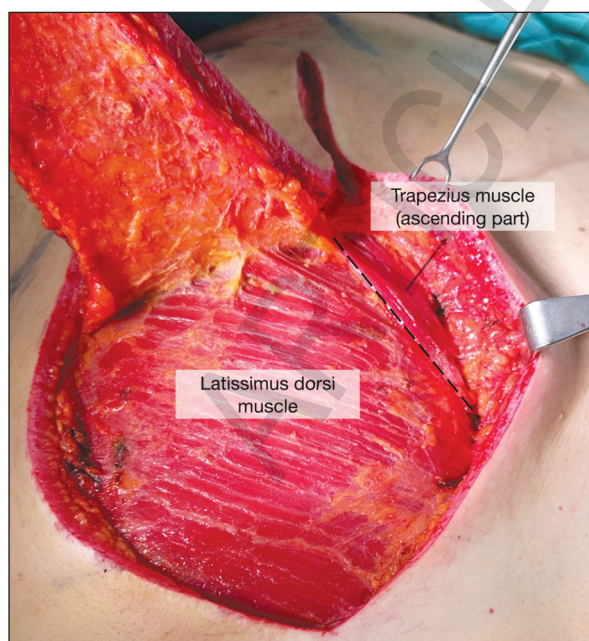
**FIGURE 1:** Anatomic landmarks and flap markings. Typical preoperative markings for a lower trapezius myocutaneous flap. In all cases, the inferior border of the flap was designed at distances much greater than 10 cm from the inferior angle of the scapula.

The first session (the surgical delay procedure) was started in the prone position with the arms abducted at 90 degrees. An incision was made at the lower, medial, and lateral borders of the flap. Starting caudally, the skin island was elevated from the dissection plane between it and the underlying latissimus dorsi muscle. Dissection was terminated when the caudal border of the trapezius muscle was reached near the midline. A suction drain was placed, the skin was closed, and the first session ended (Figure 2).

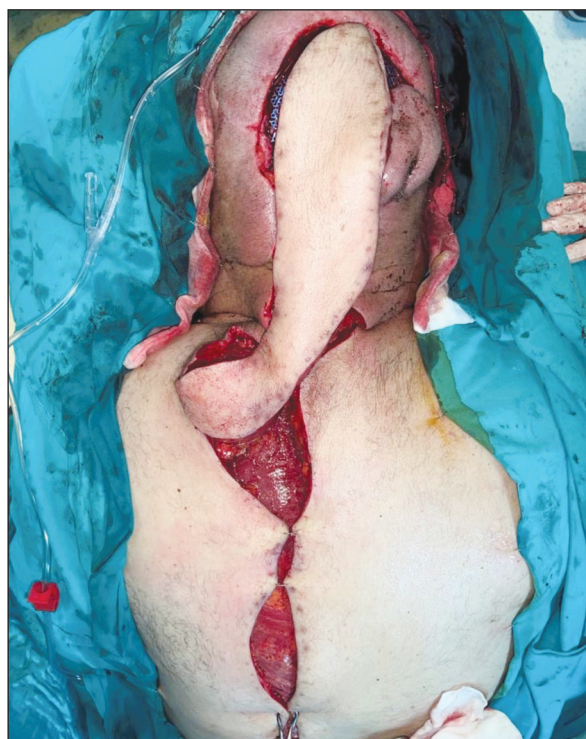
#### TRANSFER OF THE FLAP TO THE DEFECT ON THE SCALP

All markings in the first session were made again in the second session. Again, surgery was started in the prone position with the arms abducted at 90 degrees. The incisions were made again, and the skin island began to be elevated by separating it from the underlying latissimus dorsi muscle from the caudal to the cranial direction. When the caudal border of the trapezius muscle was reached near the midline, the trapezius muscle was elevated together with the skin island as myocutaneous flap while the underlying latissimus dorsi muscle was left in place. Since the

trapezius muscle is the most superficial muscle on the back, it was also elevated from the underlying rhomboid major muscle. When it came to the area between the minor and major rhomboid muscle, it was observed that the flap reached the defect area without tension, and the dissection was terminated (If further release is required, the minor rhomboid muscle can be divided, and a few more cm of dissection can be done) (Figure 3). The flap was isolated as an island flap and brought to the defect area through the posterior neck incisions. It was not used as an interpolation flap. The flap inset was made without tension while the neck was in a neutral position. First the muscle and then the skin were inset to the defect. A suction drain was placed on the back and a Penrose drain was placed in the recipient area. The donor and recipient areas were closed with absorbable sutures. When tension was detected while closing the donor area, a split-thickness skin graft was applied to the high-tension area.



**FIGURE 2:** While performing the surgical delay procedure (first session), the distal part of the flap island was elevated from the underlying latissimus dorsi muscle. Elevation was stopped when the ascending fibers of the trapezius muscle were clearly identified.



**FIGURE 3:** Transfer of delayed lower trapezius myocutaneous flap to cover full-thickness scalp defect (second session).



## RESULTS

Of the 7 patients in the study, 5 were men and 2 were women. The mean age was 56 years (range: 42-62 years). The average duration of postoperative follow-up was 17 months (range: 6-24 months). All defects were full-thickness scalp defects. In one case, some split-thickness skin graft was used when closing the donor area. The average time between the first surgical delay session and the second flap transfer session was 11 days (10-14 days). All patients had uneventful wound healing and defect closure. There were no complications. Table 1 summarizes the characteristics of the cases, the causes of the defects, their locations, and sizes.

Figure 4 shows a 58-year-old male patient who had previously undergone craniotomy for intracranial tumor resection and subsequently underwent multiple rotation flap surgery to cover the scalp defect that developed after craniotomy. The patient's scalp defect was successfully reconstructed with a delayed lower trapezius myocutaneous flap.

## DISCUSSION

The delay phenomenon can be defined as the set of changes that result in increased flap viability after the flap experiences partial ischemia and vascular changes develop in response to ischemia. The delay phenomenon can also be defined as vascular delay or ischemic preconditioning. If the blood flow to the planned flap is surgically reduced, it is called a surgical delay or delay procedure. Surgical delay can be performed in a variety of ways. The non-dominant pedicle of the flap can be ligated, some of the marginal incisions of the flap can be made, or the flap

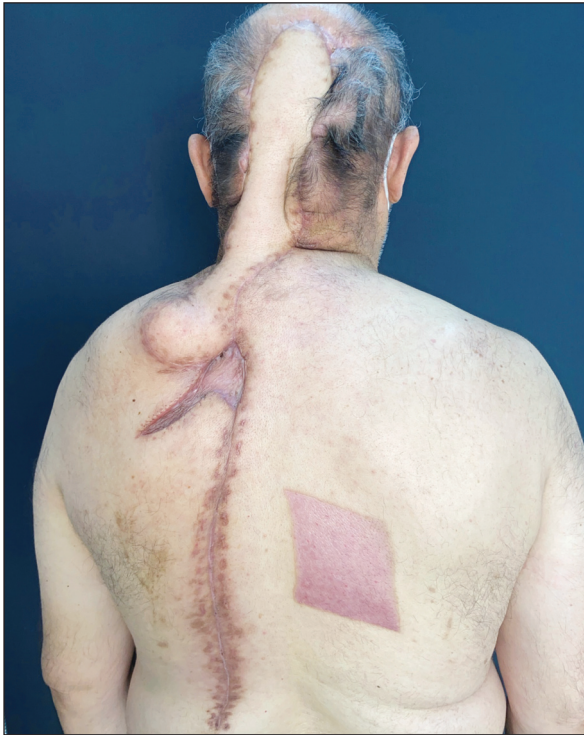can be partially elevated. The delay procedure can be planned as one or multiple stages. Dilatation of choke vessels, which becomes significant 72 hours after the delay procedure, is crucial in increasing flap blood supply. In cases where defect reconstruction is challenging, flap survival or flap dimensions can be increased by using the delay procedure.<sup>8-10</sup>

Local flaps are most commonly used in the reconstruction of full-thickness scalp defects. It may be necessary to perform pedicled regional flaps or free flaps in cases where local flaps are not sufficient (defects larger than approximately 100 cm<sup>2</sup>), in cases where the tissue quality around the defect is inadequate, and in cases where the donor areas of local flaps are not suitable for conventional closure. When it is decided to avoid free flaps due to various factors, pedicled upper trapezius flap, lower trapezius flap, and latissimus dorsi are regional flaps frequently used to reconstruct posterior scalp defects.<sup>1,11</sup> Among these options, the lower trapezius flap is the one that can extend the most towards the vertex because its rotation arc is long. Since only a part of the trapezius muscle is harvested in the lower trapezius flap, the morbidity does not occur as much as in the latissimus dorsi flap. For these reasons, the lower trapezius flap is our choice when a regional flap is needed in posterior scalp defects.

There are some studies in the literature on the lower trapezius myocutaneous flap.<sup>7,12-15</sup> However, there are a few publications showing the extended design. Xie et al. described including a latissimus dorsi segment in the lower trapezius musculocutaneous flap to extend far beyond the border of the trapezius muscle.<sup>16</sup> However, in their study, the tissue defects were not in the distal scalp. Another study on the ex-

TABLE 1: Detailed characteristics of the cases.

Case	Age	Gender	Cause of the defect	Location of the defect	Size of the defect	Follow-up period (months)
Case 1	58	M	Craniotomy due to intracranial tumor	Parietal scalp	9×10 cm	6
Case 2	42	M	Craniotomy due to intracranial tumor	Parietal+occipital scalp	7×12 cm	18
Case 3	55	M	Squamous cell carcinoma	Vertex+parietal scalp	7×10 cm	20
Case 4	66	M	Basal cell carcinoma	Parietal scalp	7×11 cm	12
Case 5	57	M	Malignant melanoma	Parietal scalp	9×9 cm	24
Case 6	55	F	Squamous cell carcinoma	Parietal scalp	7×10 cm	24
Case 7	60	F	Squamous cell carcinoma	Occipital scalp	10×10 cm	12



**FIGURE 4:** Postoperative 6th-month photograph of a 58-year-old male patient (case 1) whose scalp defect was successfully reconstructed with a delayed lower trapezius myocutaneous flap.

tended lower trapezius musculocutaneous flap design was published by Wang et al.<sup>17</sup> Their study reported that if a large flap was to be designed, tissue expansion was performed with a tissue expander placed through a paraspinal incision. Tissue expansion is also a surgical delay technique. It is similar to our study in terms of the application of the delay procedure. The advantage of performing a delay procedure to harvest a lower trapezius musculocutaneous flap with more caudal extension is that there is no tissue expander cost. On the other hand, the advantage of tissue expansion is the possibility of primary closure of the donor site.

A delayed lower trapezius myocutaneous flap is a useful option for reconstructing subacute-chronic wounds unsuitable for microsurgery. Finding a recipient vessel in the occipital region in free flap reconstruction is difficult, which is another advantage of the lower trapezius myocutaneous flap. In addition, the lower trapezius flap is advantageous for wound healing in cases where radiation therapy has been applied to the head and neck region, as it is har-

vested from a remote area that is not affected by radiation therapy. Since the flap contains muscle tissue with high vascularity, it may be advantageous for wound healing in radiated recipient defects.

The disadvantages of performing the lower trapezius myocutaneous flap applying a surgical delay procedure include prolonged treatment time and additional costs due to the two-session nature of the flap. In addition, it is unsuitable for cases where urgent defect reconstruction is required, as it requires two sessions. Since this reconstruction method requires long back and posterior neck incisions, it disrupts the natural lines and transitions in the neck area and creates aesthetic problems.

The limitations of this study are its small sample size, retrospective nature, and lack of a control group. More reliable results could be obtained with prospective study design and more cases.

## CONCLUSION

The lower trapezius myocutaneous flap can be designed more caudally without compromising blood supply by a surgical delay procedure. A delayed lower trapezius myocutaneous flap can be used safely in posterior scalp defects close to the vertex. It is advantageous in patients who do not have local flap options, have relative contraindications for free flaps, have a history of unsuccessful free flaps, and have received radiotherapy to the head and neck region.

### Source of Finance

*During this study, no financial or spiritual support was received neither from any pharmaceutical company that has a direct connection with the research subject, nor from a company that provides or produces medical instruments and materials which may negatively affect the evaluation process of this study.*

### Conflict of Interest

*No conflicts of interest between the authors and / or family members of the scientific and medical committee members or members of the potential conflicts of interest, counseling, expertise, working conditions, share holding and similar situations in any firm.*

### Authorship Contributions

*All authors contributed equally while this study preparing.*

## REFERENCES

1. Haas F, Weiglein A, Futran ND. Trapezius flap. In: Wei FC, Mardini S, eds. *Flaps and Reconstructive Surgery*. 2nd ed. Edinburgh: Elsevier; 2017. p.134-56.
2. McCraw JB, Magee WP Jr, Kalwaic H. Uses of the trapezius and sternomastoid myocutaneous flaps in head and neck reconstruction. *Plast Reconstr Surg*. 1979;63(1):49-57. PMID: 372987.
3. Demergasso F, Piazza MV. Trapezius myocutaneous flap in reconstructive surgery for head and neck cancer: an original technique. *Am J Surg*. 1979;138(4):533-6. PMID: 384820.
4. Baek SM, Biller HF, Krespi YP, Lawson W. The lower trapezius island myocutaneous flap. *Ann Plast Surg*. 1980;5(2):108-14. PMID: 7447278.
5. Mathes SJ, Nahai F. Muscle flap transposition with function preservation: technical and clinical considerations. *Plast Reconstr Surg*. 1980;66(2):242-9. PMID: 7403313.
6. Mathes SJ, Nahai F. Classification of the vascular anatomy of muscles: experimental and clinical correlation. *Plast Reconstr Surg*. 1981;67(2):177-87. PMID: 7465666.
7. Yoon SK, Song SH, Kang N, Yoon YH, Koo BS, Oh SH. Reconstruction of the head and neck region using lower trapezius musculocutaneous flaps. *Arch Plast Surg*. 2012;39(6):626-30. PMID: 23233888; PMCID: PMC3518006.
8. Dhar SC, Taylor GI. The delay phenomenon: the story unfolds. *Plast Reconstr Surg*. 1999;104(7):2079-91. PMID: 11149772.
9. Hamilton K, Wolfswinkel EM, Weathers WM, Xue AS, Hatef DA, Izaddoost S, et al. The delay phenomenon: a compilation of knowledge across specialties. *Craniomaxillofac Trauma Reconstr*. 2014;7(2):112-8. PMID: 25071876; PMCID: PMC4078182.
10. Gersch RP, Fourman MS, Drace C, Bui DT, Dagum AB. The delay phenomenon: is one surgical delay technique superior? *Plast Reconstr Surg Glob Open*. 2017;5(10):e1519. PMID: 29184734; PMCID: PMC5682170.
11. Alessandri-Bonetti M, David J, Egro FM. Pedicled latissimus dorsi flap for extensive scalp reconstruction in acute burns. *Plast Reconstr Surg Glob Open*. 2023;11(8):e5217. PMID: 37600832; PMCID: PMC10438794.
12. Yang HJ, Lee DH, Kim YW, Lee SG, Cheon YW. The trapezius muscle flap: a viable alternative for posterior scalp and neck reconstruction. *Arch Plast Surg*. 2016;43(6):529-35. PMID: 27896183; PMCID: PMC5122541.
13. Naalla R, Murthy V, Chauhan S, Chinta K, Singhal M. Revisiting the trapezius flap as a reconstructive option for cervico-occipital and thoracic spine regions. *Indian J Plast Surg*. 2019;52(3):322-3. PMID: 31908371; PMCID: PMC6938435.
14. Baghaki S, Yalcin CE, Khankishiyev R, Suleymanov S, Oner MB, Temiz K, et al. Propeller and pre-expanded propeller use of a transversely oriented upper trapezius perforator flap in head and neck reconstruction: clinical experience and review of vascular anatomy of the supraspinal trapezius muscle. *J Plast Reconstr Aesthet Surg*. 2021;74(7):1534-43. PMID: 34031005.
15. Wang Q, Li Z, Xu X, Zhou X, Wang T. Trapezius perforator flaps based on superficial cervical artery and dorsal scapular artery: an anatomical study and a systematic review of their clinical application. *Ann Plast Surg*. 2022;89(4):437-43. PMID: 35502939.
16. Xie T, Wang M, Zang M, Zhu S, Li S, Han T, et al. Inclusion of a latissimus dorsi segment in an extended lower trapezius musculocutaneous flap facilitates complex defect reconstruction. *J Plast Reconstr Aesthet Surg*. 2022;75(9):3155-65. PMID: 35654689.
17. Wang M, Zang M, Zhu S, Li S, Han T, Chen Z, et al. Lower trapezius myocutaneous propeller flap based on dorsal scapular artery. *Ann Plast Surg*. 2022;89(5):502-9. PMID: 36279574.