

## Poland's Syndrome: Letter to the Editor

### Poland Sendromu

Abdullah ŞİMŞEK,<sup>a</sup>  
Halil ÇELİK TEN,<sup>a</sup>  
Mesiha BABALIK<sup>a</sup>

<sup>a</sup>Clinic of Chest Diseases,  
Prof.Dr. Türkan Akyol Chest Diseases  
Hospital, Bursa

Geliş Tarihi/Received: 31.01.2016  
Kabul Tarihi/Accepted: 10.02.2016

Yazışma Adresi/Correspondence:  
Abdullah ŞİMŞEK  
Prof.Dr. Türkan Akyol Chest Diseases  
Hospital,  
Clinic of Chest Diseases, Bursa,  
TÜRKİYE/TURKEY  
abdullahsimsek1@yahoo.com.tr

**Key Words:** Poland syndrome;  
therapy

**Anahtar Kelimeler:** Poland sendromu;  
tedavi

**Türkiye Klinikleri Arch Lung**  
2016;17(1):13-4

doi: 10.5336/archlung.2016-50395

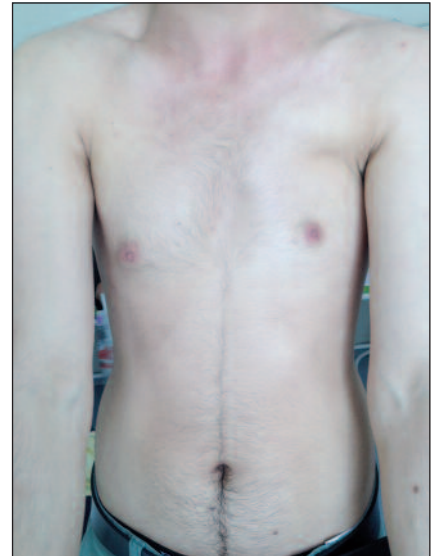Copyright © 2016 by Türkiye Klinikleri

Poland's syndrome is a rare anomaly characterized by unilateral absence (partial or complete) of the pectoralis muscles and ipsilateral syndactyly and microdactyly. Associated anomalies include defect of the breast and anterior chest wall.<sup>1</sup> The incidence of this condition ranges from 1: 20 000 to 1:50 000 live births as reported by different authors.<sup>2</sup> The right side of the body is more frequently affected than the left, and it is more common in boys than in girls.<sup>2</sup>

A 21 years old nonsmoking man admitted to hospital with a complaint of the lack of left breast muscle since birth. He had no any symptom. But he was not satisfied with the asymmetrical body image and worried for possible heart damage due to trauma in the future because of absence of left breast. Physical examination revealed left sided hypoplasia of the sternocostal portion of pectoralis major muscle (Figure 1, 2). There were no hand and finger anomalies. Chest X ray revealed hyperlucency on the left side of lung (Figure 3). Pulmonary function test results were normal (FEV: 89%, FVC: 85%, FEV<sub>1</sub>/FVC: 89%).

Laboratory findings were normal. He was followed without treatment.

The typical components of Poland's syndrome include unilateral hypoplasia or absence of the sternocostal portion of pectoralis major muscle and hand defects (as syndactyly) affecting the same side of the body.<sup>3,4</sup> Co-



**FIGURE 1:** Left sided hypoplasia of pectoralis major muscle.

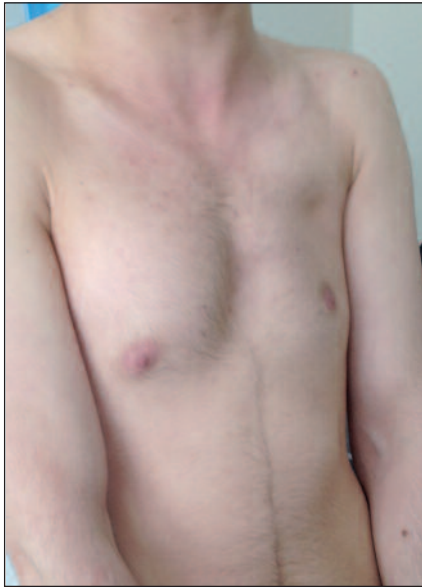


FIGURE 2: Left sided hypoplasia of pectoralis major muscle.

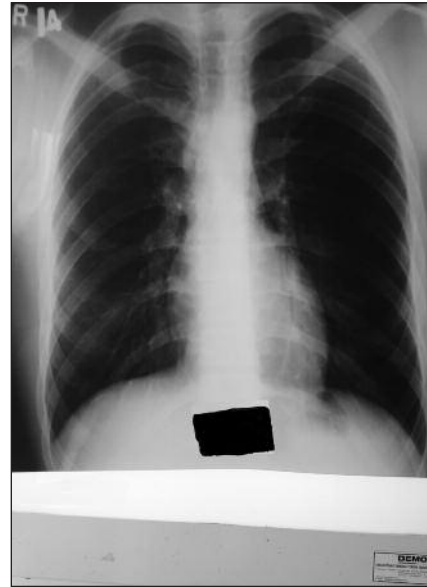


FIGURE 3: Hyperlucency on the left side of lung.

existing defects of the chest wall and the hand are referred to as complete Poland's syndrome.<sup>3</sup> However, more commonly, patients suffer from isolated pectoralis major muscle hypoplasia or aplasia and are diagnosed with partial Poland's syndrome.<sup>3</sup>

The exact etiology of Poland's syndrome is unknown. Although several theories of etiogenesis have been proposed, the vascular theory appears to be the most favored by many.<sup>2</sup> This theory describes an interruption of early embryonic blood supply to subclavian arteries, the vertebral arteries and/or their branches.<sup>5</sup>

Patients with rib cage anomalies may exhibit paradoxical respiratory movement leading to inad-

equately ventilation, especially during general anesthesia.<sup>1</sup> Chest radiograph may reveal an area of hyperlucency on the affected side that mimics a radical mastectomy.

More common indications for surgery are aesthetic reasons and psychological aspects, and such surgeries are performed after the patient goes through the developmental stage of life, i.e. reaches the age of 18.<sup>3</sup> The therapeutic approach is chosen individually for each patient, depending on the severity of pathology, patient's age and gender.<sup>3</sup> As plastic surgery, syndactyly corrections are mainly performed. The second group of procedures performed in Poland's syndrome are chest surgeries.

## REFERENCES

1. Marui Y, Nitahara K, Iwakiri S, Shono S, Sakuragi T, Higa K. [Anaesthetic management of patients with Poland syndrome: report of two cases]. *Masui* 2003;52(3):274-6.
2. Nachnani JS, Supe AN. A variant of Poland syndrome. *J Postgrad Med* 2001;47(2):131-2.
3. Fokin AA, Robicsek F. Poland's syndrome revisited. *Ann Thorac Surg* 2002;74(6):2218-25.
4. Mentzel HJ, Seidel J, Sauner D, Vogt S, Fitzek C, Zintl F, et al. Radiological aspects of the Poland syndrome and implications for treatment: a case study and review. *Eur J Pediatr* 2002;161(8):455-9.
5. Bavincck JN, Weaver DD. Subclavian artery supply disruption sequence: hypothesis of a vascular etiology for Poland, Klippel-Feil, and Mobius anomalies. *Am J Med Genet* 1986;23(4):903-18.