

CASE REPORT OLGU SUNUMU

DOI: 10.5336/jtracom.2024-106446

The Effectiveness of Major Ozone Therapy in Coxarthrosis and Femoral Head Avascular Necrosis

Koksartroz ve Femur Başı Avasküler Nekroz Birlikteliğinde Major Ozon Tedavisinin Etkinliği

 Deniz BULUT^a

^aAlanya Alaaddin Keykubat University Faculty of Medicine, Department of Physical Medicine and Rehabilitation, Antalya, Türkiye

ABSTRACT Avascular necrosis (AVN), meaning the cellular death of bone, can occur for various reasons. The goal in the treatment of avascular necrosis of the femoral head, which is a very difficult problem to solve, is to preserve the current anatomical structure. A 55-year-old male patient was identified with hip AVN and coxarthrosis on MRI. The patient underwent 12 sessions of major autohemotherapy and 15 sessions of physical therapy. The patient's pain Visual Analog Scale (VAS) score decreased from 10 to 2 after treatment. Significant improvement was achieved in WOMAC score, Harris hip score and SF-36 scores after treatment. We present this case to the literature because the patient responded very well to conservative treatment, major ozone therapy, and there was regression of edema on hip MRI.

Keywords: Femur head necrosis; ozone; hip osteoarthritis; osteonecrosis

ÖZET Kemik hücrelerinin ölümü anlamına gelen avasküler nekroz (AVN), çeşitli nedenlerle ortaya çıkabilir. Çözülmesi çok zor bir sorun olan femur başı avasküler nekrozunun tedavisinde amaç, mevcut anatomik yapıyı korumaktır. 55 yaşında bir erkek hastada manyetik rezonans görüntüleme (MRG) kalça AVN'si ve koksartroz tespit edildi. Hastaya 12 seans majör otohemoterapi ve 15 seans fizik tedavi uygulandı. Hastanın [Visual Analog Scale (VAS)] ağrı skoru tedaviden sonra 10'dan 2'ye düştü. Tedaviden sonra WOMac Osteoartrit İndeksi, Harris kalça skoru ve SF-36 skorlarında belirgin iyileşme sağlandı. Bu olguyu hasta konservatif tedaviyle birlikte uygulanan majör ozon tedavisine çok iyi yanıt verdiği ve kalça MRG'da ödemde gerileme olduğu için literatüre sunuyoruz.

Anahtar Kelimeler: Femur başı nekrozu; ozon; kalça osteoartriti; osteonekroz

Femoral head avascular necrosis (FAVN) is the name given to osteonecrosis that develops in the femoral head due to occlusion of the vessels feeding the femoral head for various reasons or decreased blood flow to the femoral head.¹ FAVN has been associated with many medical conditions and many factors have been held responsible for its formation, but no cause other than trauma has been able to clearly explain this pathological phenomenon and the etiology of the disease has not been fully elucidated. Frequently, no cause can be found that leads to osteonecrosis and it is considered as idiopathic osteonecrosis.¹

The treatment of the disease varies according to the clinical and radiological status.² FAVN causes coxarthrosis formation in the early stage. In FAVN patients, collapse and coxarthrosis of the femoral head are seen in more than 30%.³

TO CITE THIS ARTICLE:

Bulut D. The effectiveness of major ozone therapy in coxarthrosis and femoral head avascular necrosis. J Tradit Complem Med. 2025;8(2):97-100.

Correspondence: Deniz BULUT

Alanya Alaaddin Keykubat University Faculty of Medicine, Department of Physical Medicine and Rehabilitation, Antalya, Türkiye

E-mail: deniz.bulut@alanya.edu.tr



Peer review under responsibility of Journal of Traditional Medical Complementary Therapies.

Received: 23 Oct 2024

Received in revised form: 13 Jan 2025

Accepted: 21 Jan 2025

Available online: 05 Mar 2025

2630-6425 / Copyright © 2025 by Türkiye Klinikleri. This is an open access article under the CC BY-NC-ND license (<http://creativecommons.org/licenses/by-nc-nd/4.0/>).

The aim of the treatment of FAVN is to preserve the current anatomical structure, although it is difficult to solve. Therefore, patient factors such as age, general condition, and accompanying diseases, as well as other important parameters such as the stage of the disease and the location and size of the segment affected by the disease, should be taken into consideration.¹

Ozone therapy can be used for different indications. The immunomodulatory, anti-inflammatory and anti-oxidative effects of ozone injection are used in degenerative and inflammatory diseases related to the musculoskeletal system.⁴ Major autohemotherapy (AHT) is the most well-known and most widely used application method. AHT is a low-risk application and the contact and reaction of ozone with blood occurs outside the patient's body. Ozone applications are not an alternative to conservative treatments, but a complement. The doctor should evaluate the patient in all aspects and should not neglect important components of the treatment such as medical treatments, prevention principles, exercises, and assistive devices.⁴

CASE REPORT

A 55-year-old male patient presented with mechanical right hip pain that started suddenly 1.5 months ago (increased during movement, but continued at rest and at night). He was an architect. He had hypertension and coronary artery disease. There was no new medication or substance use. He was smoking. (10 cigarettes a day) He was not an alcoholic. There was no fever, weight loss, or night sweats. Neurological examination was normal, right hip Range of motion (ROM) was 100/120 degrees, the flexion abduction external rotation was positive on the right, there was no sign of arthritis. Antalgic gait was present, there was no leg length difference. X-ray of the right hip showed sclerosis of the joint surfaces, narrowing of the joint space, and degenerative cystic formation in the acetabulum. Hip magnetic resonance imaging (MRI) taken with a preliminary diagnosis of coxarthrosis revealed minimal edema in the bone marrow of the right femoral head (early avascular necrosis) (Figure 1).

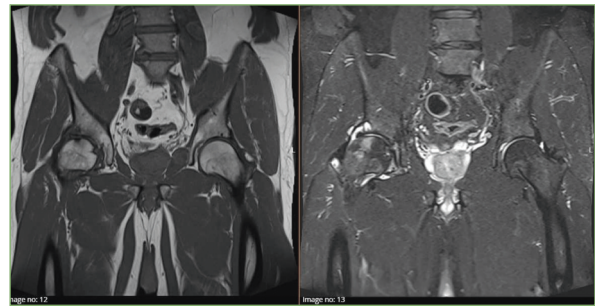


FIGURE 1: T1 (right) and short tau inversion recovery sequence (left) images of the right hip coronal section T1-weighted series, hypo-, T2-weighted series and hypo-and hyperintense signal changes

The patient was diagnosed with hip avascular necrosis based on anamnesis, examination and MRI findings. The patient was consulted to internal medicine to investigate possible underlying etiological causes. No malignancy, hematological disease etc. was detected. The orthopedic department did not recommend surgical intervention. Medical treatment (non-steroidal anti-inflammatory drug) and home exercise program that includes gentle stretching and range of motion exercises were planned. They were taught to use a cane to reduce the load on the lower extremities while walking. The patient underwent 15 sessions of physical therapy and rehabilitation program [hot pack, ultrasound (1 watt/cm²), conventional transcutaneous electrical nerve stimulation. Additionally, the patient underwent AHT for a total of 12 sessions (starting from 25 gamma and increasing up to 40 gamma). The patient did not report any side effects during and after treatment.

The patient completed the Western Ontario and McMaster Universities Osteoarthritis Index, Harris hip score (HHS) and Short Form-36 quality of life questionnaire before and after treatment. Hip pain was assessed with a 10 cm visual analog scale. Pre- and post-treatment values are shown in Table 1. In the hip MRI taken after treatment, regression of edema was observed in the T2 Short tau inversion recovery sequence (Figure 2).

Written and verbal consent was obtained from the patient to be used in the case presentation.

TABLE 1: Pre- and post-treatment values

	Before treatment	After treatment
VAS	10	2
SF-36 Physical function	15	75
SF-36 Physical role difficulty	0	100
SF-36 Emotional role difficulty	0	100
SF-36 Energy/vitality	40	75
SF-36 Mental health	48	92
SF-36 Social functioning	0	75
SF-36 Pain	0	77.5
SF-36 General health	35	80
WOMAC-Pain	18	4
WOMAC-Stiffness	6	1
WOMAC-Function	61	6
HHS	38	86

VAS: Visual analogue scale; SF-36: 36-Item Short Form Health Survey;
 WOMAC: Western Ontario and McMaster Universities Arthritis Index;
 HHS: Harris hip score

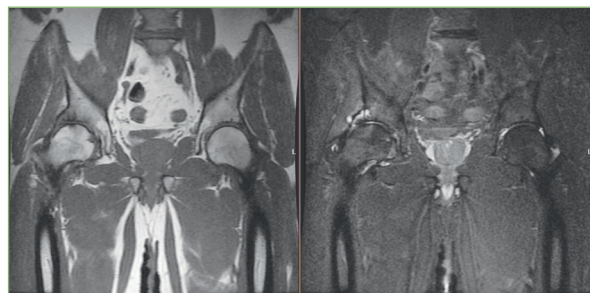


FIGURE 2: T1 (right) and short tau inversion recovery sequence (left) images of the right hip coronal section post-treatment

DISCUSSION

Osteonecrosis occurs because of decreased oxygen delivery or blood flow to the bone; however, the clinical condition is a result of the repair process rather than the initial ischemia.⁵

Ozone therapy is widely used in the treatment of musculoskeletal pain by utilizing the biochemical effects of the O₂-O₃ mixture. Studies on ozone therapy in spinal pain generally focus on the lumbosacral region. No significant complications of the treatment were reported.⁶ We did not encounter any side effects in our patient during and after treatment.

It was reported that one therapeutic effect of O₃ AHT is increasing the generation of endogenous vasodilators, such as nitric oxide and carbon monoxide.⁷ Another benefit of O₃-AHT is the enhanced

glycolysis and concentration of 2,3-diphosphoglycerate in erythrocytes, which increases the oxygen supply for ischemic tissues and improves the micro-circulatory disturbance, resulting in promoting repair of bone necrosis.⁸

In a study of 6 cancer patients with persistent or severe pelvic pain who had previously been treated with radiotherapy, chemotherapy, or endoscopic procedures, they received ozone therapy using O₂-O₃ gas mixture insufflation in addition to their conventional treatments. The median score for “pain symptom” decreased from 3 to 1 ($p=0.046$).⁹ In our case, we also found a significant regression in the hip pain VAS value.

In a study conducted with 71 FAVN patients, one group received intraarticular O₂-O₃ hip injections and O₃-AHT, and the other group received protected weight-bearing. VAS for pain and HHS for function were assessed. Bone marrow edema examination and conversion to total hip arthroplasty (THA) were assessed. Ozone therapy has been shown to be associated with significant pain relief, improvement in hip function, and regression of bone marrow edema and may delay the need for THA.¹⁰ We also used the VAS and HHS in the same way when evaluating our patient.

Pericapsular nerve group (PENG) block with a mixture of steroid and local anesthetic+intra-articular ozone therapy in three sessions at one-week intervals was applied to an 82-year-old patient with severe right coxarthrosis who could not be operated on due to comorbidities. Since pain relief was for a shorter duration, it was decided to apply PENG treatment with pulsed radiofrequency (RF) to the patient. Ozone therapy is a new and popular treatment for chronic pain. In this study, interfascial plane block+ozone+RF were combined. This regimen provided analgesia for the patient.¹¹ We observed improvement in pain and function in our patient by applying only AHT.

Even in patients with asymptomatic AVN, the risk of femoral head collapse and progression to symptomatic disease is high. When AVN is diagnosed at an early stage, patients should be advised to avoid excessive pressure on the joint, a healthy diet, and avoid weight gain weight to reduce the progression of os-

teonecrosis.¹² We also informed them about FAVN, investigated possible etiological factors, and continued to monitor the patient for progression.

It should be kept in mind that ozone therapy can be used in addition to conservative treatments to improve quality of life and reduce pain in suitable patients with avascular necrosis. However, more randomized controlled prospective studies are needed on this subject.

Source of Finance

During this study, no financial or spiritual support was received neither from any pharmaceutical company that has a direct con-

nection with the research subject, nor from a company that provides or produces medical instruments and materials which may negatively affect the evaluation process of this study.

Conflict of Interest

No conflicts of interest between the authors and / or family members of the scientific and medical committee members or members of the potential conflicts of interest, counseling, expertise, working conditions, share holding and similar situations in any firm.

Authorship Contributions

This study is entirely author's own work and no other author contribution.

REFERENCES

- Özdemir H, Baloğlu M. Femur başının avasküler nekrozu: tanı ve tedavisi [Avascular necrosis of the femoral head: diagnosis and treatment]. TOTBİD Dergisi. 2010;9(1):41-51. [\[Link\]](#)
- Mont MA, Cherian JJ, Sierra RJ, Jones LC, Lieberman JR. Nontraumatic osteonecrosis of the femoral head: where do we stand today? A ten-year update. J Bone Joint Surg Am. 2015;97(19):1604-27. [\[Crossref\]](#) [\[PubMed\]](#)
- Min BW, Song KS, Cho CH, Lee SM, Lee KJ. Untreated asymptomatic hips in patients with osteonecrosis of the femoral head. Clin Orthop Relat Res. 2008;466(5):1087-92. [\[PubMed\]](#) [\[PMC\]](#)
- Dıraçoğlu D. Ozone-oxygen therapies in musculoskeletal diseases. Turkish Journal of Physical Medicine and Rehabilitation. 2016;62(2):183-92. [\[Link\]](#)
- George G, Lane JM. Osteonecrosis of the femoral head. J Am Acad Orthop Surg Glob Res Rev. 2022;6(5):e21.00176. [\[PubMed\]](#) [\[PMC\]](#)
- Jandura J, Vajda M, Cech M, Ryska P. Oxygen-ozone therapy of musculoskeletal neck pain: a review. J Pers Med. 2024;14(3):326. [\[Crossref\]](#) [\[PubMed\]](#) [\[PMC\]](#)
- de Monte A, van der Zee H, Bocci V. Major ozonated autohemotherapy in chronic limb ischemia with ulcerations. J Altern Complement Med. 2005;11(2):363-7. [\[Crossref\]](#) [\[PubMed\]](#)
- Hu B, Zheng J, Liu Q, Yang Y, Zhang Y. The effect and safety of ozone autohemotherapy combined with pharmacological therapy in postherpetic neuralgia. J Pain Res. 2018;11:1637-43. [\[PubMed\]](#) [\[PMC\]](#)
- Clavo B, Navarro M, Federico M, Borrelli E, Jorge IJ, Ribeiro I, et al. Ozone therapy in refractory pelvic pain syndromes secondary to cancer treatment: a new approach warranting exploration. J Palliat Med. 2021;24(1):97-102. [\[Crossref\]](#) [\[PubMed\]](#)
- An JX, Wu GP, Niu K, Wei YP, Liu H, Gao XY, et al. Treatment of femoral head osteonecrosis with ozone therapy: pilot trial of a new therapeutic approach. Pain Physician. 2022;25(1):E43-E54. [\[PubMed\]](#)
- Alici HA, Ciftci B, Alver S, Ahiskalioglu A, Bilal B, Tulgar S. The role of interfascial plane blocks in multimodal chronic pain management: PENG block+pulsed radiofrequency+ozone therapy for hip osteoarthritis. Minerva Anesthesiol. 2023;89(7-8):718-21. [\[PubMed\]](#)
- Lespasio MJ, Sodhi N, Mont MA. Osteonecrosis of the hip: a primer. Perm J. 2019;23:18-100. [\[Crossref\]](#) [\[PubMed\]](#) [\[PMC\]](#)