

A Case of Flagellate Hyperpigmentation Following Bleomycin Therapy

BLEOMİSİN TEDAVİSİNDEN SONRA GELİŞEN FLAGELLA BENZERİ HİPERPİGMENTASYON OLGUSU

Savaş YAYLI, MD,^a Sevgi BAHADIR, MD,^a Ümit ÇOBANOĞLU, MD,^b
Hikmet AKYAZI, MD,^a Sibel UNCU, MD^a

Departments of ^aDermatology, ^bPathology, Karadeniz Technical University Medical Faculty, TRABZON

Abstract

Flagellate hyperpigmentation is a striking reaction to bleomycin use, and shows various clinical and histopathological features.

We present a case of bleomycin-induced flagellate hyperpigmentation. Our patient developed a pruritic, linear flagellate eruption 3 days after his first dose of bleomycin. The eruption resolved in a month leaving residual linear and flagellate hyperpigmentation.

Key Words: Bleomycin, flagellate hyperpigmentation

Türkiye Klinikleri J Dermatol 2006, 16:123-125

Özet

Flagella benzeri hiperpigmentasyon, bleomisin kullanımına bağlı gelişen ilginç bir reaksiyon olup, çeşitli klinik ve histopatolojik özellikler gösterir.

Bleomisinindüklediği bir flagella benzeri hiperpigmentasyon olgusu sunuyoruz. Hastamızda, ilk bleomisin dozundan üç gün sonra kaşıntılı, lineer, flagella benzeri bir erüpsiyon gelişti. Bu erüpsiyon bir ay içerisinde yerinde lineer ve flagella benzeri bir pigmentasyon bırakarak iyileşti.

Anahtar Kelimeler: Bleomisin, flagella benzeri hiperpigmentasyon

Bleomycin is a polypeptide, antineoplastic, antibiotic which inhibits the incorporation of thymidine into DNA. It is used in the treatment of a variety of tumours.¹ Mucocutaneous reactions due to bleomycin are common, and the linear flagellate hyperpigmentation is an eruption that occurs following the therapy.²⁻⁴

We report a patient with bleomycin-induced flagellate hyperpigmentation with review of the literature about its clinical and histopathologic features and possible pathogenic mechanisms.

Case Report

A 25 year old male with seminoma of the testis was commenced on a 3-weekly course of com-

bination chemotherapy with bleomycin, etoposide, cisplatin. Three days after his first course of bleomycin therapy (30 mg), he developed a striking eruption consist of linear erythematous papules and plaques over the neck, shoulders, upper trunk and arms with pruritus and tenderness. The eruption resolved in a month leaving residual linear and flagellate hyperpigmentation (Figure 1). Histological examination of the hyperpigmented skin patches demonstrated increased melanin content in basal keratinocytes with active melanocytes and pigment incontinence (Figure 2). Combination chemotherapy with bleomycin, etoposide, cisplatin were continued, but he did not develop similar eruptions. The patient rejected to use any medication for cutaneous hyperpigmentation.

Discussion

Bleomycin is a sulphur-containing polypeptide, antineoplastic antibiotic which was derived from *Streptomyces verticillaris*. It was first developed in 1965 by Umezawa.⁵ Bleomycin inhibits

Geliş Tarihi/Received: 14.07.2005 Kabul Tarihi/Accepted: 10.04.2006

Yazışma Adresi/Correspondence: Savaş YAYLI, MD
Karadeniz Technical University Medical Faculty,
Departments of Dermatology, TRABZON
savas_an@yahoo.com

Copyright © 2006 by Türkiye Klinikleri

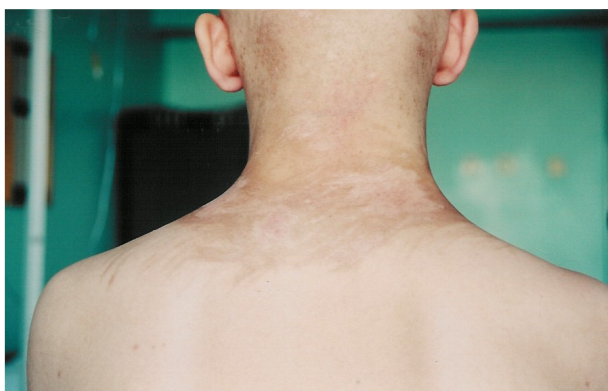

Figure 1. Linear flagellate hyperpigmentation on the neck.

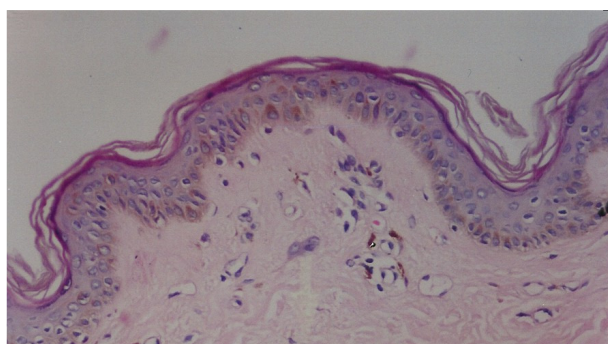


Figure 2. Increased amount of melanin pigmentation in the basal keratinocytes and pigment incontinence in the dermis (H&E, original magnification x200).

the incorporation of thymidine into DNA and causes splitting of DNA into smaller fragments.¹ It is widely used in the treatment of malignancies including lymphomas, germ cell tumors and squamous cell carcinoma of the head and neck. Following its administration, bleomycin is inactivated by a hydrolase enzyme. This enzyme is absent in the skin and lung, and thus high concentrations of the drug in these organs cause toxic reactions.^{6,7} Bleomycin-induced mucocutaneous reactions are common, and include stomatitis, alopecia, nail deformities, ulcers of palms and soles, scaling erythematous bullous lesions, sclerodermoid lesions, warty hyperkeratotic plaques and inflammatory nodules, pigmentary alterations.^{2,8}

The overall incidence of hyperpigmentation occurring during bleomycin use is approximately 30%.⁹ The flagellate streaks of hyperpigmentation is an interesting feature that occur in 8-20% of

cases. The reaction may occur from a few hours up to 9 weeks after the administration of the drug. Furthermore, it can occur after both small and large doses as 15 mg or 285 mg.^{3,4,10-14} The typical routes of administration are intramuscular or intravenous, and most cases of linear flagellate hyperpigmentation have followed i.v and i.m administration. However, flagellate hyperpigmentation has been reported following intralesional bleomycin treatment of verruca plantaris and intrapleural bleomycin as a sclerosing agent.¹⁴⁻¹⁶

This type of hyperpigmentation may occur de novo, but sometimes it follows a flagellate dermatosis consist of erythematous papules and plaques or urticarial -like lesions. The lesions are usually seen over the upper trunk and limbs and may be associated with pruritus.^{4,14} There are many theories to explain the mechanism responsible for the clinical features including post-inflammatory changes associated with intense pruritus, the local accumulation of bleomycin in the skin, an allergic drug reaction.^{9,14,17}

The local accumulation of bleomycin in the skin due to vasodilatation caused by dermographic stimulus such as scratching may lead a direct toxic effect on the keratinocytes.¹⁷ The mechanism of increased melanogenesis may be due to a direct effect of the bleomycin on the melanocytes, or as a result of the release of mediators from surrounding keratinocytes. However, the linear flagellate pigmentation may occur in the absence of the itching. An allergic drug reaction has been proposed, but linear and flagellate pattern of hyperpigmentation is difficult to be explained by this.^{4,14} Topically applied bleomycin in tape stripped skin of the patients has been found to induce marked erythema within 48 h. After 3 weeks, hyperpigmented patches occurred.⁴ This may be related with the toxic effect of topical bleomycin.

The histopathologic findings reveal an increased epidermal pigmentation with increased melanin content in basal keratinocytes, active melanocytes and some degree of pigment incontinence.^{12,16,17}

Additional studies are required to explain the linear and flagellate pattern of the hyperpigmentation due to bleomycin therapy.

REFERENCES

1. Dantzig, PI. Immunosuppressive and cytotoxic drugs in dermatology. *Arch Dermatol* 1974;110:393-406.
2. Mowad CM, Nguyen TV, Elenitsas R, Leyden JJ. Bleomycin-induced flagellate dermatitis: A clinical and histopathological review. *Br J Dermatol* 1994;131:700-2.
3. Nigro MG, Hsu S. Bleomycin-Induced Flagellate Pigmentation. *Cutis* 2001;68:285-6.
4. Nayak N, Friedmann PS, Healy E. Case 2. Bleomycin-induced flagellate dermatosis. *Clin Exp Dermatol* 2003;28:105-6.
5. Umezawa H. Bleomycin and other antitumour antibiotics of high molecular weight. *Antimicrob Agent Chemother* 1965;5:1079-85.
6. Evans WE, Yee GC, Crom WR, Pratt Cb, Green AA. Clinical pharmacology of bleomycin and cisplatin. *Head Neck Surg* 1981;4:98-110.
7. Lindae ML, Hu CH, Nickoloff BJ. Pruritic erythematous linear plaques on the neck and back. *Arch Dermatol* 1987;12:393-8.
8. Yagoda A, Mukherji B, Young C, et al. Bleomycin, an antitumor antibiotic. Clinical experience in 274 patients. *Ann Intern Med* 1972;77:861-70.
9. Bronner AK, Hood AF. Cutaneous complications of chemotherapeutic agents. *J Am Acad Dermatol* 1983;9:645-63.
10. Polla L, Merot Y, Slosman D, Polla B, Olgiate D, Saurat JH. Dermite lineaire et pigmentogene apres scintigraphie a la bleomycin. *Ann Dermatol Venereol* 1985;112:821-3.
11. Cortina P, Garrido JA, Thomas JF, Unamuno P, Armijo M. Flagellate erythema from bleomycin. With histopathological findings suggestive of inflammatory oncotaxis. *Dermatologica* 1990;180:106-9.
12. Wright AL, Bleehen SS, Champion AE. Reticulate pigmentation due to bleomycin: light-and electron-microscopic studies. *Dermatologica* 1990;180:255-7.
13. Rademaker M, Thomas RH, Meyrick Lowe DG, Munro DD. Linear streaking due to bleomycin. *Clin Exp Dermatol* 1987;12:457-9.
14. Rubeiz NG, Salem Z, Dibbs R, Kibbi AG. Bleomycin-induced urticarial flagellate drug hypersensitivity reaction. *Int J Dermatol* 1999;38:140-1.
15. Abess A, Keel DM, Graham BS. Flagellate hyperpigmentation following intralesional bleomycin treatment of verruca plantaris. *Arch Dermatol* 2003;139:337-9.
16. Fernandez-Obregon AC, Hogan KP, Bibro MK. Flagellate pigmentation from intrapleural bleomycin. A light microscopy and electron microscopy study. *J Am Acad Dermatol* 1985;13:464-8.
17. Guillet G, Guillet MH, de Meaux H, et al. Cutaneous pigmented stripes and bleomycin treatment. *Arch Dermatol* 1986; 122:381-2.