

# Transient Pulmonary Perfusion Abnormality After Massive Exchange Transfusion: Case Report

## Kan Değişimi Sonrası Geçici Pulmoner Perfüzyon Bozukluğu

İlknur KILIÇ, MD,<sup>a</sup>  
Özmerit M.A. ÖZDEMİR, MD,<sup>a</sup>  
Dolunay GÜRSES, MD,<sup>a</sup>  
Fatma DUKSAL, MD,<sup>a</sup>  
Fatma Suna KIRAÇ, MD<sup>b</sup>

Departments of  
<sup>a</sup>Pediatrics,  
<sup>b</sup>Nuclear Medicine,  
Pamukkale University  
Faculty of Medicine, Denizli

Geliş Tarihi/Received: 22.12.2008  
Kabul Tarihi/Accepted: 12.02.2009

*This article was reported as a poster (oral) presentation at the XXV UNEKO, Antalya, Turkey, April 4-7, 2007.*

Yazışma Adresi/Correspondence:  
Özmerit M.A. ÖZDEMİR, MD  
Pamukkale University  
Faculty of Medicine,  
Department of Pediatrics, Denizli,  
TÜRKİYE/TURKEY  
drozmert@gmail.com

**ABSTRACT** The principal indications for exchange transfusion are hemolytic diseases of the newborn with hyperbilirubinemia. However, there are some potential complications of exchange transfusion such as infection, coagulopathies (i.e., thrombocytopenia), electrolyte abnormalities (i.e., hypocalcemia), metabolic acidosis, hypoglycemia, and necrotizing enterocolitis. Stored blood develops some platelet-white cell microaggregates. These microaggregates or blood debris have been found to produce changes in pulmonary hemodynamics in animals and have been implicated in post-traumatic pulmonary insufficiency in man. Authors suggested that pulmonary gas exchange alterations following blood transfusion were primarily due to increased dead-space ventilation secondary to vasoconstriction and occlusion of the pulmonary microvasculature because of microaggregates. In this article, a newborn with transient pulmonary perfusion abnormality who had massive exchange transfusion for Rh isoimmunization and hyperbilirubinemia was reported.

**Key Words:** Infant, newborn; exchange transfusion, whole blood; pulmonary diffusing capacity

**ÖZET** Kan değişimi tedavisi esas olarak hemolitik hastalığı olan hiperbilirübinemili yenidoğanlarda endikedir. Ancak, kan değişimi uygulamasının infeksiyon, koagülopati (trombositopeni gibi), elektrolit anormalliği (hipokalsemi gibi), metabolik asidoz, hipoglisemi ve nekrotizan enterokolit gibi bazı komplikasyonları vardır. Depo kanında bazı trombosit-lökosit hücre mikroagregatları gelişebilmektedir. Bu tür mikroagregat veya kan yıkım ürünlerinin, hayvanlarda pulmoner hemodinamik değişikliklere, insanlarda travma sonrası pulmoner yetmezliğe yol açabildiği saptanmıştır. Araştırmacılar, kan transfüzyonunu takiben meydana gelen pulmoner gaz değişimindeki değişikliklerin, pulmoner mikrovasküler yataktaki mikroagregatlar nedeniyle oluşan oklüzyon ve vazokonstriksiyona ikincil artan ölü alan ventilasyonuna bağlı geliştiğini belirtmektedirler. Bu yazıda, Rh izoimmunizasyonu ve hiperbilirübinemi nedeniyle tam volüm kan değişimi yapılan ve geçici pulmoner perfüzyon anomalili bir yenidoğan vakası sunuldu.

**Anahtar Kelimeler:** Yenidoğan; kan değişimi, tam kan; pulmoner difüzyon kapasitesi

Turkiye Klinikleri J Med Sci 2010;30(5):1712-5

The principal indications for exchange transfusion are hemolytic diseases of the newborn with hyperbilirubinemia. Exchange transfusion is sometimes employed for the treatment of disseminated intravascular coagulation or sepsis, although its efficacy in these conditions is controversial. In addition, exchange transfusion can be used to remove exogenous (i.e., drugs) or endogenous (i.e., metabolic) toxins. For this reason, in some situations exchange transfusion should be done; however, it may have some

potential complications such as infection, coagulopathies (i.e., thrombocytopenia), electrolyte abnormalities (i.e., hypocalcemia), metabolic acidosis, hypoglycemia, and necrotizing enterocolitis.<sup>1</sup> Furthermore, many experts have reported that pulmonary insufficiency and some changes in pulmonary hemodynamics may develop in man and animals after blood transfusion.<sup>2-4</sup> In addition, in some transfusion errors were reported. These errors were misidentification of blood bags, incorrect blood typing and failure to identify patient.<sup>5</sup> In this article, we reported, for the first time, a newborn with transient pulmonary perfusion abnormality who had massive exchange transfusion for Rh isoimmunization and hyperbilirubinemia.

## CASE REPORT

A male infant with 38 weeks of gestational age, born by Cesarean section from third pregnancy of a 30-year-old mother was admitted to our hospital because of Rh isoimmunization at postnatal first hour. We learned from the prenatal history of the mother that she had Rh isoimmunization; however, rhoGam was not administered. At birth, the infant was 3500 g (50th percentile), in weight and 48 cm in length (50th percentile), and his head circumference was 36 cm (50th percentile). On physical examination of the baby, jaundice, pallor, and hepatosplenomegaly (spleen and liver was 5 cm under the midclavicular line of the costa) were found. The other physical and neurologic examination findings were normal.

Laboratory findings included hemoglobin 8.3 g/dl, hematocrit of 28.5%, platelet count 87000/mm<sup>3</sup>, white blood cell (WBC) count 24900/mm<sup>3</sup>, total bilirubin (TB) 13.3 mg/dl, and direct bilirubin value 1.0 mg/dl within a few hours after birth. Peripheral red blood cell (RBC) smear of the patient showed nucleated RBCs, spherocytes and other fragmented cells. The baby's blood group was 0 Rh (+), direct antiglobulin test (DAT) was 4+ and his mother's blood group was B Rh (-). Other biochemical parameters such as liver and renal functions, and electrolytes of the baby were normal.

Exchange transfusion was performed with 0-Rh-negative and appropriate cross-matched blood

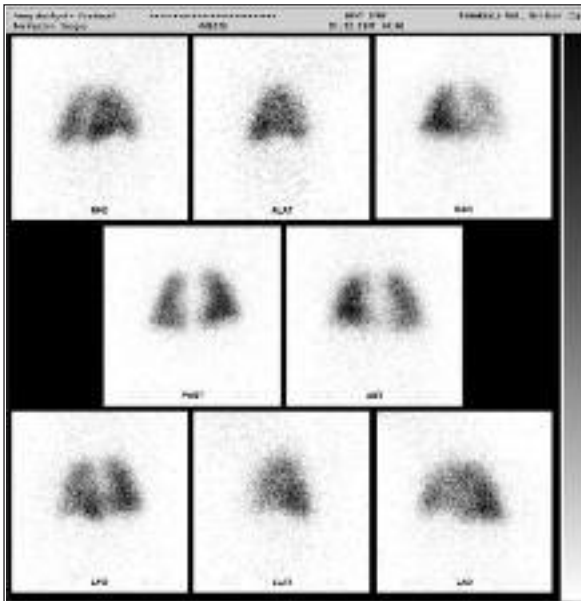
three times for Rh isoimmunization and hyperbilirubinemia on sixth (TB 13.3 mg/dl), ninth (TB 13.2 mg/dl) and 14th (TB 13.7 mg/dl) hours of postnatal life. In addition, phototherapy was initiated. At the end, bilirubin value reduced to normal level after a few days of phototherapy.

The patient had no pulmonary problems and his oxygen saturation was normal in the room air before the exchange transfusion; however, he had pulmonary problems such as dyspnea, tachypnea, retractions, cyanosis, and low oxygen saturation (<85%) a few hours after the last exchange transfusion. For that reason, we re-evaluated the patient. Chest radiography, acute phase reactants, blood culture and WBCs were normal. We determined that arterial blood gas sample was pH 7.10, PCO<sub>2</sub> 73 mmHg, PO<sub>2</sub> 56 mmHg, HCO<sub>3</sub> 18 mEq/L. Patient was intubated, observed for a few hours, and then, extubated and followed up with free oxygen in the incubator. The values of arterial blood gas sample returned to normal, however the patient remained dependent to oxygen for five days. On the 6th day of postnatal life, echocardiography was normal except for 1-2 mm patent foramen ovale. When pulmonary perfusion scintigraphy was performed with 0.3 mCi of Tc-99m macroaggregate (MAA) solution including 22,500 particles, we determined a prominently decreased activity accumulation in the posterior and anterior segments of the left pulmonary superior apical area when compared to the other segments of left pulmonary and the right pulmonary regions (Figure 1). After five days, the patient's pulmonary dysfunction recovered. After three weeks, pulmonary perfusion scintigraphy was repeated with Tc-99m MAA (0.5 mCi, 22,500 particles), and no abnormal finding were determined (Figure 2).

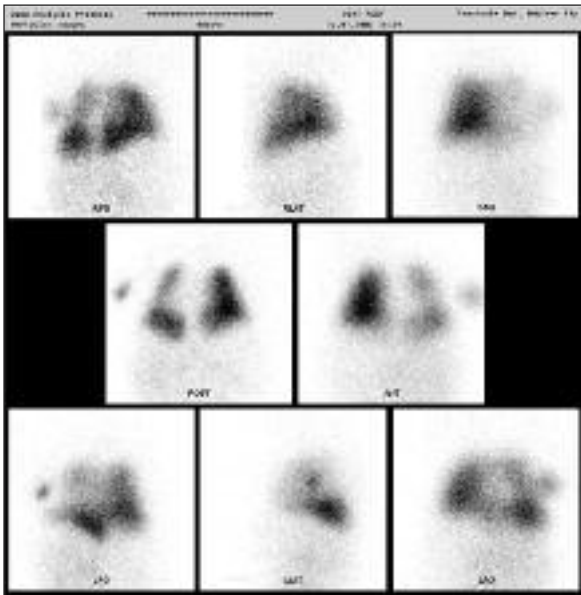
Consequently, we considered that a transient pulmonary dysfunction might develop due to the exchange transfusion.

## DISCUSSION

Some platelet-white cell microaggregates develop in stored blood. These microaggregates or blood debris have been found to produce changes in pulmonary hemodynamics in animals and have been



**FIGURE 1:** The pulmonary perfusion scintigraphy was performed after 0.3 mCi of Tc-99m MAA injection, decreased activity of accumulation was observed in the posterior and anterior segments of the left pulmonary superior apical region. The others segments of bilateral lungs showed normal radiopharmaceutical distribution.



**FIGURE 2:** After three weeks, pulmonary perfusion scintigraphy findings were normal.

implicated in post-traumatic pulmonary insufficiency in humans.<sup>2-4</sup> Marshal et al. demonstrated that pulmonary microemboli occurred in animals, more often when greater numbers of units of blood had been given.<sup>2</sup> Robinson et al. reported that pulmonary dysfunction with ventilation/perfusi-

on ratio distributions was determined.<sup>4</sup> They suggested that pulmonary gas exchange alterations following blood transfusion was primarily reflected by increased dead-space ventilation secondary to vasoconstriction and occlusion of the pulmonary microvasculature with microaggregates greater than 90 micrometers in diameter.<sup>4</sup> After last exchange transfusion, we determined a clinical constellation of signs and symptoms including dyspnea, tachypnea, retractions and cyanosis in patient. For that reason, we re-evaluated the patient. Chest radiography, WBCs, acute phase reactants and all of cultures (i.e, blood, urine, tracheal aspiration materials) of the patient for any infectious agents, and echocardiography were normal. We determined that the pulmonary perfusion scintigraphy with Tc-99m MAA of patient was impaired on postnatal fifth day. After three weeks, pulmonary perfusion scintigraphy was completely normal. The differential diagnosis of patients who present with acute lung injury after blood transfusion includes transfusion-related acute lung injury (TRALI), transfusion-associated cardiac/circulatory overload (TACO), cardiogenic edema, allergic and anaphylactic transfusion reactions and transfusion of bacterially contaminated blood components. Circulatory or cardiac overload can result from hypertransfusion (rapid or massive transfusion) to the patients at risk, namely the very young recipient, in whom fluid infusion overwhelms the capacity of the left ventricle, resulting in pulmonary oedema.<sup>6,7</sup> TRALI is an immune-mediated acute lung injury resulting from transfusion of plasma-containing products.<sup>8,9</sup> It is best described as clinically as dyspnea and bilateral pulmonary edema that usually develops during, or within six hours after blood transfusion. Radiological findings show bilateral pulmonary infiltrates consistent with pulmonary edema, and they tend to be more remarkable than the physical findings.<sup>6,7</sup> While TRALI is characterised by hypoxemia or clinical evidences of hypoxemia and bilateral infiltrates on chest radiography without evidence of left atrial hypertension, TACO is characterised by hypoxemia and bilateral infiltrates on chest radiography in the presence of clinically

evident left atrial hypertension.<sup>8,9</sup> In the presented patient, chest radiography and echocardiography were normal, therefore, we did not consider it as a TRALI or a TACO. Allergic and anaphylactic reactions produce respiratory distress as a result of bronchospasm or laryngeal edema, manifested by tachypnea, wheezing and cyanosis, and can occur after transfusion of very small volumes of blood components. Bacterial contamination manifests as fever, hypotension and it must be considered, especially in patients who have received platelets.<sup>6</sup> The clinical and laboratory findings of the presented patient were not considered it as an anaphylactic reaction or a bacterial contamination. Inappropriate blood component transfusion may in develop various occasions because of wrong spe-

cimen and patients, specimen exchange and mistake of ABO compatibility test. Although mistakes may occur in the blood transfusion service, about two-thirds of errors are associated with incorrect blood recipient identification at the patient's bedside.<sup>5,10</sup> Exchange transfusion was performed with 0-Rh-negative and appropriate cross-matched blood. Therefore, we concluded that the condition of the patient was a transient pulmonary dysfunction resulting from occlusion of the pulmonary microvasculature with microaggregates due to the massive exchange transfusion.

In conclusion, transient pulmonary perfusion abnormality is an early complication of exchange transfusion and it may develop in newborns who had massive exchange transfusion.

## REFERENCES

1. Luchtman-Jones L, Schwartz AL, Wilson DB. Blood component therapy for the neonate. In: Fanaroff AA, Martin RJ, eds. Neonatal-Perinatal Medicine Diseases of the Fetus and Infant. 7<sup>th</sup> ed. Philadelphia: Mosby; 2002. p.1239-54.
2. Rosario MD, Rumsey EW, Arakaki G, Tanoue RE, McDanal J, McNamara JJ. Blood microaggregates and ultrafilters. *J Trauma* 1978;18(7):498-506.
3. Brown C, Dhurandhar HN, Barrett J, Litwin MS. Progression and resolution of changes in pulmonary function and structure due to pulmonary microembolism and blood transfusion. *Ann Surg* 1977;185(1):92-9.
4. Robinson NB, Heimbach DM, Reynolds LO, Pavlin E, Durtschi MB, Riem M, et al. Ventilation and perfusion alterations following homologous blood transfusion. *Surgery* 1982;92(2):183-91.
5. Murakami J. [Present state of transfusion errors]. *Rinsho Byori* 2003;51(1):43-9.
6. Bux J. Transfusion-related acute lung injury (TRALI): a serious adverse event of blood transfusion. *Vox Sang* 2005;89(1):1-10.
7. Haji AG, Sharma S, Vijaykumar DK, Paul J. Transfusion related acute lung injury presenting with acute dyspnoea: a case report. *J Med Case Reports* 2008;2:336.
8. Roberts GH. Transfusion-related acute lung injury (TRALI). *Clin Lab Sci* 2004;17(3):133-5.
9. Rana R, Fernández-Pérez ER, Khan SA, Rana S, Winters JL, Lesnick TG, et al. Transfusion-related acute lung injury and pulmonary edema in critically ill patients: a retrospective study. *Transfusion* 2006;46(9):1478-83.
10. Pagliaro P, Rebulli P. Transfusion recipient identification. *Vox Sang* 2006;91(2):97-101.