

# Tissue expansion in pediatric patients: A report of 44 patients

Figen ÖZGÜR, Oya KOCABALKAN, Emin MAVİLİ, Yücel ERK, K Güler GÜRSU.

Department of Plastic and Reconstructive Surgery, Hacettepe University Medical School, Ankara-TURKEY

*Tissue expanders were used in reconstruction of various deformities of 44 pediatric patients between 1988-1992 at Hacettepe University Plastic and Reconstructive Surgery Department. Deformities of 36 of these 44 patients were due to burn scars and 8 were due to congenital deformities. Total of 62 expanders were placed for 44 patients. We have observed complications in 7 patients, 5 of the complicated expanders had to be removed before reaching desired expansion volume. Complications of tissue expansion were hematoma formation, infection, skin necrosis and exposure of the Implant secondary to trauma. Clinical experience with tissue expansion in children proved to be a well tolerated and a valuable reconstruction method. [Turk J MedRes 1993; 11 (3): 146-150]*

Key Words: Tissue expander, Reconstruction

Tissue expansion is a well accepted treatment modality in reconstruction problems by inadequate skin or soft tissue. The optimal coverage or replacement for soft tissue defects should be similar to local tissue in color, texture, hair-bearing properties and volume. Tissue expansion can offer a well suited solution for otherwise a difficult reconstruction problem in appropriately selected and planned pediatric cases and meets these criteria. Review of the English literature reveals only a few series concerning the use of tissue expanders in the pediatric population (1-4). In this paper we have reviewed our clinical experience in 44 pediatric patients whom we have used tissue expanders as the method in reconstruction of various deformities.

## MATERIALS AND METHODS

Between 1988-1992 we have used tissue expansion method for 44 children in our clinic with skin or soft tissue defects and pathologies. Deformities mostly were due to burn scars of the hair bearing areas. Our youngest patient was 23 months old, and the oldest 16 years old. In 28 patients only one tissue expander

was used, in 15 patients two, and one patient four expanders were used to expand the skin. Total of 62 tissue expanders were used (Table f).

Tissue expanders were placed in various sites. For scalp, expanders were placed beneath the galea aponeurotica. In other localizations subcutaneous pockets were created for expanders. Tissue expanders were placed under general anesthesia. No drains were used. Tissue expanders were inflated with 10-50 cc. of saline intra operatively, depending on the site, to fill the dead space created by dissection. Antibiotic prophylaxis was used routinely with first generation cephalosporins for 7 days. All patients were hospitalized for at least postoperative two days. One third of

Table.1. Localization and definition of the deformities

Localization patients	DEFORMITIES	
	Definition	Number of
Scalp	Scatricial alopecia	22
	Hemangioma	2
Face	Burn scar	2
	Congenital hairy nevus	1
	Neurofibromatosis	1
Forehead	Congenital hairy nevus	1
Ear	Microtia	2
Trunk	Burn scar	10
	Congenital giant nevus	1
Popliteal region	Burn contracture	2
Total		44

Received: Jan. 28, 1993

Accepted: April 6, 1993

Correspondence: Figen ÖZGÜR

Dept. of Plastic and Reconstructive  
Surgery, Medical School of Hacettepe  
University 06100, Ankara, TURKEY

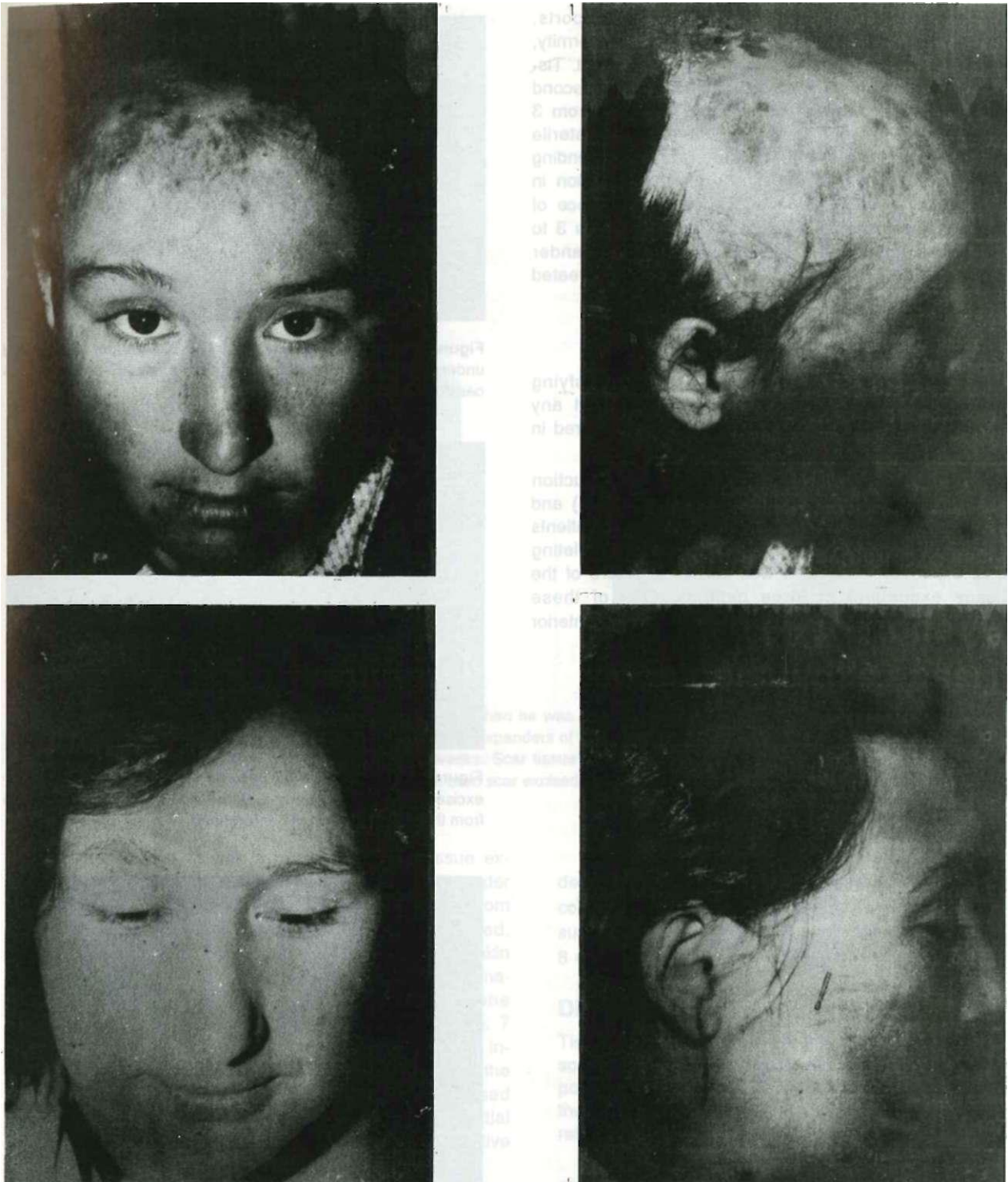

Figure 1. 15 years old girl was burned when she was 1 years old. Her right temporal and fronto-parietal region was burned in third degree. She has only received conservative treatment with dressing changes at the village health house. (A-B) 15x18 cm area of alopecia at her fronto-parietal and right temporal scalp region. Two rectangular tissue expanders of 300 cc and 350 cc were placed beneath the occipital region under the galea aponeurotica. Expansion was started on the second week and continued for 8 week. In the first operation occipital transposition flap on the left side and advancement flap on the right side were designed. Donor defect of the transposition flap was covered with full-thickness, skin graft from her right inguinal region. 9 months later 100 cc and 250 cc rectangular tissue expanders were placed beneath the transposed flap and priorly expanded skin over occipital region. Expansion was completed in 6 weeks, the graft and the hairless region were excised totally. (C-D) Two years after reconstruction.

the expanders had self contained injection ports. Depending on the size and localization of deformity, various size and shapes of expanders were used. Tissue expansion started on postoperative first or second week. Intervals between two inflation changed from 3 to 10 days. In each inflation 5 to 40 ml of sterile saline was injected into the tissue expander depending on the size of the expander and its site. Decision in how much to inflate depended on the appearance of the over the expander. Total expansion time was 3 to 12 weeks (mean time 7 weeks). As the expander removed, rotation or advancement flaps were created for the necessary reconstruction.

**RESULTS**

We have treated 37 patients with very satisfying results using tissue expansion method without any complications. Three of these patients were pictured in Figures 1,2 and 3.

The overall complication rate in reconstruction using tissue expansion was 7 in 44 cases (16%) and 7 in 62 expanders (11 %) in our series. In five patients 8 expanders had to be removed before completing total expansion volume. It was due to exposure of the tissue expanders in three patients. One of these patients had a giant congenital nevus of the anterior

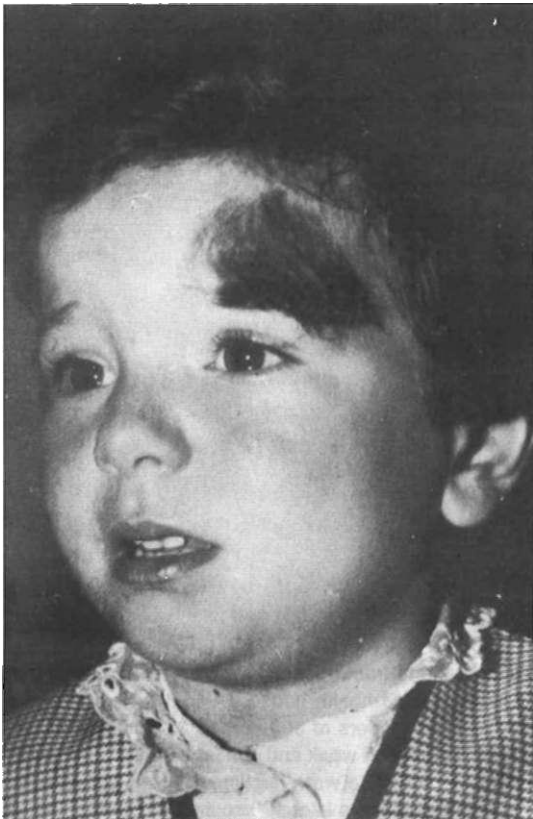

Figure 2. (A) 3 years old girl with a hairy nevus on her forehead of 5x6 cm.

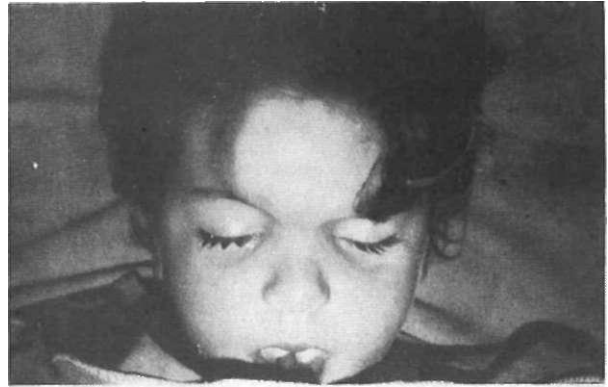

Figure 2. (B) 100 cc of rectangular tissue expander was placed under her right forehead galea aponeurotica. Expansion successfully completed in 18 days.

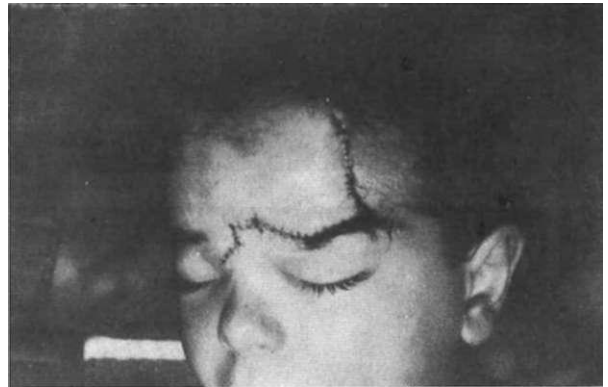

Figure 2. (C) Hairy nevus over her left eyebrow was totally excised and the defect was covered with an advancement flap from the expanded skin of her forehead.

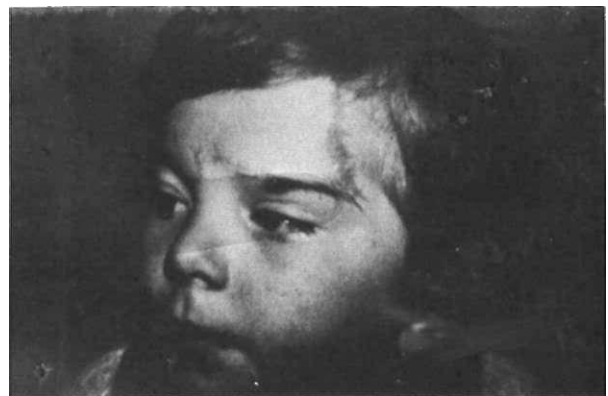

Figure 2. (D) 6 months after surgery.

trunk. The child was 3 years of age and there were 4 expanders on both flanks. The expander on the right flank was exposed from the incision 6 weeks after insertion of expander after trauma. All four expanders had to be removed and nevus was partially excised.

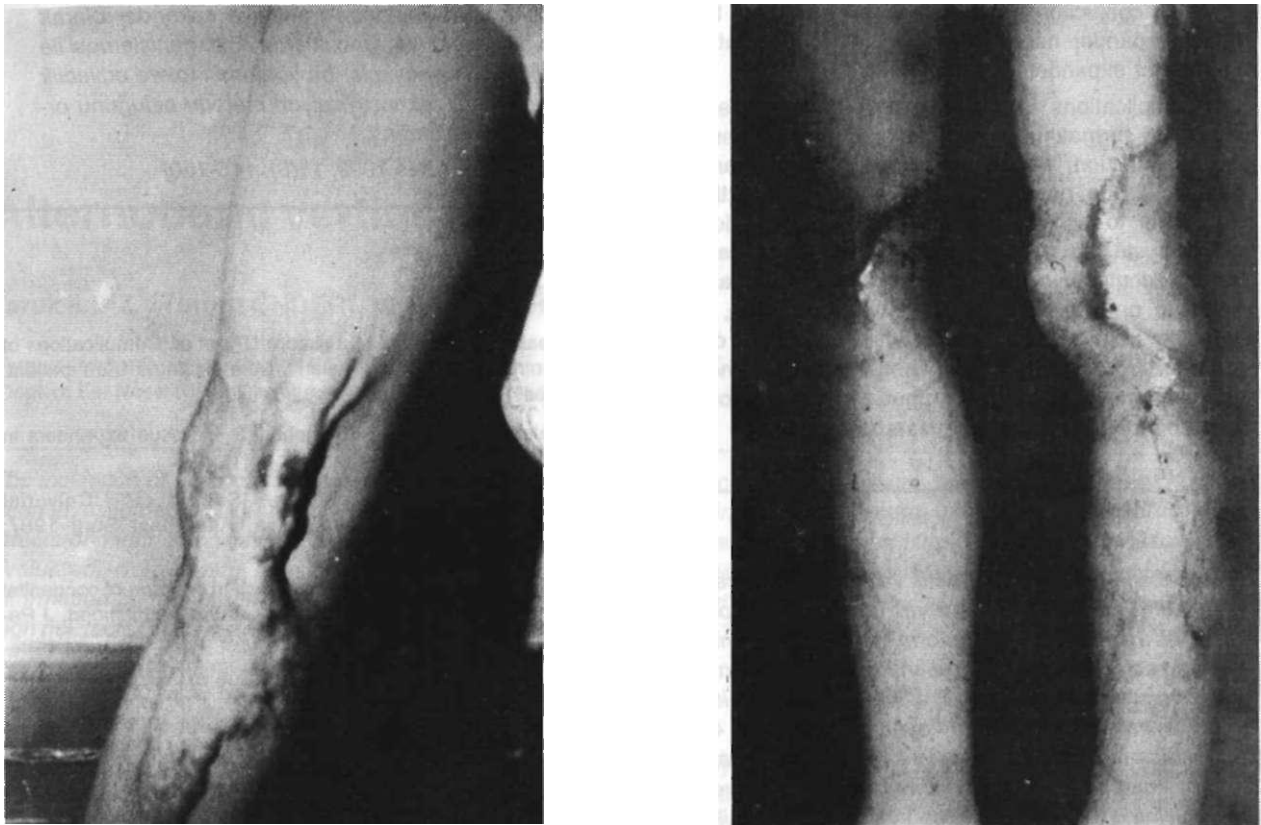


Figure 3. A) 6 years old boy was burned with hot water when he was 3 years old. He had a hypertrophied scar of 25x9 cm and a flexion contracture on his left posterolateral knee. Two oval expanders of 300 cc and 310 cc were under the subcutaneous tissue of his posterior thigh calf. Expansion was completed in six weeks. Scar tissue was excised with a "lazy S" incision. (B) 6 months after the reconstruction. Incision seen on the right knee is due to burn scar excised and closed primarily. He still had a hypertrophied scar of both incisions and was given pressure garments.

The second patient was a microtia case. A tissue expander was placed beneath the mastoid skin in order to reconstruct the ear. The expander extruded from the skin 4 after insertion. Expander was removed, necrotic area excised. The remaining expanded skin was sufficient to reconstruct the ear. Hematoma formation was observed 3 days after insertion in one patient. Hematoma was evacuated through incision. 7 days after the drainage expander extruded from the incision. Expansion process was not interrupted until the fourth week. As the expansion progressed exposed area increased. Expander was removed and partial reconstruction with excision was done in postoperative fourth week.

We have seen hematoma formation in two patients, hematoma was drained and expansion progressed without further complication.

Expanders had to be removed before reaching planned volume because of infection in two patients with expanders which were both placed under scalp. *Staphylococcus aureus* was isolated from expander sites.

Despite an uncomplicated expansion up to desired volume expanded skin was not sufficient to cover the surgical defect created in two patients. Tissue expansion was used for both these patients 6 and 8 months after the first expansion.

## DISCUSSION

Tissue expanders can be used in reconstruction of scalp, face, trunk, and extremity soft tissue in pediatric population. There is no absolute contraindication to their use. Only unreliable home environment may be a relative contraindication (2).

Our clinical observation in tissue expansion in children proved this method to be well tolerated by children. The only painful step was inflation of the expander, besides there was no intolerable pain necessitated the removal of the expander.

Either advancement or transposition flaps and sometimes both can be used to cover the defect. Design of these flaps should be made prior to placement of tissue expander to define the best localization for the expander (5).

In every location large expanders should be chosen in conjunction with a simple clinical guide to the size of expander necessary, the "two to one ratio for the base of expander" is recommended.

Complications of tissue expansion are infection, hematoma formation, exposure of the expander, implant malfunction, wound separation during expansion, pain and tissue necrosis (6,7). Pediatric population is also prone to all of these complications. In addition, trauma sustained by the patient to the expander site may contribute to occurrence of complications as observed in one of our patients. Home accidents, such as falling from a chair, may cause exposition of the expander from the incision. Therefore importance of the guardiance should be emphasized when informing the parents about the tissue expansion method.

Pediatric hastalarda doku genişlemesi:  
44 hastanın incelenmesi

*Hacettepe Üniversitesi plastik ve rekonstrüktif cerrahi bölümünde 1988-1992 yılları arasında 44 pediatrik hastada çeşitli deformitelerin düzeltilmesinde doku genişleticiler kullanıldı. Bu 44 hastanın 36'sının deformitesi yanık, 8'inin deformitesi ise konjenital bozukluklardan kaynaklanmaktaydı. 44 hastada toplam 62 genişletici kullanıldı. Yedi hastada komplikasyon gözlemlendi. Bunlardan 57 istenen genişleme volumüne ulaşmadan önce genişleticilerin çıkartılmasına bağlı idi. Doku genişleme kompli-*

*asyonları; hematoma oluşması, enfeksiyon, doku nekrozu ve implantın travmaya sekonder olarak açığa çıkmasıdır. Çocuklarda doku genişlemesi ile ilgili klinik deneyimler bu yöntemin tolere edilebilir kıymetli bir rekonstrüksiyon metodu olduğunu ortaya koymaktadır.*

[TurkJMedRes 1993; 11(3): 146-150]

## REFERENCES

1. Neale H W, High R M, Billmore DA, et al. Complications of controlled tissue expansion in the pediatric burn patient. *Plast Reconstr Surg* 1988; 82(5):840-5.
2. Paletta C, Campbell E, Shehadi S I. Tissue expanders in children. *J Pediatr Surg* 1991; 26(1):22-5.
3. Hemmer KM, Marsh JL, Selwyn P. Calvarial erosion after scalp expansion. *Ann Plast Surg* 1987; 19:454.
4. Bauer B S, Vicari A F. An approach to excision of congenital giant pigmented nevi in infancy and early childhood. *J Pediatr Surg* 1988; 23:509.
5. Austad E D. Complications in tissue expansion. *Clin Plast Surg* 1987; 14:549-50.
6. Joss G S, Zoltie N, Chapman P. Tissue expansion technique and the transposition flap. *Br J Plast Surg* 1990; 43:328-33.
7. Wiss K. Lasers, tissue expansion and sun protection in pediatric dermatology. *Cutis* 1990; 45: 331-34.