

Priapism Secondary to Penile Metastasis of Bladder Carcinoma: A Case Report and Review of the Literature

Mesane Kanserinin Penise Metastazına Sekonder Priyapizm

Sinan EKİCİ, MD,^a
Orhun SİNANOĞLU, MD,^a
Işın DOĞAN EKİCİ, MD^b

^aDepartment of Urology,
Maltepe University Faculty of Medicine,
^bDepartment of Patology,
Yeditepe University Faculty of Medicine,
İstanbul

Geliş Tarihi/Received: 30.04.2010
Kabul Tarihi/Accepted: 19.10.2010

Yazışma Adresi/Correspondence:
Orhun SİNANOĞLU, MD
Maltepe University Faculty of Medicine,
Department of Urology, İstanbul,
TÜRKİYE/TURKEY
orhundur@hotmail.com

ABSTRACT Malignant priapism is an uncommon clinicopathologic entity. It is indicative of a poor prognosis with very low survival rates. In this article diagnostic and treatment approaches of penile secondary malignancies are discussed accompanied with a presented case. Although a variety of treatment approaches are available, cavernosal decompression was performed on the reported case for pain palliation and histopathological evaluation of the cavernosal tissue yielded metastatic urothelial carcinoma. Magnetic resonance imaging also confirmed a metastatic infiltration to the corpora cavernosa. Our case has an exceptionally aggressive clinical course after appearance of malignant priapism in paralel to the reported cases in the literature.

Key Words: Neoplasm metastasis; priapism; urinary bladder neoplasms

ÖZET Malign priyapizm, nadir görülen klinikopatolojik bir durumdur. Oldukça kötü bir prognoz ve düşük sağkalım oranının göstergesidir. Bu makalede, mesane kanserinin primer tümörünün penise metastazını bildirdiğimiz bir olgu ile literatürdeki benzer olguların teşhis ve tedavi yaklaşımları tartışılmaktadır. Sekonder penil metastazlarda muhtelif tedavi yaklaşımları olmakla beraber burada sunulan hastada kavernöz dekompresyon yapılmıştır, elde edilen kavernöz doku histopatolojik inceleme metastatik ürotelyal karsinomuna ortaya çıkarmıştır. Manyetik rezonans inceleme de kavernöz cisimlere metastatik yayılımı doğrulamıştır. Bildirilen olguda malign priyapizm ortaya çıkmasından sonra literatürdekilere paralel olarak son derece agresif bir seyir izlenmiştir.

Anahtar Kelimeler: Tümör metastazı; priyapizm; mesane tümörleri

Türkiye Klinikleri J Urology 2010;1(3):83-6

Priapism is prolonged and painful erection without sexual stimulation. There are two major types of priapism: low-flow priapism due to venous occlusion and high-flow priapism due to uncontrolled arterial flow to the veins. High-flow priapism most frequently occurs as a result of penile trauma in which the intercavernosal artery disruption causes an arteriocavernosal fistula. Malignant priapism represents a type of low flow ischemic priapism. Priapism due to metastatic neoplasms is very rare, representing 3-8% of all cases of priapism.¹ Metastatic tumors of the penis are also rare despite an abundant blood supply to the penis.

The corpus cavernosum is usually the site of involvement of metastatic penile carcinoma. The glans penis and corpus spongiosum are involved

rarely.² Seventy-seven percent of metastasis is originated from pelvic region and prostate and bladder is the most frequent primary location.³

Herein, we report a patient died of brain metastasis due to urothelial carcinoma of the bladder that developed very soon following malignant priapism without any other organ metastasis, and make a brief review of the literature

CASE REPORT

A 60-year-old male was presented to our clinic with persistent painful erection for 3 days. His medical history revealed muscle invasive high grade urothelial carcinoma (pT2G3) diagnosed 5 months ago. The patient had undergone systemic chemotherapy including cisplatin and gemcitabine. Then, due to the toxicity of chemotherapy, his management had been shifted to radiotherapy. However, painful priapism had ensued at 29th day of the radiotherapy. The patient was presented to our clinic 4 days later. Our physical examination revealed that both the corpora cavernosa were engorged and painful to palpation without any local lesion. Pain relief was accomplished with intramuscular administration of 50 mg pethidine and 75 mg diclofenac sodium. He was inserted urethral catheter because of inability to urinate. Digital rectal examination revealed a medium-sized prostate gland hard in consistency. His mental status was good. Cavernosal blood gas analysis revealed tissue ischemia indicating ischemic priapism. Cavernosal irrigation with diluted adrenalin injection and corporoglandular shunt were not successful. Thoracoabdominal tomography showed no major organ metastases. Pelvic magnetic resonance imaging (MRI) including penis showed a 3 cm vegetative tumoral lesion with irregular contour on the trigone extending to the right lateral wall of bladder. The lesion, 114 x 64 x 68 mm in size, was infiltrating the prostate and crossing the perineal membrane with extension into the distal corpora cavernosa (Figure 1). Penile skin, glans penis, corpus spongiosum and mid/distal corpora cavernosa were intact. Since ischemic priapism of a long duration implies a compartment syndrome, decompression of the corpora cavernosa was performed

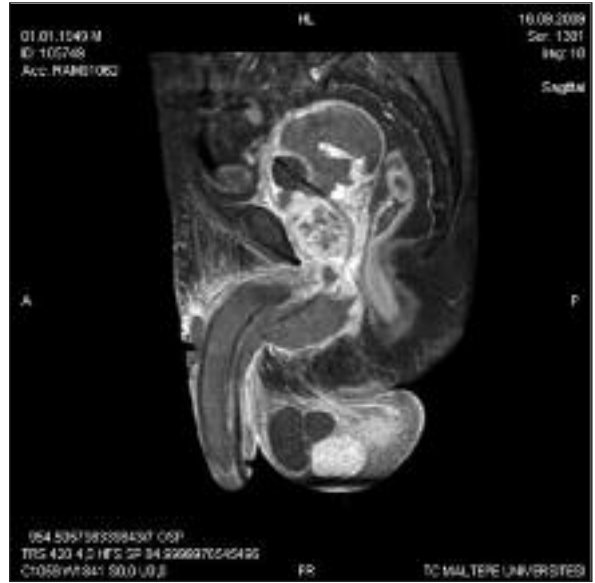

FIGURE 1: Magnetic resonance imaging demonstrates the mass in urinary bladder and accompanying metastatic mass infiltrating distal corpora cavernosa and perineum.

to relieve the ischemic effects. Corporal bodies were incised longitudinally and coagulated blood, hyperviscous and necrotic tissues were evacuated from the cavernosal bodies. Excisional biopsies from the cavernosa showed a poorly differentiated, mostly necrotic neoplasm which was positive with cytokeratin-7 immunohistochemically, consistent with metastatic high grade urothelial carcinoma (Figures 2 and 3). His penile pain was recovered slightly and palliative radiotherapy was offered. However, his general health status worsened and his speech blurred within a week, and cranial computed tomography revealed brain metastasis. He died 2 weeks later.

DISCUSSION

Malignant priapism is relatively infrequent. It can be mostly caused by bladder, prostate, kidney, gastrointestinal tract, testis, lung, liver, bone and sarcoma.⁴⁻⁷ The earliest report of secondary penile malignancy was published in 1870, which reported metastasis from an adenocarcinoma of the rectum.⁸ First penile metastasis from a primary genitourinary neoplasm was reported two years later. In a review of 372 penile metastasis cases presented by Cherian et al in 2006, primary tumor localization was prostate, bladder, recto-sigmoid and rectum,

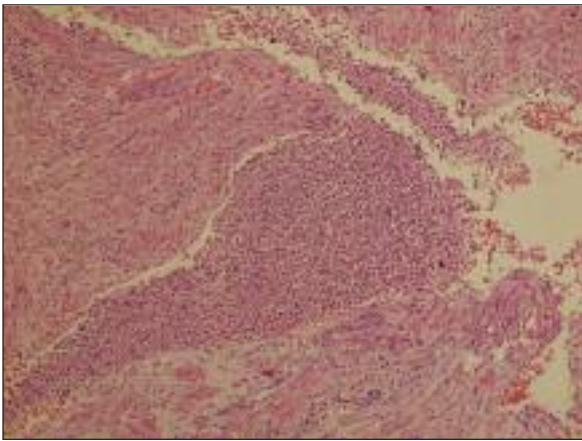


FIGURE 2: The pathologic examination of the biopsy specimen from the corpora cavernosa revealed mostly necrotic poorly differentiated neoplasm (Hematoxylen and eosin, x100).

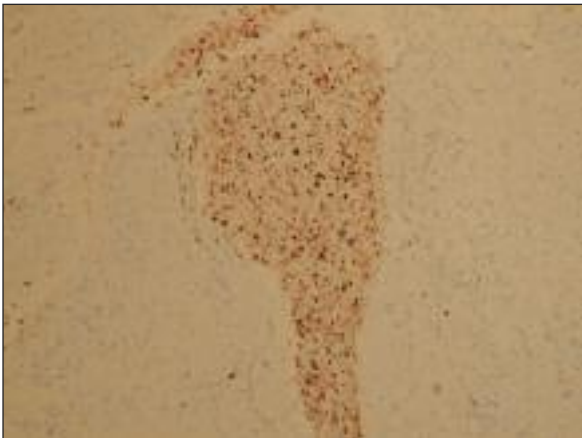

FIGURE 3: Immunohistochemical examination showed cytokeratin-7 positive staining consistent with high grade urothelial carcinoma metastatis (Cytokeratin-7, x 100).

and kidney in 34, 30, 13, 8 percent of the cases respectively.⁹ In a recent study which reported clinicopathologic and outcome features of 17 patients with metastatic tumor to the penis primary sites and histological types are as follows: 6 urothelial carcinomas of urinary bladder, 4 prostatic carcinomas (2 adenocarcinomas and 2 adenosquamous carcinomas), 2 colorectal adenocarcinomas, 2 pulmonary carcinomas (1 squamous cell carcinoma and 1 small cell carcinoma), 1 squamous cell carcinoma of base of the tongue, 1 cutaneous malignant melanoma, and 1 acute myeloid leukemia. Most of

the patients presented with a penile mass.¹⁰ Priapism was observed in 4 patients. Symptoms of secondary penile neoplasms other than painful priapism, are mostly penile induration, or nodules over the penis, difficulties in voiding and perineal pain. Sonmez et al in 2009 reported a patient who underwent radical cystoprostatectomy and bilateral pelvic node dissection with an ileal conduit diversion. Six months after cystectomy, their patient presented with priapism, pain, and urethral discharge.¹¹ In contrast to priapism, erectile dysfunction due to penile metastasis of small cell lung cancer is recently reported isolated case in the literature.¹²

Forty percent of penile metastases are manifested with priapism. Diagnosis is usually made by biopsy or corporeal aspiration, which helps to differentiate between metastasis and primary tumours. Initial diagnostic tools can be radiological modalities, including penile doppler ultrasonography, computed tomography and MRI.^{5,11-13}

The management of malignant priapism is controversial. Treatment modalities are mainly palliative and largely depend on prognostic features of the primary tumor, extent of metastatic spread and general condition of the patient. Metastatic lesions of the penis can be treated surgically with excision of the lesion, partial or total penectomy, chemotherapy, radiotherapy or conservative management.^{9,10} The average survival in patients with penile metastasis was reported as 3.9 months from diagnosis and, with extensive therapy, a survival ranging from 3 to 24 months.^{1,9-11} Therefore, conservative treatment can be a reasonable choice. In our case, we performed surgical corporal decompression with the aim of pain palliation. However, offered radiotherapy was not able to be given due to aggressive progression of his brain metastasis.

Consistent with the reported cases, priapism due to malignant causes can be a clinical prognostic marker for widespread metastases with poor prognosis.^{6,10,14,15} Malignant priapism develops due to neoplastic infiltration of the corpora cavernosa leading to obstruction of the corpora or penile venous flow, or irritation of the neural pathways.^{1,3,9} Although the penis has rich vascularity with end

arterial nature, frequency of metastases to the penis is less than expected. Plausible route(s) of metastases from primary pelvic organ malignancies to the penis were proposed as direct extension, retrograde pelvic venous flow, retrograde lymphatic flow and arterial embolism.^{3,4,16} However when metastasis occurs, this rich blood supply renders penis a take off point for metastases to the vital organs.

In conclusion, secondary malignancy of the penis is an uncommon clinical entity. The rarity of these lesions and variable clinical presentation ne-

cessitate a good knowledge of this condition to plan appropriate treatment in these patients. The overall outcome is very poor and most patients will need only palliative or supportive care. Our patient had the tumoral invasion in the penis and perineum. The striking clinical picture was development of clinically overt brain metastasis with absence of other major organ metastases following priapism and death of the patient very soon. The presented case was also one of the exceptional examples reported in the literature that showed rapid and aggressive clinical course after appearance of malignant priapism.

REFERENCES

1. Celma Domènech A, Planas Morin J, de Torres Ramirez I, Bestard Vallejo J, Mir Maresma C, Morote Robles J. [Priapism secondary to penis infiltration of bladder cancer]. *Actas Urol Esp* 2009;33(3):327-9.
2. Park JC, Lee WH, Kang MK, Park SY. Priapism secondary to penile metastasis of rectal cancer. *World J Gastroenterol* 2009;15(33):4209-11.
3. Guvel S, Kilinc F, Torun D, Egilmez T, Ozkardes H. Malignant priapism secondary to bladder cancer. *J Androl* 2003;24(4):499-500.
4. Berger AP, Rogatsch H, Hoeltl L, Steiner H, Bartsch G, Hobisch A. Late penile metastasis from primary bladder carcinoma. *Urology* 2003;62(1):145.
5. Andresen R, Wegner HE, Dieberg S. Penile metastasis of sigmoid carcinoma: comparative analysis of different imaging modalities. *Br J Urol* 1997;79(3):477-8.
6. Valadez RA, Wheeler JS Jr, Canning JR, Moylan DJ. Metastatic transitional cell carcinoma to penis. *Urology* 1987;29(4):394-7.
7. Krco MJ, Jacobs SC, Lawson RK. Priapism due to solid malignancy. *Urology* 1984;23(3):264-6.
8. Eberth CJ. Krebsmetastasen des corpus cavernosum penis. *Virch Arch* 1870;51:145.
9. Cherian J, Rajan S, Thwaini A, Elmasry Y, Shah T, Puri R. Secondary penile tumours revisited. *Int Semin Surg Oncol* 2006;3:33. doi: 10.1186/1477-7800-3-33.
10. Chaux A, Amin M, Cubilla AL, Young R. Metastatic Tumors to the Penis: A Report of 17 Cases and Review of the Literature. *Int J Surg Pathol* 2010;22(3):281-99.
11. Sönmez NC, Coşkun B, Arisan S, Güney S, Dalkiliç A. Early penile metastasis from primary bladder cancer as the first systemic manifestation: a case report. *Cases J* 2009;2:7281.
12. Haliloglu AH, Haliloglu N, Akpınar EE, Ataoglu O. Erectile dysfunction: initial symptom of a patient with lung cancer. *J Sex Med* 2009 Aug 11. doi:10.1111/j.1743-6109.2009.01431.
13. Dubocq FM, Tefilli MV, Grignon DJ, Pontes JE, Dhabuwala CB. High flow malignant priapism with isolated metastasis to the corpora cavernosa. *Urology* 1998;51(2):324-6.
14. Bordeau KP, Lynch DF. Transitional cell carcinoma of the bladder metastatic to the penis. *Urology* 2004;63(5):981-3.
15. Khan MA, Tao W, Mathews P, Potluri BS. Penile metastasis arising from transitional cell carcinoma of the urinary bladder. *Urol Int* 2001;66(3):162-3.
16. Paquin AJ Jr, Roland SI. Secondary carcinoma of the penis; a review of the literature and a report of nine new cases. *Cancer* 1956;9(3):626-32.