

A Rare Cause of Sympathetic Ophthalmia: Combined Penetrating Keratoplasty and Pupilloplasty

- ① Baran KANDEMİR,^a
- ① Nesrin TUTAŞ GÜNAYDIN,^a
- ① Burak TANYILDIZ,^a
- ① Güzide AKÇAY,^a
- ① Eren GÖKTAŞ^a

^aClinic of Ophthalmology,
Dr.Lütfi Kırdar Kartal Training and
Research Hospital,
İstanbul

Received: 01.01.2018
Received in revised form: 10.04.2018
Accepted: 10.04.2018
Available online: 17.09.2018

Correspondence:
Nesrin TUTAŞ GÜNAYDIN
Dr.Lütfi Kırdar Kartal Training and
Research Hospital,
Clinic of Ophthalmology,
İstanbul, TURKEY
drnesrintutas@hotmail.com

ABSTRACT A 60-year-old male patient was referred to our clinic with the diagnosis of corneal staphyloma secondary to keratitis in the left eye. Penetrating keratoplasty (PK) and pupilloplasty were performed and one month after the intervention, the patient was admitted to our clinic with decreased vision in his right eye. Based on clinical findings, Fundus Fluorescein Angiography (FFA), and optical coherence tomography (OCT) results, he was diagnosed with sympathetic ophthalmia (SO) secondary to combined keratoplasty and pupilloplasty. The patient was treated with topical and systemic corticosteroids with immunosuppressive drugs. To the best of our knowledge, this is the first case of SO, on the basis of combined PK and pupilloplasty performed in a patient with acquired anterior staphyloma secondary to keratitis.

Keywords: Sympathetic ophthalmia; penetrating keratoplasty; pupilloplasty

Sympathetic ophthalmia (SO) is a rare, bilateral, recurrent, non-necrotizing granulomatous panuveitis which develops following an ocular injury or surgery. T-cell autoimmune inflammatory responses to uveal, retinal, and retinal pigment epithelial antigens are considered to play a role in the pathogenesis of SO. The incidence of SO has been reported between 0.2 and 0.5% after a penetrating ocular trauma and 0.01% after intraocular surgery in the literature.¹ To the best of our knowledge, there were two cases previously published describing SO following PK for fungal keratitis.^{2,3} Herein, we report the first case of SO following combined PK and pupilloplasty who was diagnosed with acquired anterior staphyloma secondary to keratitis.

CASE REPORT

A 60-year-old male patient was referred to our clinic with the diagnosis of corneal staphyloma secondary to keratitis with no history of trauma in his left eye (LE). On ophthalmological examination, the best corrected visual acuities (BCVA) were 0.5 logMAR in the right eye (RE) and light perception in the LE. There was corneal thinning with an entrapped iris within (pseudocorneal formation) and corneal protrusion in the LE (Figure 1A). The iris was adhered to the cornea. Neither lens nor fundus was able to be

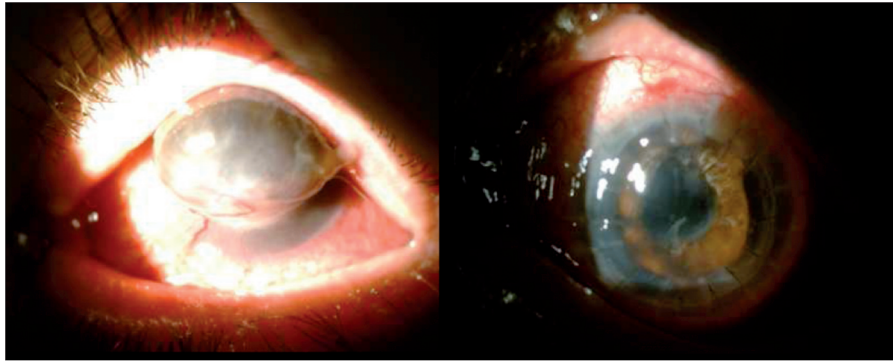


FIGURE 1: A) Preoperative anterior biomicroscopy of the left eye, B) Clear graft after penetrating keratoplasty.

evaluated. The anterior segment findings were normal for RE. PK was planned for the LE.

During keratoplasty surgery, fibrotic membrane formation was observed above the lens, which was adhered to the iris and cornea. After dissection of adhesions, the lens was extracted and pupilloplasty was performed following anterior vitrectomy. On Day 1 following surgery, the best corrected visual acuity (BCVA) was 1.3 logMAR in the LE with +11.0 Diopter (D), and the graft was clear (Figure 1 B). At one month following surgery, the patient presented with a complaint of decreased vision in the RE. The BCVA were 0.5 logMAR for the RE and 1.3 logMAR for the LE. Biomicroscopic examination of the RE revealed Koeppe's nodules, 0.5+ cells in the anterior chamber, and vitreous haze. The graft was clear with minimal anterior chamber reaction in the LE. Funduscopic examination (FFA) of the RE demonstrated optic disc edema, intra-retinal edema, and multifocal yellow-white subretinal lesions (Figure 2A). The fundus of the LE was normal. Spectral-domain-OCT (Optos

SD-OCT, Scotland, UK) of the RE demonstrated retinal pigment epithelium (RPE) irregularities, intra-retinal fluid, and multi-lobular detachment of the neurosensory retina (Figure 2 B). The laboratory analysis excluded other potential etiologies of granulomatous panuveitis. Two weeks later, visual acuity of the RE decreased to hand motion with no anterior segment findings. Fundus examination showed optic disc and macular edema with three quadrant serous retinal detachment in the periphery of the RE (Figure 3 A, B, C, D). FFA demonstrated multiple hyperfluorescent spots in the RPE (pinpoint view) with more significant sub-retinal leakage in the late phase (Figure 3E). Based on the clinical and laboratory findings, the patient was diagnosed with SO secondary to combined keratoplasty, particularly iris excision, and pupilloplasty. The patient was treated with intravenous methylprednisolone (Prednol-L[®]) 1 g daily for three days, followed by oral prednisolone 1 mg/kg/day, azathioprine 100 mg (Imuran[®] tablet 50 mg, bid), cyclosporine 200 mg (Sandimmune[®]

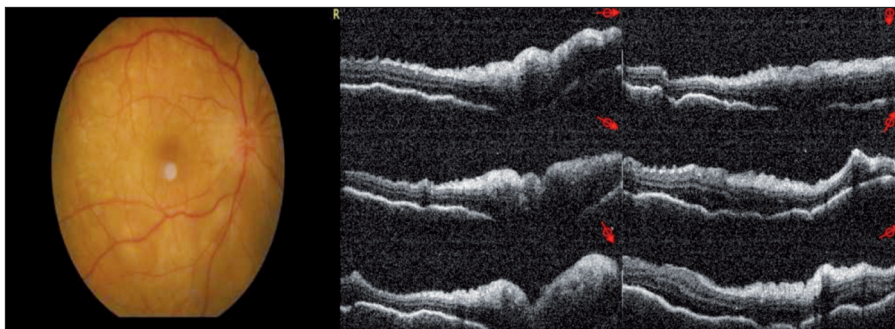


FIGURE 2: A) The funduscopy of the right eye: OD edema, multifocal subretinal deep yellow-white lesions, B) OCT of the right eye: Multilobular retinal detachment, RPE irregularity.

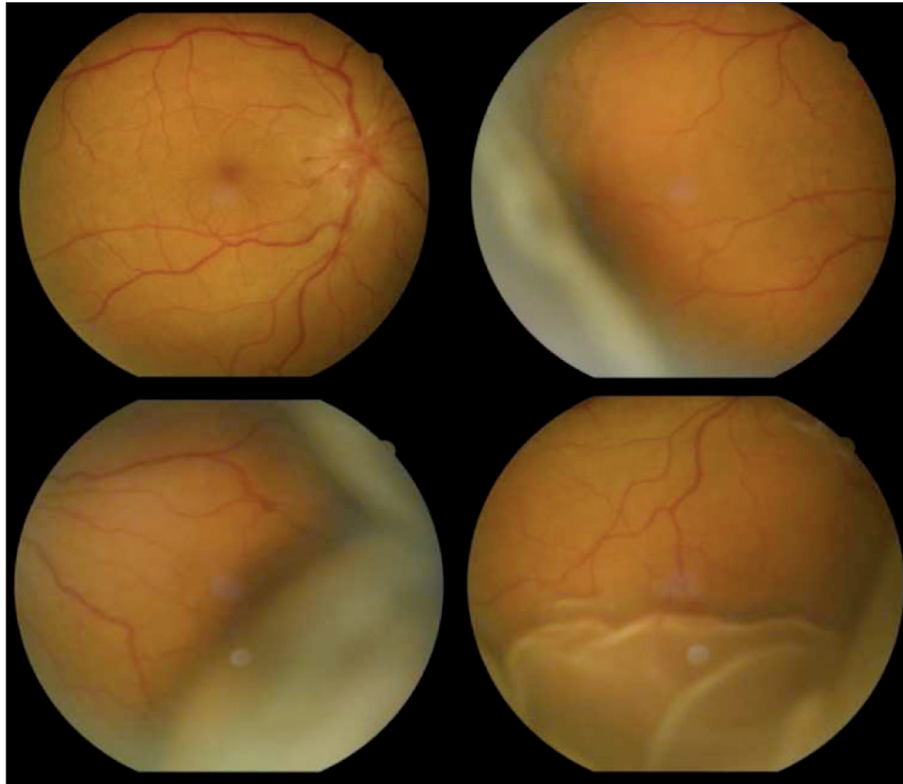


FIGURE 3: Funduscopy of the right eye: lobular serous retinal detachment.

tablet 100 mg, bid), and topical dexamethasone (Maxidex eyedrop®, qid). At one month of treatment, the visual acuity improved to 0.1 logMAR with complete resorption of the subretinal fluid (Figure 4 A, B, C, D).

DISCUSSION

Sympathetic ophthalmia is a rare panuveitis which is often diagnosed based on medical history and clinical findings of the patient. Clinical findings include granulomatous mutton fat keratic precipitates, inflammation in the anterior chamber and vitreous body, yellow-white lesions in the retinal periphery, serous retinal detachment, papillitis, optic atrophy, vasculitis, and subretinal neovascularization. Our case presented with more prominent posterior segment signs than the anterior segment findings, suggesting posterior SO. McPherson et al. reported an atypical form of SO with only posterior segment changes in two cases and termed the disease as posterior sympathetic ophthalmia.⁴ Bhandari et al. described a case of

atypical SO with only posterior segment findings which developed after therapeutic corneoscleral keratoplasty following fungal keratitis.³ The other case was published in the literature of SO after a severe *Aspergillus fumigatus* keratitis in the absence of corneal perforation by Buller.⁵ Guerriero et al. reported the first case of SO after Acanthamoeba keratitis.⁶ The two authors highlighted that in the absence of corneal perforation chronic severe keratitis may have caused the diffusion of denatured ocular antigens and proinflammatory mediators through a disrupted blood retinal barrier and triggering the development of SO. In our case corneal staphyloma secondary to keratitis may be the facilitating factor of the SO. “We hypothesise that entrapped iris within the corneal tissue can lead to the sensitization of the eye by uveal antigens leading to the damage of retinal pigment epithelium layer of the retina. On the other hand presence of an infectious agent with an antigen may have incite immune response involving exposed retinal antigens, to serve as adjuvants in this

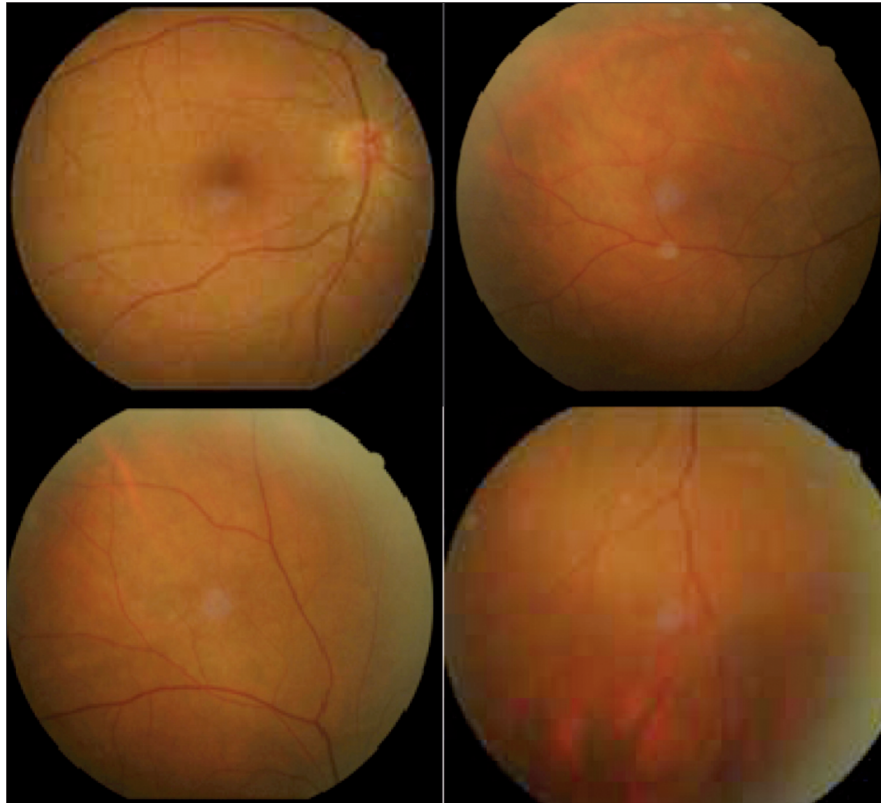


FIGURE 4: Funduscopy of the right eye at one month of the treatment: complete resorption of the subretinal fluid.

mechanism of sensitization. Then combined PK and pupilloplasty may have caused SO by exacerbation of the clinic. This hypothesis is supported by Buller et al. and Guerriero et al. who published the only case in the literature of SO after a severe keratitis in the absence of corneal perforation.^{5,6}

In addition to clinical findings, ocular imaging methods are also critical in the diagnosis and treatment of SO. FFA is able to show multiple hyperfluorescent spots at the RPE in the early venous phase, which continues to the late leakage.⁷ In addition, OCT facilitates the diagnosis of SO, enabling the management of patient's response to treatment.⁸ In a case report, SD-OCT was used to diagnose and follow SO which occurred following tectonic keratoplasty for fungal keratitis.² Our case had consistent clinical findings, FFA and OCT images supporting the diagnosis.

The limitation of our case report is the absence of indocyanine green angiography (ICGA) and enhanced depth imaging OCT (EDI-OCT) ex-

amination which are valuable tools in the diagnosis and monitoring the response to treatment of SO.⁹ Systemic corticosteroids are initially used in the treatment of SO; however, considering the adverse effects of corticosteroids, they are often used in combination with immunosuppressive agents. The visual acuity and clinical findings of our case improved with an oral steroid combined with systemic immunosuppressive drugs, followed by pulse steroid therapy. To the best of our knowledge, this is the first reported case of SO following combined PK and pupilloplasty with the diagnosis of acquired anterior staphyloma secondary to keratitis. The latter occurs subsequent to corneal perforation, usually following untreated or non-responding infective keratitis.¹⁰ In case of corneal perforation, the perforated area becomes obstructed by iris which is covered by the pseudocorneal tissues. Ultimately, anterior staphyloma develops with progressive protrusion of the pseudocorneal tissue. Depending on the size of anterior staphyloma, dif-

ferent surgical methods such as PK, sclera keratoplasty, or dural patch can be performed.^{11,12} In the present case, a large keratoplasty and lens extraction with pupilloplasty were applied.

In conclusion, ocular antigens arising in keratitis or response to excision of the entrapped iris within the corneal tissue, combined PK and pupilloplasty may induce SO. It should be kept in mind that complaints including conjunctival injection, blurred or decreased vision in the fellow eye of a patient with a history of corneal and iris surgery following chronic severe keratitis involving one eye should alert surgeons about possibility of SO.

Informed Consent

Informed consent form obtained from the patients.

Source of Finance

During this study, no financial or spiritual support was received neither from any pharmaceutical company that has a direct connection with the research subject, nor from a company that provides or produces medical instruments and materials which may negatively affect the evaluation process of this study.

Conflict of Interest

No conflicts of interest between the authors and / or family members of the scientific and medical committee members or members of the potential conflicts of interest, counseling, expertise, working conditions, share holding and similar situations in any firm.

Authorship Contributions

Writing, Discussion, Literature Review: Baran Kandemir, Nesrin Tutaş Günaydın, Burak Tanyıldız; **Idea, Design, Analysis, Interpretation:** Baran Kandemir, Nesrin Tutaş Günaydın, Burak Tanyıldız, Güzide Akçay, Eren Göktaş.

REFERENCES

1. Marak GE Jr. Recent advances in sympathetic ophthalmia. *Surv Ophthalmol* 1979;24(3):141-56.
2. Magalhães FP, Lavinsky D, Rossi LV, Barbosa L, Moraes N. Sympathetic ophthalmia after penetrating keratoplasty: a case report evaluated by spectral-domain optical coherence tomography. *Retin Cases Brief Rep* 2012;6(1):11-5.
3. Bhandari V, Ganesh Sri, Raj M, Batra A. A rare case of atypical sympathetic ophthalmia post therapeutic keratoplasty. *J Ophthalmic Inflamm Infect* 2016;6(1):34.
4. McPherson SD Jr, Dalton HT. Posterior form sympathetic ophthalmia. *Trans Am Ophthalmol Soc* 1975;73:251-63.
5. Buller AJ, Dorris JP, Bonshek R, Brahma AK, Jones NP. Sympathetic ophthalmia following severe fungal keratitis. *Eye (Lond)* 2006; 20(11):1306-7.
6. Guerriero S, Montepara A, Ciraci L, Monno R, Cinquepalmi V, Vetrugno M. A case of sympathetic ophthalmia after a severe acanthamoeba keratitis. *Eye Contact Lens* 2011;37(6):374-6.
7. Chu DS, Foster CS. Sympathetic ophthalmia. *Int Ophthalmol Clin* 2002;42(3):179-85.
8. Chan RV, Seiff BD, Lincoff HA, Coleman DJ. Rapid recovery of sympathetic ophthalmia with treatment augmented by intravitreal steroids. *Retina* 2006;26(2):243-7.
9. Castiblanco C, Adelman RA. Imaging for sympathetic ophthalmia: impact on the diagnosis and management. *Int Ophthalmol Clin* 2012;52(4):173-81.
10. Grieser EJ, Tuli SS, Chabi A, Schultz S, Downer D. Blueberry eye: acquired total anterior staphyloma after a fungal corneal ulcer. *Cornea* 2009;28(2):231-2.
11. Panda A, Sharma N, Angra SK, Singh R. Sclerokeratoplasty versus penetrating keratoplasty in anterior staphyloma. *Ophthalmic Surg Lasers* 1999;30(1):31-6.
12. Yalçındag FN, Celik S, Ozdemir O. Repair of anterior staphyloma with dehydrated dura mater patch graft. *Ophthalmic Surg Lasers Imaging* 2008;39(4):346-7.