

Surgical Treatment of Tongue Hemangioma with Diode Laser: Case Report

Dil Hemanjiyomasının Diode Lazerle Cerrahi Tedavisi

Göksel ŞİMŞEK KAYA,^a
Günay YAPICI YAVUZ,^a
Ertunç DAYI,^a
Elif DEMİRCİ^b

^aDepartment of Oral and
Maxillofacial Surgery,
Atatürk University Faculty of Dentistry,
^bDepartment of Pathology,
Atatürk University Faculty of Medicine,
Erzurum

Geliş Tarihi/Received: 17.01.2011
Kabul Tarihi/Accepted: 09.02.2011

Yazışma Adresi/Correspondence:
Göksel ŞİMŞEK KAYA
Atatürk University Faculty of Dentistry,
Department of Oral and
Maxillofacial Surgery, Erzurum,
TÜRKİYE/TURKEY
gokselsemsek@yahoo.com

ABSTRACT Hemangiomas are benign, non-reactive lesions containing a large number of vessels. Although several different treatment modalities have been proposed, the management of hemangiomas remains a subject of considerable controversy, and thus the search for a new form of treatment continues. Developments in laser therapy have led to new alternatives for the treatment of vascular lesions of the maxillofacial region. This report describes a hemangioma on the lateral surface of the tongue caused by dental trauma and its successful surgical treatment with a Continuous Wave Gallium Aluminum Arsenide (GaAlAs) diode laser at 3.0 W and a wavelength of 808 nm. The absence of any peri- or post-operative complications and the excellent tissue regeneration achieved in this case show that diode laser surgery may be a suitable alternative for treating superficial tongue hemangiomas.

Key Words: Hemangioma, cavernous; hemangioma, capillary; tongue; lasers; laser therapy

ÖZET Hemanjiyomalar, çok sayıda damar içeren iyi huylu ve reaktif olmayan lezyonlardır. Çok çeşitli tedavi yöntemleri önerilmiş olmasına karşın, hemanjiyomaların tedavisi hâlâ tartışmalı bir konudur ve bu yüzden yeni bir tedavi yönteminin araştırılması devam etmektedir. Lazer tedavisinde meydana gelen gelişmeler, maksillofasial bölgedeki vasküler lezyonların tedavisinde yeni alternatiflerin gelişmesine yol açmıştır. Bu rapor, dental travmanın neden olduğu dilin yan yüzeyindeki hemanjiyomayı ve bu lezyonun sürekli dalga boyuna sahip Gallium Aluminum Arsenide (GaAlAs) diode lazerle 808 nm dalga boyu ve 3.0 W'ta yapılan başarılı cerrahi tedavisini sunmaktadır. Bu olguda herhangi bir peri- veya postoperatif komplikasyonun görülmemesi ve mükemmel doku rejenerasyonunun elde edilmesi diode lazerin yüzeyel dil hemanjiyomalarının tedavisinde uygun bir alternatif olabileceğini göstermektedir.

Anahtar Kelimeler: Hemanjiyom, kavernöz; hemanjiyom, kapillar; dil; lazerler; lazer tedavisi

Türkiye Klinikleri J Dental Sci 2015;21(1):57-60

Hemangiomas are benign, non-reactive lesions containing a large number of vessels.¹ Although hemangiomas are one of the most common soft-tissue tumors of the head and neck, they are comparatively rare in the oral cavity. Hemangiomas are more common in females than in males and usually develop during the neonatal period, grow during the first year of life and then gradually regress. In fact, the majority of congenital hemangiomas regress spontaneously with no need for treatment.^{2,3}

Hemangiomas are classified histologically as capillary, cavernous or mixed based on the size of their vascular spaces. Clinically, hemangiomas present as smooth or lobulated, sessile or pedunculated soft masses ranging in size from

a few millimeters to several centimeters and in color from a pink to reddish purple that blanches upon pressure. Hemorrhage may occur either spontaneously or in the wake of minor trauma. While the majority of hemangiomas are painless, tongue hemangiomas may be a source of distress to patients and their families, not only because they represent a cosmetic deformity, but because of spontaneous hemorrhaging and functional problems related to speaking, deglutition and chewing as well as shortness of breathe secondary to lingual enlargement.^{2,4}

A range of alternative treatment modalities for the management of head and neck hemangiomas has been proposed, including careful observation, steroid and other drug therapy, fibrosing agents, interferon, radiation, cryosurgery, laser therapy, embolization and surgical excision.^{5,6} The issue of when and how to treat hemangiomas remains controversial.⁵ Developments in laser therapy have led to new possibilities for the treatment of vascular lesions of the maxillofacial region.⁷ The many advantages of laser therapy-ablation or vaporization, local hemostasis, a virtually bloodless surgical field, sterilization and contact-free incision-make it suitable as either an alternative or an adjunct to more conventional therapies.⁸ The following case report describes the surgical extraction of a hemangioma on the lateral surface of the tongue using a GaAlAs diode laser.

CASE REPORT

A 55-year-old male was admitted to our clinic with a slow-growing lesion on the tongue that for the past year had caused pain upon movement of the tongue. The patient's teeth were abraded, and both the upper and lower right molar regions were toothless. Clinical examination revealed a 4 x 2 cm non-pedunculated, bluish, soft mass on the right lateral surface of the tongue. The overlying mucosa was normal (Figure 1). No other lesions were clinically visible in the head and neck region, and the lymph nodes could not be palpated. The patient reported no previous systemic illness and was unable to confirm how long the lesion had been present.

A pre-diagnosis of lingual hemangioma was made. Due to the large size of the lesion, a high-

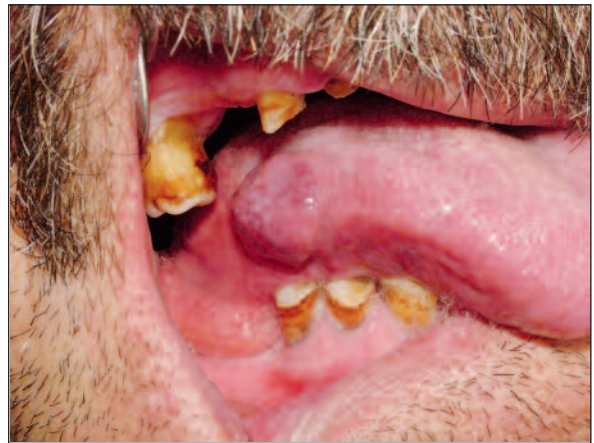

FIGURE 1: Pre-operative appearance of the hemangioma.

powered laser was chosen for surgical intervention, with the patient attending treatment on an outpatient basis. Articaine HCl 2.5% plus 1:100, 000 epinephrine (Ultracaine D-S Forte Ampul; Aventis, Istanbul, Turkey) were used as a lingual nerve block. The lesion was totally resected using an 808 nm, 100 mW Continuous Wave Gallium Aluminum Arsenide (GaAlAs) diode laser ('Doctor Smile', Lambda Laser Products, Vicenza, Italy), with 3-W administered via a pencil-sized hand-piece containing 300-mm lasing fiber. A surgical aspirator was used to cool the operative site. Hemorrhage during the procedure was minimal (Figure 2). Postoperatively, the patient was given 500 mg of oral amoxicillin (Alfoxil; Abfar, Istanbul, Turkey) three times per day for 5 days, 500 mg acetaminophen (Minoset; Roche, Istanbul, Turkey) as an analgesic as necessary and a benzydamine HCL + chlorhexidine gluconate gargle antiseptic solution (Farhex; Santa Farma, Istanbul, Turkey) three times per day for 5 days. No pain, dyspnea or hemorrhage was observed postoperatively, and swallowing, taste perception, chewing and speaking functions were normal. Histopathological analysis revealed a mixed capillary and cavernous hemangioma (Figure 3). No sign of recurrence was observed during six months post-surgery (Figure 4).

DISCUSSION

Hemangiomas are benign vascular lesions of uncertain etiology.^{2,9} Both trauma and hormonal changes

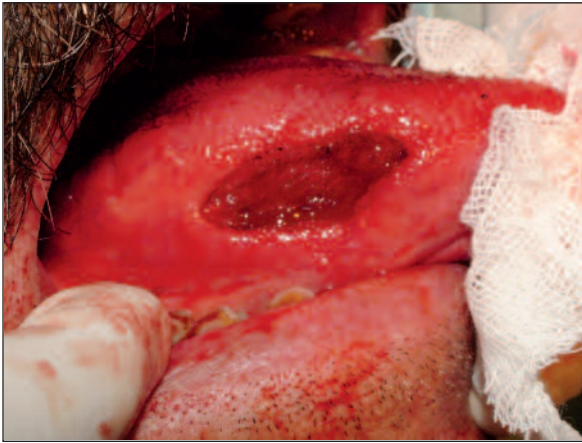

FIGURE 2: Appearance of the hemangioma immediately post-surgery.

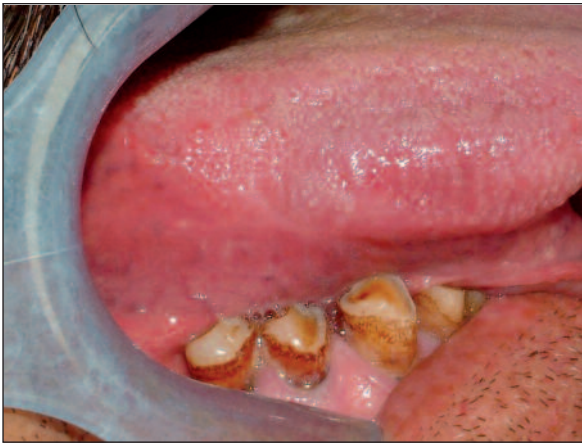

FIGURE 3: Intra-oral appearance of the patient 6 months after the surgery.

are regarded as significant factors involved in the proliferation of embryonic vascular tissue; however, a congenital theory has been also been put forward based on the high incidence of hemangiomas during the first years of life.⁹ In the case presented here, the hemangioma is likely to have developed as a result of repeated mechanical trauma caused by abraded teeth during continuous movement of the tongue toward an edentulous area in the mouth as part of functional movement, thus corroborating the role of trauma in the etiology of these lesions.

Lasers have been used to treat a wide range of vascular lesions. Studies have reported the successful application of several types of lasers for hemangiomas.⁶ Diode lasers comprised of gallium, arsenide,

aluminum or indium semiconductors that transform electrical energy into light energy are used almost exclusively for soft-tissue surgery and have a number of advantages over other laser types. Soft tissue absorbs a high level of light energy from the diode.^{6,8} Diode lasers used in dentistry have wavelengths ranging from 800 nm to 980 nm, in the ionized part of the spectrum, which not only makes them absorbable by water, but allows high levels to be absorbed by chromophores such as melanin and oxyhemoglobin. Diode lasers are able to make incisions by establishing coagulation and hemostasis, and in contrast to carbon-dioxide lasers, the diode laser beam is carried by flexible optic fibers that can be coupled to telescopes, making it possible to access sites that are difficult to explore and control vascular bleeding easier than with other techniques.^{6,10} The continuous-wave diode laser at low power is a useful tool for tissue excision and reducing bacteria when used in a contact mode.^{6,8} In addition, the exclusive use of this laser in contact or at very close proximity eliminates potential damage from “beam escape” in an open field, making it much safer than other laser sources. Compared with other lasers such as neodymium: YAG and potassium-titanyl-phosphate, the diode laser is more precise and less invasive.¹⁰

In the case presented here, diode laser treatment was able to control peri-operative bleeding, and no tongue swelling, bleeding, loss of taste per-

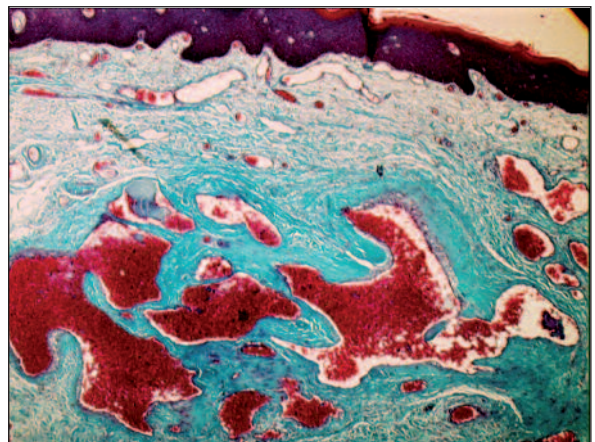


FIGURE 4: Capillary and cavernous lumens in the fibrous tissue (H&E staining; x200).

ception or pain was observed postoperatively. The lack of peri- and post-operative complications and the ideal level of tissue regeneration observed in this study indicate diode laser surgery to be a suit-

able alternative for the treatment of superficial hemangiomas of the tongue. However, comprehensive scientific studies are required to arrive at a definitive judgment.

REFERENCES

1. Fronie A, Simionescu C, Vască V, Dumitrescu D, Fronie AS. Histopathological aspects of benign mesenchymal tumors located in "high risk areas" of the tongue. *Rom J Morphol Embryol* 2010;51(1):97-104.
2. Bonet-Coloma C, Mínguez-Martínez I, Palma-Carrió C, Galán-Gil S, Peñarocha-Diago M, Mínguez-Sanz JM. Clinical characteristics, treatment and outcome of 28 oral haemangiomas in pediatric patients. *Med Oral Patol Oral Cir Bucal* 2011;16(1):e19-22.
3. Gönülol E, Gündüz K, Sümer M, Süllü Y. [Oral pyogenic granuloma associated with congenital hemangioma (Sturge-Weber Syndrome): case report]. *Turkiye Klinikleri J Dental Sci* 2009;15(1):40-3.
4. Neville BW, Damm DD, Allen CM, Bouquot JE. *Congenital Disorders. Oral and Maxillofacial Pathology*. 2nd ed. Philadelphia: WB Saunders; 2002. p.447-9.
5. Zheng JW, Zhou GY, Wang YA, Zhang ZY. Management of head and neck hemangiomas in China. *Chin Med J (Engl)* 2008;121(11):1037-42.
6. Genovese WJ, dos Santos MT, Faloppa F, de Souza Merli LA. The use of surgical diode laser in oral hemangioma: a case report. *Photomed Laser Surg* 2010;28(1):147-51.
7. Băciuț M, Băciuț G, Câmpian RS, Crișan B, Crișan L, Hurubeanu L, et al. [Use of laser-therapy for treatment of oral and maxillofacial hemangioma]. *Rev Med Chir Soc Med Nat Iasi* 2008;112(2):512-6.
8. Aras MH, Göregen M, Güngörmüş M, Akgül HM. Comparison of diode laser and Er:YAG lasers in the treatment of ankyloglossia. *Photomed Laser Surg* 2010;28(2):173-7.
9. Bucci T, De Giulio F, Romano A, Insabato L, Califano L. Cavernous haemangioma of the temporalis muscle: case report and review of the literature. *Acta Otorhinolaryngol Ital* 2008;28(2):83-6.
10. Saetti R, Silvestrini M, Cutrone C, Narne S. Treatment of congenital subglottic hemangiomas: our experience compared with reports in the literature. *Arch Otolaryngol Head Neck Surg* 2008;134(8):848-51.