

Colon Volvulus in Childhood: Case Report

Çocukluk Çağında Kolon Volvulusu

Derya ERDOĞAN, MD, Msc,^a
Ayşe KARAMAN, MD, Assoc.Prof.,^a
Y. Hakan ÇAVUŞOĞLU, MD, Assoc.Prof.,^a
İbrahim KARAMAN, MD, Assoc.Prof.,^a
Mustafa ÖZÇATAL, MD, Msc^a

^aPediatric Surgery Clinic,
Dr. Sami Ulus Obstetrics and
Gynecology, Pediatric Training and
Research Hospital, Ankara

Geliş Tarihi/Received: 03.05.2010
Kabul Tarihi/Accepted: 03.11.2010

*This study was presented as a poster at
27th National Congress of Pediatric Surgery,
30 September-3 October, 2009, Malatya,
TURKEY.*

Yazışma Adresi/Correspondence:
Derya ERDOĞAN, MD, Msc
Dr. Sami Ulus Obstetrics and Gynecology,
Pediatric Training and Research Hospital,
Pediatric Surgery Clinic, Ankara,
TÜRKİYE/TURKEY
deryaerdo@yahoo.com

ABSTRACT A 12-year-old boy with mental retardation and epilepsy was admitted with a 2-day history of vomiting, abdominal pain, constipation and severe abdominal distension. Physical examination showed a marked abdominal distention and generalized tenderness. Plain X-rays of the abdomen showed a markedly dilated loop of large intestine with multiple air-fluid levels. Surgical exploration revealed presence of a 180° counterclockwise volvulus of the transverse colon. A 15-year-old boy was admitted with the history of abdominal pain, constipation and abdominal distension. Non-operative reduction was performed with decompression of rectum and all the symptoms disappeared. The patient was discharged from the hospital. He was admitted with the same complaints seven days later. Surgical exploration revealed presence of a 720° counterclockwise sigmoid volvulus. Large intestinal volvulus is a rare surgical problem in childhood and it may be due to congenital or acquired anatomical variations. In this report, two cases of colon volvulus in childhood were presented and etiology and management were discussed.

Key Words: Colon; child; intestinal volvulus; mental retardation

ÖZET Mental retardasyon ve epilepsili 12 yaşında bir erkek çocuk son iki gündür devam eden karın ağrısı, konstipasyon, şiddetli abdominal distansiyon ve kusma nedeniyle başvurdu. Fizik muayenede belirgin bir abdominal distansiyon ve yaygın hassasiyeti mevcuttu. Düz karın grafisinde çok sayıda hava-sıvı seviyeleri ile birlikte belirgin dilate kolon lüpu gözlemlendi. Cerrahi eksplorasyonda kolonda saatin tersi yönünde 180°'lik transvers volvulusu olduğu görüldü. On beş yaşında bir erkek çocuk karın ağrısı, konstipasyon ve abdominal distansiyon ile başvurdu. Rektum dekompresyonu yoluyla sağlanan nonoperatif redüksiyon sonrası tüm semptomlar kaybolmuştu. Hasta hastaneden taburcu edildikten yedi gün sonra aynı yakınmalarla başvurdu. Cerrahi eksplorasyonda saatin tersi yönünde 720°'lik sigmoid volvulusu olduğu gözlemlendi. Kolon volvulusu çocukluk çağında nadir görülen bir cerrahi sorundur ve konjenital veya anatomik varyasyonlara bağlı olabilmektedir. Bu yazıda iki çocukluk çağı kolon volvulusu olgusu sunularak etyoloji ve tedavileri tartışılmıştır.

Anahtar Kelimeler: Kolon; çocuk; bağırsak volvulusu; mental retardasyon

Türkiye Klinikleri J Med Sci 2012;32(4):1131-4

Colon volvulus is a rare cause of childhood intestinal obstruction. It is most frequently seen in the sigmoid colon and is rarely seen in the cecum and transverse colon.^{1,2}

CASE REPORTS

CASE 1

A 12-year-old epileptic and mentally retarded male patient was admitted with a 2-day history of vomiting, abdominal pain, constipation and marked

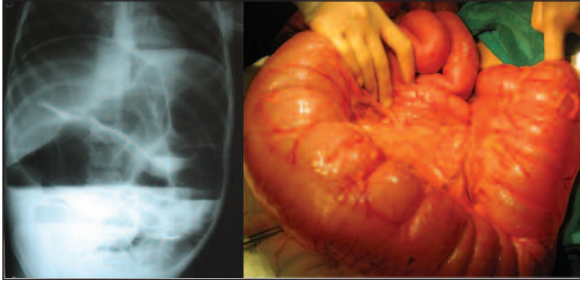


FIGURE 1: Plain abdominal X-ray and surgical findings in transverse colon volvulus.

(See for colored from <http://tipbilimleri.turkiyeklinikleri.com/>)

abdominal distension. His history revealed that he had been suffering from epileptic seizures since he was 6 months old, and he had been using low dose anticonvulsants irregularly. He had chronic constipation for a long time, but vomiting and distension had been added for last two days. Physical examination revealed marked distension and diffuse sensitivity in the abdomen. Plain abdominal X-ray showed multiple air-fluid levels and markedly dilated intestinal loops (Figure 1). Laboratory tests showed a white blood cell (WBC) count of $16.700/\text{mm}^3$ and C-reactive protein (CRP) of 11.2 mg/L (both were higher than the normal values) while Na was 132 mEq/L and K 2.5 mEq/L (both were lower than the normal values). Other test results were within normal limits. Surgical exploration revealed presence of a 180° counterclockwise volvulus of the transverse colon and detorsion was achieved (Figure 1). A special diet and treatment for constipation were recommended. There was no problems during three-year follow-up.

CASE 2

A 15-year-old male was admitted with abdominal pain, inability to pass feces and distension for one day and he also had a history of chronic constipation. Physical examination showed marked abdominal distension. Complete blood count and biochemical test results were in the normal limits while plain abdominal X-ray showed dilated intestinal loops and air-fluid levels. Non-operative reduction was achieved with an enema and rectum decompression that led to resolution of the pa-

tient's signs and symptoms. The patient was admitted again with vomiting, abdominal pain and distension for seven days after discharge, and he had marked abdominal distension and tenderness. All tests were normal except for a WBC count of $15.300/\text{mm}^3$. Plain abdominal X-ray showed air-fluid levels with a wide base. Surgical exploration revealed presence of a 720° counterclockwise sigmoid volvulus (Figure 2). Intestinal viability was good but sigmoid colon resection and anastomosis was performed following detorsion because the mesocolon was long and narrow, and there was a history of recurrent volvulus. The follow-up was uneventful.

DISCUSSION

Large intestinal volvulus can develop idiopathically or due to several factors. These factors include chronic constipation, Hirschsprung's disease, excessive fiber in the diet, decreased intestinal motility in mentally retarded patients due to the psychotropic drugs used, malrotation, past surgery and adhesions, Chagas disease, myotonic dystrophy and Prune Belly syndrome.³⁻⁹ There are also some cases reported after an antegrade colonic enema.¹⁰ Constipation may be due to intermittent volvulus, or a mechanic volvulus may develop following chronic constipation as in Hirschsprung's disease. The presence of an abnormal posture as in patients with cerebral palsy can also be a predisposing factor in the development of volvulus by causing colonic distension. Cecal, transverse or sigmoid

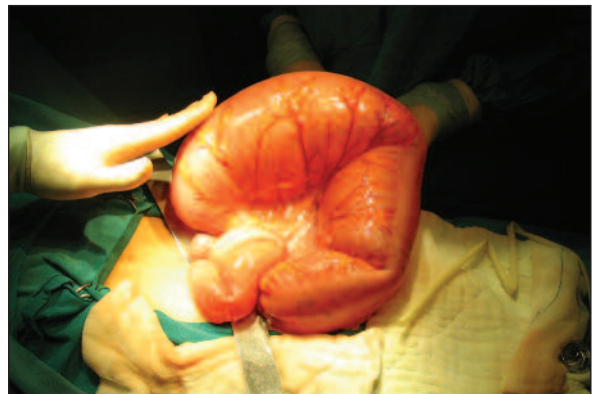

FIGURE 2: Sigmoid colon volvulus.

(See for colored from <http://tipbilimleri.turkiyeklinikleri.com/>)

colon volvulus in childhood may also be caused by some congenital factors such as absence or abnormal structure of the phrenocolic and splenocolic ligaments, absence of cecal fixation, a narrow and long mesocolon, narrow hepatic and splenic flexures with long connections, and a narrow sigmoid with a long mesocolon.

Cecal volvulus and transverse colon volvulus are seen much less frequently than sigmoid volvulus.^{1,2} One of the patients we operated on for volvulus had mental retardation and chronic constipation and the cause of the transverse colon volvulus was probably irregular intestinal function due to mental retardation. On the other hand, we found that the long and narrow sigmoid mesocolon might have played a role in the sigmoid volvulus etiology in our other patient.

Early diagnosis of volvulus is important. Some patients may suffer from similar previous attacks and then recover. Clinical findings may be crampy abdominal pain, vomiting, constipation, abdominal distension and bloody defecation. Physical examination findings are abdominal distension, tenderness and intestinal sounds that first increase and then decrease. There may be a palpable mass. Plain abdominal X-rays usually show wide intestinal dilatations and air-fluid levels. A colon X-ray with barium may be ordered in patients with no intestinal gangrene sign or peritonitis on physical examination; the typical 'bird's beak' appearance on colon X-ray is helpful in diagnosis.²

Once the diagnosis is made, wide-spectrum antibiotics should be started and the patient should be rapidly prepared for surgery.¹¹ The role of colonoscopic decompression and reduction is lim-

ited in children. A success rate of 79% has been reported following a barium enema reduction, but recurrence is common and therefore, definite treatment of childhood colon volvulus is surgery.¹² Barium reduction provides some extra time to correct the patient's fluid-electrolyte balance and to treat dehydration before surgery. Our first case was operated on following preoperative preparation, because his physical examination revealed tenderness. We did not consider barium enema and decompression to achieve reduction in the second case, and operated him directly because of recurrent volvulus.

Resection-anastomosis or colostomy is used in the presence of intestinal gangrene in a colonic volvulus case. Segment resection and end-to-end anastomosis are recommended in cases with viable intestines and a longer-than-normal mesocolon together with colonic fixation deficiency following detorsion.^{5,12} However, our patient with transverse colon volvulus had an uneventful follow-up with a proper diet and treatment for constipation following detorsion despite the lack of colonic resection.

Sigmoid colon resection-anastomosis together with laparoscopy is also recommended in selected cases.¹³ Hirschsprung's disease should also be considered in the etiology and a biopsy is obtained in case of any suspicion.

In conclusion, large intestine volvulus is rare in childhood but it is a surgical problem that should be considered in the differential diagnosis, especially in children with chronic constipation and mental retardation who present with abdominal pain and distension symptoms. The treatment is surgical exploration.

REFERENCES

- Samuel M, Boddy SA, Nicholls E, Capps S. Large bowel volvulus in childhood. *Aust N Z J Surg* 2000;70(4):258-62.
- Mercado-Deane MG, Burton EM, Howell CG. Transverse colon volvulus in pediatric patients. *Pediatr Radiol* 1995;25(2):111-2.
- Smith SD, Golladay ES, Wagner C, Seibert JJ. Sigmoid volvulus in childhood. *South Med J* 1990;83(7):778-81.
- Asbun HJ, Castellanos H, Balderrama B, Ochoa J, Arismendi R, Teran H, et al. Sigmoid volvulus in the high altitude of the Andes. Review of 230 cases. *Dis Colon Rectum* 1992;35(4):350-3.
- Ballantyne GH, Brandner MD, Beart RW Jr, Ilstrup DM. Volvulus of the colon. Incidence and mortality. *Ann Surg* 1985;202(1):83-92.
- McCalla TH, Arensman RM, Falterman KW. Sigmoid volvulus in children. *Am Surg* 1985;51(9):514-9.
- Kirks DR, Swischuk LE, Merten DF, Filston HC. Cecal volvulus in children. *AJR Am J Roentgenol* 1981;136(2):419-22.
- Neilson IR, Youssef S. Delayed presentation of Hirschsprung's disease: acute obstruction secondary to megacolon with transverse colonic volvulus. *J Pediatr Surg* 1990;25(11):1177-9.

9. Valla JS, Louis D, Berard J, Jaubert M, de Beaujeu MJ. [Sigmoid volvulus in children. About 6 cases (author's transl)]. *Chir Pediatr* 1982;23(2):93-6.
10. Kokoska ER, Herndon CD, Carney DE, Lerner M, Grosfeld JL, Rink RC, et al. Cecal volvulus: a report of two cases occurring after the antegrade colonic enema procedure. *J Pediatr Surg* 2004;39(6):916-9.
11. Akgün Y, Gedik E. [Mechanical colon obstruction]. *Türkiye Klinikleri J Surg Med Sci* 2007;3(28):50-6.
12. Mellor MF, Drake DG. Colonic volvulus in children: value of barium enema for diagnosis and treatment in 14 children. *AJR Am J Roentgenol* 1994;162(5):1157-9.
13. Liu KK, Leung MW, Wong BP, Chao NS, Chung KW, Kwok WK. Minimal access surgery for sigmoid volvulus in children. *Pediatr Surg Int* 2006;22(12):1007-8.