

# Effect of Cisplatin on Bacterial Translocation in An Experimental Model with Increased Intestinal Microflora

## SİSPLATİNİN İNTESTİNAL FLORASI ZENGİNLEŞTİRİLMİŞ RATLARDA BAKTERİYAL TRANSLOKASYONA ETKİSİ

Bahar ULUBAŞ, MD,<sup>a</sup> Gülden ERSÖZ, MD,<sup>b</sup> Banu COŞKUN, MD,<sup>c</sup> Münir TÜMKAYA, MD,<sup>a</sup> Handan ÇAMDEVİREN, MD,<sup>d</sup>

Departments of <sup>a</sup>Chest Diseases, <sup>b</sup>Infection Disease, <sup>c</sup>Histopathology, <sup>d</sup>Biostatistics, Mersin University Faculty of Medicine, MERSİN

### Abstract

**Objective:** Several reasons cause bacterial translocation and these may be increase mortality and morbidity of patients. Cisplatin is the most important antineoplastic drug in treatment of lung cancer. The aim of the study was to investigate cisplatin effect on bacterial translocation in Wistar albino rats.

**Material and Methods:** 15 female Wistar albino rats were studied. To rich intestinal microflora, 24 h before drug administration, all of them were given *Escherichia coli* suspension by oral way. Eight of the 15 rats, were given intraperitoneal Cisplatin 6 mg/kg and others were 1 mL saline solution as a control group. During study (48 h), food and drink intake were restricted to constitute starvation effect. At the end of the study, liver, spleen, ileum and arterial blood samples were obtained each sample.

**Results:** The mean weight of the rats was 162.66 ± 14.43 (138-182) g. Peripheral blood counts were similar each group (p> 0.307). In cisplatin administered group, bacterial growing was found on one blood culture, two mesenteric lymph node (MLN) and three spleen. Total logarithmic number of bacteriologic growing was not significant than control. On histopathology examination, necrosis in ileum was not found in groups, additionally respect to infiltration of PMNL in liver and ileum were not significant difference.

**Conclusion:** The presented study results implied that cisplatin administration was not increase infection risk due to bacterial translocation on experimental models.

**Key Words:** Bacterial translocation, cisplatin, rats

Türkiye Klinikleri J Med Sci 2004, 24:633-637

### Özet

**Amaç:** Çeşitli nedenlerle ortaya çıkabilen bakteriyal translokasyon hastalarda mortalite ve morbiditeyi arttırmaktadır. Sisplatin akciğer kanserlerinin tedavisinde kullanılan en önemli antineoplastik ajanlardan biridir. Bu çalışmanın amacı sisplatin uygulanan ratlarda bakteriyolojik ve histopatolojik olarak bakteriyal translokasyona etkisini araştırmaktır.

**Gereç ve Yöntemler:** Çalışmaya 15 Wistar albino rat alındı. Ratlara uygulamadan 24 saat önce intestinal mikroflorayı arttırmak amacıyla *Escherichia coli* süspansiyonu verildi. Çalışma grubu olarak 8 rata intraperitoneal 6 mg/kg sisplatin uygulanırken, 7'si kontrol grubu olarak seçildi ve aynı yolla 1 mL serum fizyolojik verildi. Açlık etkisini oluşturabilmek için çalışmanın devam ettiği 48 saat boyunca, oral sıvı ve gıda verilmedi. Uygulamadan 24 saat sonra çalışma sonlandırıldı. Ratların herbirinden çalışma sonunda intrakardiyak kan, mezenter lenf nodu (MLN), karaciğer, dalak, ileum dokusundan örnekler alındı.

**Bulgular:** Ratların ortalama ağırlığı 162.66 ± 14.43 g (138-182) olarak saptandı. Periferik kan hücre sayısı bakımından gruplar arasında anlamlı fark yoktu (p> 0.307). Sisplatin uygulanan gruptaki bir ratta kan kültüründe, 2'sinde MLN'de ve 3'ünde dalak dokusundan alınan örneklerde üreme saptandı. Bakteriyal üremenin total logaritmik sayısı bakımından gruplar arasında anlamlı fark saptanmadı. Histopatolojik incelemede her iki grupta da ileumda nekroz saptanmadığı gibi, ileum ve karaciğerde lökosit infiltrasyonu açısından fark bulunmadı.

**Sonuç:** Sisplatin uygulamasının bakteriyal translokasyon nedeniyle enfeksiyon riskini arttırmadığını göstermektedir.

**Anahtar Kelimeler:** Bakteriyal translokasyon, sisplatin, rat

In addition to nutrient absorption and fluid secretion, the gastrointestinal tract serves as a potent barrier that prevents luminal bacteria

from entering the host. This barrier function is maintained by a well-balanced intestinal flora, an unaltered permeability of the intestinal mucosa, and a normal functioning immune system.<sup>1</sup> Bacterial translocation is defined as the phenomenon by which live bacteria, their products, or both cross the intestinal barrier. The first organ encountered by the organism or product undergoing translocation is the mesenteric lymph node (MLN). Subsequently, extension to the liver,

Geliş Tarihi/Received: 27.02.2003

Kabul Tarihi/Accepted: 22.05.2003

**Yazışma Adresi/Correspondence:** Bahar ULUBAŞ, MD  
Köy-Tür (2) Sitesi, B(2) Blok, Daire 4,  
D. Tepe, 33320 MERSİN  
baharulubas@hotmail.com

Copyright © 2004 by Türkiye Klinikleri

Türkiye Klinikleri J Med Sci 2004, 24

633

spleen, and the general circulation may occur. Three mechanisms are proposed to promote bacterial translocation: Small bowel bacterial overgrowth, immune deficiency state, and physical damage to the intestinal mucosa and vasculature that causes increased permeability.<sup>2,3</sup> Passage of bacteria through mucosal membranes and survival in extra-intestinal sites depend on the effectiveness of the host immune system. Both humeral and cellular immunity have been shown to be important in protection against translocation.<sup>4</sup> Intestinal microflora as the driving force behind systemic inflammatory response syndrome (SIRS) and multisystem organ dysfunction is to study the effects of therapies designed to treat the putative mechanisms of bacterial translocation while monitoring the clinical status of the patients. The hypothesis is that oral flora and aerobic intestinal bacteria may undergo translocation and cause infections in sick patients including pneumonia, bacteraemia, or urinary tract infection.

Cisplatin is one of the most effective chemotherapeutic agents and plays an important role in the treatment of lung cancer.<sup>5</sup> In cancer patients, systemic infections risk increases to mortality. The aim of the study was to investigate bacteriologic and histopathologic effect of cisplatin on bacterial translocation.

### Material and Methods

Fifteen wistar rats were used in this study. The animals were obtained from the animal breeding centre of Veterinary Faculty of Erciyes University.

All animals were fed with a standard rat's diet for 1 week before the experiment. Rats were kept in the same environment with a room temperature of 18°C to 22°C. In order to provide starvation effects on bacterial translocation, before and after 24 h administration of cisplatin rats were not given food or water.

**Processing of bacteriological samples:** By oral way, viable *Escherichia coli* cells ( $2 \times 10^7$ /g of body weight) isolate, from getting septic patients blood, were given each group. The rats were divided into two groups. Group I (n: 8) animals

received 6 mg/kg cisplatin (Cisplatinum®-Onko-İstanbul-Turkey) via intraperitoneal. Group II (n: 7) was administered 1 mL saline solution in to same way. No animal died before the end of the study. In the 24<sup>th</sup> h after cisplatin administration, the rats were anaesthetized with 50 mg/kg ketamine hydrochloride (Ketalar®; EWL Eczacıbaşı Warner Lambert İstanbul-Turkey) and using sterile technique, the chest cavity was opened and animals were sacrificed by cardiac blood aspiration. 100 µL of two blood samples were incubated aerobically for 48 h at 37°C in 5 mL of thioglycollate broth and plated 5% blood agar plates. After retraction, abdominal cavity was opened with sterile forceps and the liver, spleen, and mesenteric lymph nodes were obtained, and all organs were divided into small pieces. The pieces of tissue were weighed separately and placed in a sterile grinding tube. The samples were homogenized with 1 mL of thioglycollate broth using sterile ground-glass stoppers. After mechanical grinding (Pottere S, Biolab, Melcungen-Germany), 500 µL of homogenate were transferred into a tube containing 4.5 mL of 0.9% NaCl, and used to perform serial four dilutions. From this dilution, 100 µL aliquots were plated onto two different plates, including 5% blood agar and EMB agar. Quantitative culture results were determined by the number of colony-forming units (CFU) per gram calculated from the dilutions of tissue homogenate cultures with the formula [(number of CFU x reciprocal of dilution x 10)/weight of tissue]. We did not study obligate anaerobes because these organisms are rare causes of translocation. Finally, the terminal ileal loop and cecum were excised, placed in a tube of thioglycollate broth. To prevent contamination of the environment, cecal cultures were prepared as the last procedure. All agar plates and thioglycollate broth tubes incubated aerobically 5% CO<sub>2</sub> for 24 h at 37°C. The gram-negative enteric were identified by biochemical profiles, and *Enterococcus* spp was identified by esculin hydrolysis in the presence of bile, and grows in broth containing 6.5% NaCl.

Processing of histological samples; samples from the central of the ileum, liver and spleen were taken and fixed with neutral formalin 10%.

Paraffin sections were stained with haematoxylin. Two experienced histopathologists examined coded slides blind. Several inflammatory and destructive changes such as: Haemorrhages, necroses, infiltration by polymorph nuclear leucocytes (PMNLs) were evaluated. A numerical score was given to the changes: 0= Norm; -1, -2, -3= Diminishing (mild, moderate, severe changes) as compared with the norm; -1, -2, -3= Increasing changes as compared with the norm. The norm was defined by the examination of control rats as in a previous study.

Statistical analyses were performed by using SPSS 9.05 version. The following tests were used: Unpaired *t* test for comparison of groups with normally distributed data, Mann-Whitney test for comparison of groups without normal distribution and  $\chi^2$  test for prevalence comparison of changes between groups.

### Results

The mean weight of the rats was  $162.66 \pm 14.43$  (138-182) g. In group I, bacterial growing was found one blood culture, 2 MLN and 3 spleen. Total logarithmic number of bacteriologic growing was not significant than controls. Bacteriological examination and statistical analysis results were shown Table 1 and 2. Peripheral blood counts were similar each group ( $p > 0.307$ ). On histopathology

examination, necrosis in ileum was not found in groups, additionally respect to infiltration of PMNL in liver and ileum were not significant differences (Figure 1 and 2).

### Discussion

Gut serves as a reservoir for bacteria, fungi and parasites. One gram of feces contains  $10^{11}$  to  $10^{12}$  anaerobic and  $10^8$  to  $10^{10}$  aerobic bacteria.<sup>6</sup> The “gut origin of sepsis” hypothesis proposes that

**Table 1.** Total number of growing bacteria on the studied tissues of the cisplatin administered group and controls.

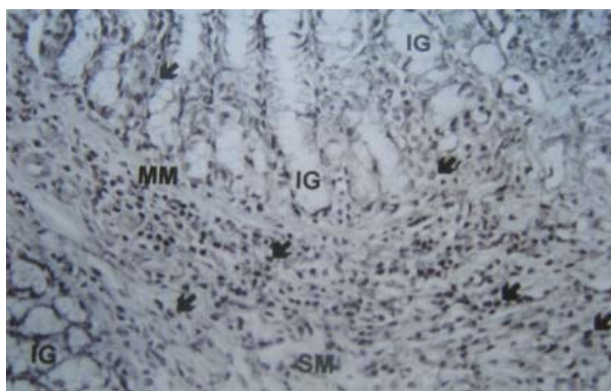
	Ileum	MLN*	Liver	Spleen	Blood
<b>Cisplatin groups</b>					
1	$4 \times 10^8$	$2 \times 10^6$	-	-	-
2	-	-	-	$3 \times 10^4$	-
3	$8 \times 10^7$	-	-	$7 \times 10^4$	-
4	$24 \times 10^5$	-	-	$4 \times 10^5$	-
5	$15 \times 10^3$	-	-	-	-
6	$4 \times 10^6$	-	-	-	-
7	$5 \times 10^4$	-	-	-	-
8	$1 \times 10^4$	-	-	-	-
<b>Controls</b>					
1	$9 \times 10^6$	-	-	-	-
2	$15 \times 10^5$	$1 \times 10^6$	$2 \times 10^4$	$5 \times 10^3$	$9 \times 10^3$
3	$24 \times 10^5$	-	-	-	-
4	$77 \times 10^3$	-	-	-	-
5	$5 \times 10^6$	$5 \times 10^7$	-	-	-
6	$1 \times 10^5$	-	-	-	-
7	$9 \times 10^3$	-	-	-	-

\* MLN: Mesenteric lymph node.

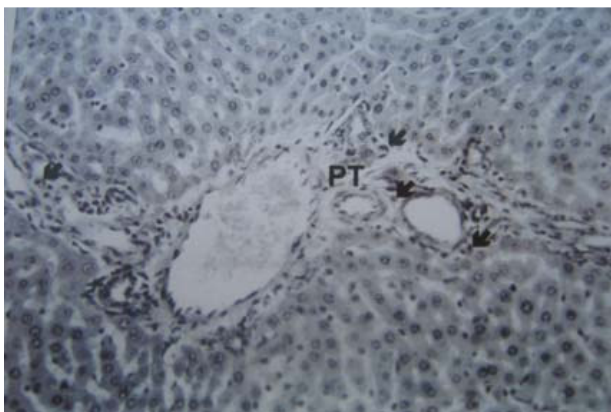
**Table 2.** Bacteriologic, histopathologic examination results and peripheral blood count of the cisplatin administered group and controls.

Bacteriologic examination	Cisplatin group	Control	Correlation coefficient/p
Blood	1/8	-	-
MLN*	2/8	1/7	0.229
Liver	-	1/7	-
Spleen	3/8	1/7	-
Ileum	7/8	7/7	0.724
Total	5/8	1/7	0.310
<b>Peripheral blood count</b>			
PMNL**	$32.000 \pm 7.92$	$28.000 \pm 6.42$	0.307
MNL***	$68.000 \pm 7.92$	$72.000 \pm 6.42$	0.307
<b>Histopathologic examination</b>			
Hemorrhage in liver	$1.37 \pm 0.916$	$1.37 \pm 1.25$	-
Infiltration with PMNLs in liver	$1.5 \pm 0.53$	$1.5 \pm 0.97$	0.800
Infiltration with PMNLs in ileum	$1.5 \pm 0.92$	$1.28 \pm 0.95$	0.578
Necrosis in ileum	-	-	-

\* MLN: Mesenteric lymph node,\*\* PMNLs: Polymorph nuclear leucocytes,\*\*\* Monocyte.



**Figure 1.** Light photomicrograph of small intestine for the animal (No: 10). IG: Intestinal glands, MM: Muscularis mucosae, SM: Submucosae, and polymorphonuclear leukocytes (arrows) were observed. (Hematoxylin & Eosin x 200)



**Figure 2.** Photomicrograph of liver for the animal (No: 11). PT: Portal triad, and polymorphonuclear leukocytes (arrows) were seen. (Hematoxylin & Eosin x 200)

bacteria, which are normally resident within the lumen of the intestinal tract, translocation across the intestinal epithelial barrier and act as a source of sepsis at distant sites. Many animal studies support this concept. A number of factors have been shown to predispose to bacterial translocation. These include shock with reduced splanchnic blood flow, burn, radiation, malignancy, cytotoxic drugs, antibiotic therapy, endotoxin and cytokines, starvation, parenteral nutrition, intestinal epithelial damage and antibiotic therapy.<sup>2,7-11</sup> Several steps occur in this process of translocation, including the attachment

of microbes to the gut mucosa, penetration through the gut epithelium in to the lamina propria, and transport to distal side.

In Naaber experimental study, bacterial translocation on late sepsis (after 48 h-5 day from intraperitoneal *E. coli* inoculation), was found lower than early sepsis (after 6-24 h from intraperitoneal *E. coli* inoculation). In the same study, the expression of histopathologic characteristics in individual animals no statistical difference.<sup>4</sup>

In our study, although to increase intestinal microflora *E. coli* isolate was administered each group, bacteraemia was not proven with blood culture apart from one sample.

Cancer, itself and radiotherapy and chemotherapy, may be cause immunosuppression.<sup>2,11</sup>

Cisplatin is the most important chemotherapeutic agent using cancer treatment. Nausea and vomiting are common cisplatin toxicities. These symptoms are cause limitation of oral intake during few days. Apart from moderate anemia, myelosuppression is rare complication in patient treated with cisplatin. Febrile neutropenia, was also not common clinical picture. According to our knowledge, cisplatin effect on bacterial translocation was not reported on the English language literature.

Previous reports showed that oral intake limitation could be cause bacterial translocation. Because of nausea and vomiting in patients with treated cisplatin oral intake decreases. To provide same effect, before and after 24 h from administration cisplatin, food and drink were not given to each group.

The presented study was shown that cisplatin administration was not cause the bacterial translocation. This can be explained with cisplatin have not adversely affected such as increasing intestinal epithelial permeability.

Our results may be imply that patients treated with cisplatin have not risk systemic infection because of bacterial translocation.

## REFERENCES

1. Deitch EA, Berg RD. Bacterial Translocation from gut: A mechanism of infection. *J Burn Care Rehab* 1987;8:475-82.
2. Liethman MS. Bacterial translocation in humans. *J Pediatr Gastroenterol Nutr* 2001;33:1-10.
3. Demircan O, Köksal F, Gönluşen G, Erkoçak E, Öztürk C, Ergin E. Splenektomi yapılan sıçanlarda endoksinle uyarılan bakteriyel translokasyon. *Çukurova Üniversitesi Tıp Fakültesi Dergisi* 1998;23(1):4-10.
4. Naaber P, Smidt I, Tamme K, et al. Translocation of indigenous microflora in an experimental model of sepsis. *J Med Microbiol* 200;49:431-9.
5. Hande KR. Chemotherapy in Lung Cancer: Principles and Practice. In: Pass HI, Mitchell J, Johnson D, Turrisi A, Minna J, eds. Philadelphia: Lippincot Williams & Wilkins; 2000. p.270-83.
6. Kodner IJ, Fry RD, Fleshman JW, Birnbaum EH. Colonic microflora. In: Schwartz SI, ed. Principles of Surgery. New York: McGraw-Hill; 1994. p.1200.
7. Moore AF, Moore EE, Pogetti RS, et al. Postinjury shock and early bacteremia; a lethal combination. *Arch Surg* 1992;127:893-8.
8. Pohlson EC, Suehiro A, Ziegler EJ, Suehiro G, McNamara JJ. Antiserum to endotoxin in hemorrhagic shock. *J Surg Res* 1988;45:467-71.
9. Baykal A, Iskit AB, Kaynaroğlu V, Güç O, Hascelik G, et al. Adrenalin tolerance does not prevent bacterial translocation in a murine burn model. *Int Surg* 2000;85:18-22.
10. Berg RD. Promotion of the translocation of enteric bacteria from the gastrointestinal tracts of mice by oral treatment with penicilin, clindamycin or metronidazole. *Infect Immun* 1981;33:845-61.
11. Fox Ad, Kripke SA, De Paula J, et al. Effect of glutamine-supplemented enteral diet on methotrexate-induced enterocolitis. *J Parenter Enteral Nutr* 1988;12:325-31.