

The Effects of Alpha-Tocopherol on Stress-Induced Ulcers in Rats

STRES ÜLSERLİ SIÇANLARDA E VİTAMİNİNİN ETKİLERİ

Kevser EROL*, Serkan BOYDAĞ*, Fatma Sultan KILIÇ*, Varol ŞAHİNTÜRK**, Duygu KOYUNCU**, Ergin AÇIKALIN**

* Department of Pharmacology, Osmangazi University School of Medicine,

**Department of Histology, Osmangazi University, School of Medicine, Eskişehir, TURKEY

Summary

Various mechanisms are involved in the development of stress ulcers including mucosal ischemia, bile refluxes and acid hypersecretion. The oxidation of arachidonic acid may occur and free radicals may be released during mucosal ischemia. In this study, the effects of alpha-tocopherol which is a scavenger on stress induced gastric lesions were investigated. Cold + immobilization test was used for the formation of stress lesions. The ulcerations were evaluated in two sets of experiments by using mean ulcer index in one and microscopic examination in the other. One, 5 and 25 mg/ kg alpha-tocopherol were injected intraperitoneally for three days and the gastroprotective effects were compared. 5 mg/kg alpha-tocopherol was the most effective dose in the protection of ulcer lesions.

Key Words: Alpha-tocopherol, Stress ulcer, Rats

T Klin J Med Res 2001, 19:140-145

Physical stress has been associated with several manifestations including gastric ulcerations. The increase of stress-induced ulcerations has been an important investigation area for modern society and public health. Various mechanisms are involved in the development of stress ulcers including mucosal ischemia, bile refluxes and acid hypersecretion (1). Most authorities agree that initial events in stress ulcer formation are hypoperfusion and mucosal ischemia (2,3). The gastric microcirculation is considered as a critical component of gastric mucosal defence. Stress is a highly inductible event for production of free oxygen radicals which generated by

Received: April 5, 2001

Correspondence: Kevser EROL

Dept. of Pharmacology
Osmangazi University School of Medicine
26480, Eskişehir, TURKEY

Özet

Stres ülseri oluşumunda mukozal iskemi, safra reflüsü ve asid hipersekresyonu gibi çeşitli mekanizmalar sorumludur. Mukozal iskemi sırasında serbest radikaller salınabilir veya arachidonik asid oksidasyonu olabilir. Bu çalışmada, strese bağlı gastrik lezyonlarda bir serbest oksijen süpürücü olan alfa-tokoferol (E Vitamini)'ün etkileri incelenmiştir. Stres lezyonlarının oluşumu için soğuk + immobilizasyon testi kullanıldı. Deneysel 2 ayrı deney seti halinde yapıldı. Ülserler birincisinde ortalama ülser indeksi kullanılarak ve ikincisinde ise mikroskopik inceleme ile değerlendirildi. Üç gün süre ile 1, 5, 25 mg/kg alfa tokoferol periton içine injekte edildi. Gastroprotektif etkileri birbirleriyle karşılaştırıldı. 5 mg/kg alfa-tokoferol ile ülser lezyonlarında en iyi koruyucu etki gözlemlendi.

Anahtar Kelimeler: Alfa tokoferol, Stres ülseri, sıçan

T Kim Araştı- ma 2001, 19:140-145

oxidative burn in all body tissue and may be harmful to gastric cells (4,5). Vitamin E is known to have function as a free radical scavenger that prevents oxidation of essential cellular constituents or the formation of toxic oxidation products such as the peroxidation products formed from unsaturated fatty acids (6). Vitamin E has been shown to have protective effect in myocardial infarction, ischemic coronary heart disease (7), progression of the neurological abnormalities (8). Considering all the above factors, the present study was undertaken to examine the effects of a-tocopherol on stress-induced gastric ulcers in rats.

Material and Methods

Morphometric evaluation of gastric mucosal damage

40 albino rats of either sex, weighing 180-200 g were used in the first set of the present study. The

rats were divided into five groups of eight animals. They were fed on standard chow diet. The distribution of animals in groups and the treatment were randomized. Animals were pretreated with 0.2 ml intraperitoneal injection of dimethylsulfoxide (DMSO) or a-tocopherol diluted in DMSO, at 1, 5 or 25 mg/kg doses for three days. These animals were fasted for 16 hours before the stress, but had access to water ad libitum. Sixty minutes after the last injection the rats were immobilized in restraint cages and exposed to a temperature of 4°C for 4 hours. The animals were then killed by an overdose of ether. Their stomachs were removed, cut open along the greater curvature and examined for measurement of mucosal lesions. Each lesion was measured along its greatest diameter (mm). When assessing the size of petechiae, five such lesions were considered equivalent to 1 mm ulcer. The sum of the lesions lengths in each group was divided by the number of rats in that group and expressed as mean ulcer index (9).

Measurement of Gastric Mucus

The method described by Corne et al (1974) was followed. Briefly after macroscopic assessment, the glandular segments of the stomach which included corpus and antrum were separated from the rumen of the stomachs and weighed. Each segment was soaked for 2 hour in 10 ml 0.1% Alcian blue dissolved in 0.16 M sucrose buffered with 0.05 M sodium acetate adjusted to pH:5.8 with 1 M HCl. Uncomplexed dye was removed by two successive washes of 15 and 45 min in 10 ml 0.25 M sucrose. Dye complexed with mucus was eluted by immersion in 10 ml aliquots of 0.5 M MgCl₂, which was shaken intermittently for 1 min at 30 min intervals for 2 hours. 4 ml of the blue extract solution were then shaken vigorously with an equal volume of diethylether. The resulting emulsion was centrifuged at 3600 rpm for 10 min. The optical density of 2 ml aqueous layer was determined at 598 nm. Alcian blue recovery recorded as optical density was converted into micrograms of Alcian blue solutions. The quantity of Alcian blue extracted per gram of wet glandular tissue was then calculated (10,11).

Microscopic evaluation of gastric mucosal damage

In the second set of experiments 21 rats were divided into 4 groups (stress group included 6, and

the others included 5 rats) and animals were prepared as in the method mentioned above. After killing the animals the stomach tissue was then fixed in 10% neutral formaline and embedded in paraffin. Sections from tissue blocks taken from ulcerated areas were stained with hematoxylin-eosin and (PAS: Perodic acid-Schift) in Carnoy fixative for routine histologic examination. Epithelial injury, polymorphonuclear leucocytes (PMNL) infiltration, congestion and parietal cell eosinophilia were scored on sets of serial sections for each rat as to the following scale:

0: Absent	+: light
++: mild	+++: severe

Experiments were accepted by Osmangazi University, School of Medicine, Animal Use and Care Committee.

Statistics

The data are expressed as mean \pm SEM. Statistical analysis were performed using student's t test for ulcer index and mucus secretion, Kruskal-Wallis test and Hollender-Wolfe multiple comparison tests for histological data.

Results

Cold-Restraint stress-induced lesions

The animals subjected to restraint and cold for 4 hours showed the ulcerogenecity in the form of hemorrhagic mucosal lesions in the glandular segments of their stomachs. The intraluminal bleeding was also observed in these animals.

Table 1 shows the effects of a-tocopherol on stress lesions formation.

a-Tocopherol decreased stress-induced acute hemorrhagic gastric lesion formation dose-dependently at the doses of 1 and 5 mg/kg ($p < 0.05$). But the protective activity of a-tocopherol reduced at 25 mg/kg dose. a-Tocopherol, given at 5 mg/kg dose elevated the mucus content, but the difference was insignificant and diminished mucosal damage. 1 mg/kg dose of a-tocopherol was not enough to elevate the gastric mucus secretion, but enough to decrease the mean ulcer index ($p < 0.05$). The most gastroprotective activity of a-tocopherol was observed at 5 mg/kg dose in regard to mean ulcer

Table 1. Effects of alpha- tocopherol on stress lesions formation

GROUPS	Mean Ulcer Index (mm)	Gastric wall mucus ug Alcian blue / g wet glandular tissue
Control	0.00 ± 0.00	529 ± 62
Stress	11.75 ± 1.09 +	288 ± 39 +
1 mg/kg a-Tocopherol	5.17 ± 1.41 *	283 ± 59 +
5 mg/kg a-Tocopherol	3.00 ± 1.29 *	390 ± 75
25mg/kg a-Tocopherol	7.25 ± 1.40 *	350 ± 28 +

p<0.05 as compared to stress group
 : p<0.05 as compared to control group

index and gastric mucus secretion (p<0.05) (Table 1).

Light microscopic evaluations

Table 2 shows the scores of the animals. There is no significant difference between the groups in regard to epithelial injury, PMNL infiltration and congestion (P>0.05). But parietal cell eosinophilia in the group given 5 mg/kg a-tocopherol was less than the other groups (p<0.05). Representative photographs of the mucosa in a stressed rat show epithelial damage (Figure 1 A) and decrease of gastric mucus secretion (Figure 1B). Figure 2 and 3 show the protective activity of a-tocopherol of 1 and 5 mg/kg doses. But 25 mg/kg dose of a-tocopherol produced the epithelial injury (Figure 4A) and reduced mucus secretion (Figure 4B).

Cold restraint stress significantly decreased the stomach wall mucus. Pretreatment of rats with a-

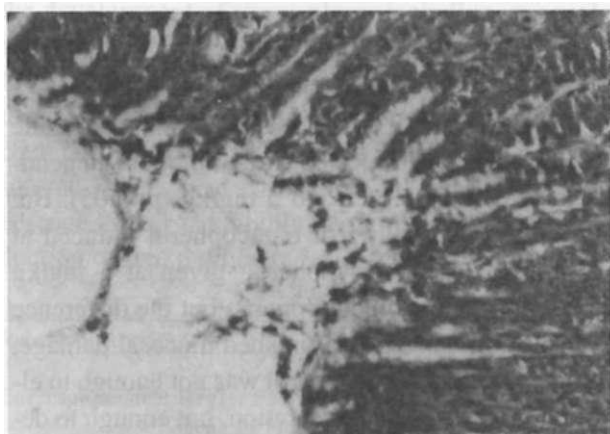


Figure 1A. Destruction of the gastric mucosal epithelium and epithelial cell necrosis. Group I, H-E, x 66.

Table 2. Histological scores of the animals

Groups Number of rats	Epithelial Damage	Increase of PMNL	Eozinophili of Congestion	Parietal Cell
Stress (I)				
1	++	++	+++	+++
2	+++	+++	++	-H-
3	+	+	++	++
4	+	++	+	I +++
5	0	+	0	* ++
6	0	+	+	++
1 mg/kg a-T (II)				
1	0	+	+	+
2	+	+	++	+
3	+	+	++	++
5	0	++	++	0
5	0	0	+	+
5 mg/kg a-T (III)				
1	0		+	0
2	0	++	++	
3	0	0	0	0
4	0	+	+	0
5	0	0	0	0
25 mg/kg a-T (IV)				
1	++	+	++	+
2	0	0	+	++
3	+	+	++	++
4	+	+++	++	
5	0	+	++	+++

0: Absent +: Light ++ : Mild +++: Severe

tocopherol reduced the ulceration at 1 and 5 mg/kg doses. But the gastroprotective activity of a-tocopherol reduced at 25 mg/kg dose.

Discussion

Alpha-Tocopherol showed biphasic effect on the stress induced ulcerations. It reduced (dose dependently) acute hemorrhagic lesions at low doses

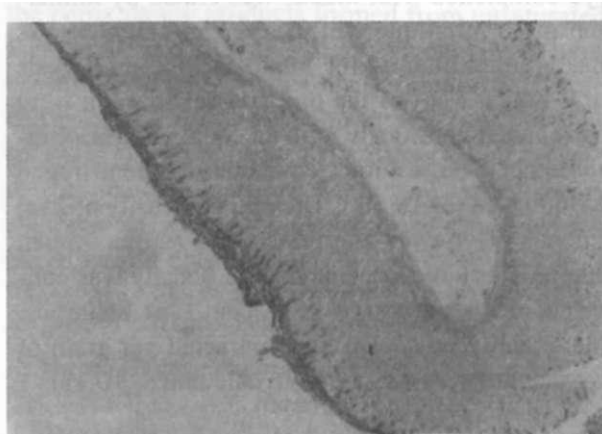


Figure 1B. Partial loss of the gastric surface mucous layer and reduction of mucous secretion. Group I, PAS technique,x13.2.

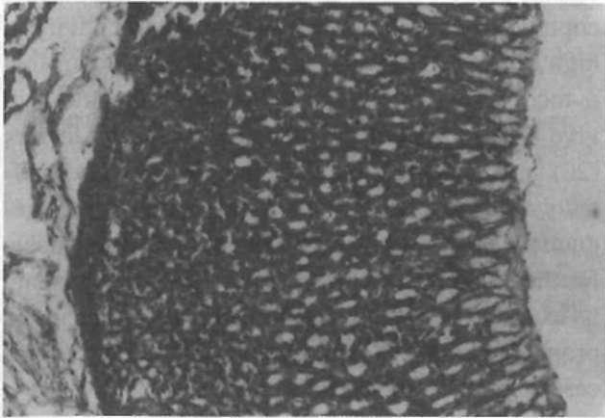


Figure 2A. Normal gastric mucosa. Group II, H-E, x 33.

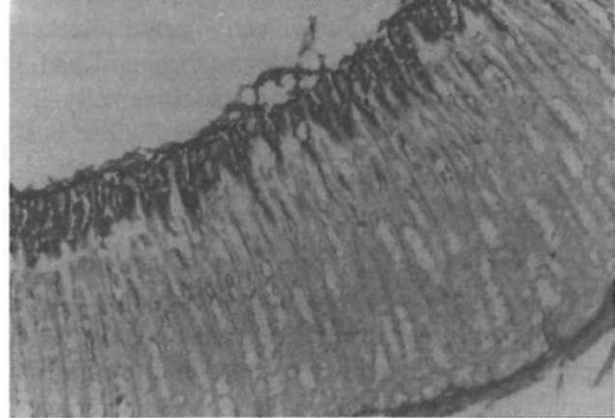


Figure 2B. Protected gastric surface mucous layer and normal mucous secretion. Group II, PAS technique, x 33.

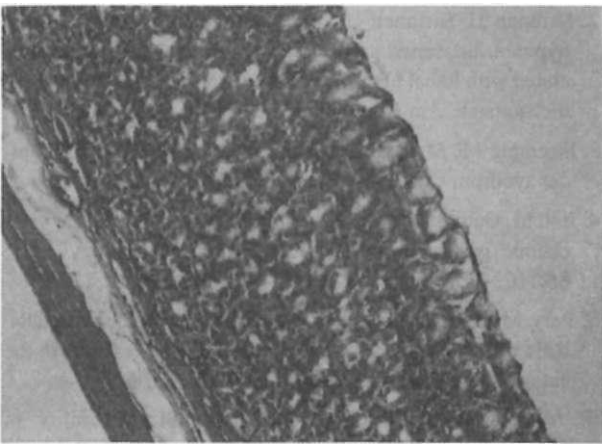


Figure 3A. Protected gastric mucosa. Group III, H-E, x 33.

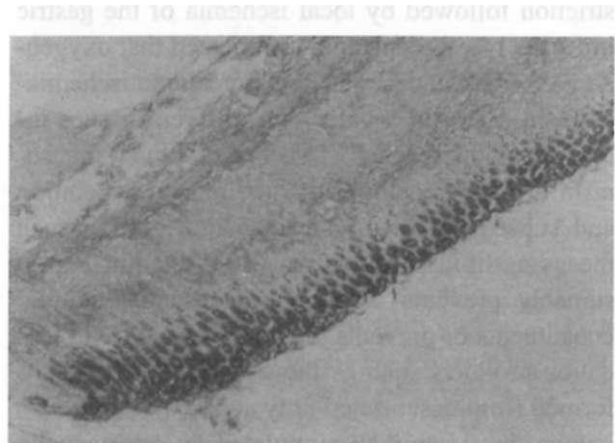


Figure 3B. Normal gastric mucous secretion Group III, PAS technique, x 13.2.

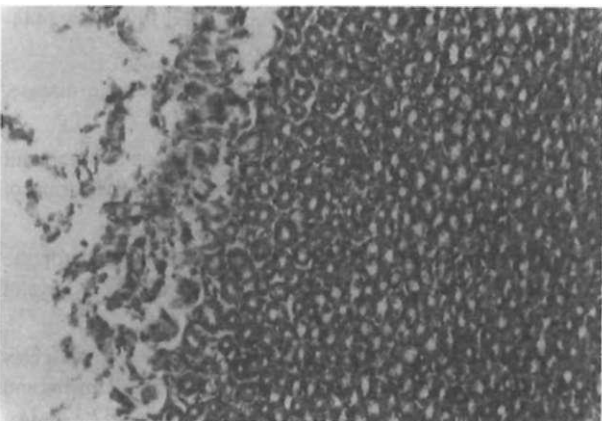


Figure 4A. Destruction of the gastric surface epithelium and the gastric glands. Group IV, H-E, x 33.

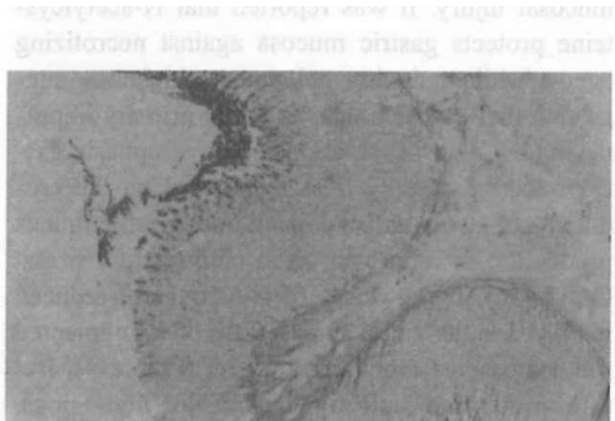


Figure 4B. Reduced mucus secretion and partial loss of the surface mucous layer Group IV, PAS technique, x 13.2

(1 and 5 mg/kg) but this protective activity lacked at high dose (25 mg/kg). Alpha-tocopherol had a function in protection against experimentally induced gastric lesions. Several direct or indirect possible mechanisms may exist in its protective activity.

Numerous theories have been forwarded to the pathophysiology of stress ulcer formation (12,13). The following pathogenic mechanisms have been reported to account for the stress-induced gastric lesions; disturbance of gastric mucosal microcirculation, hypersecretion of gastric acid, alteration of the gastric mucosal barrier, abnormal gastric motility and back diffusion of hydrogen ions. Stress ulcer formation is initiated by acute gastric vasoconstriction followed by local ischemia of the gastric mucosa (14). Recent studies indicated that oxygen-derived free radicals play a major role in ischemia-induced injury in a variety of different tissues including stomach (11,15,16). The dominant mechanism of injury has been oxygen radical generation and subsequent membrane damage through such means as lipid peroxidation (15). Vitamin E presumably prevents oxidation of essential cellular constituents or prevents the formation of toxic oxidation products such as the peroxidation products formed from unsaturated fatty acids (6). It was also known that vitamin E stimulated the prostacyclin production (17). Mucus is thought to act as an effective barrier to acid and pepsin digestion (11). However there is a considerable controversy regarding the role of mucus in prevention of gastric mucosal injury. It was reported that N-acetylcysteine protects gastric mucosa against necrotizing agents while reducing gel mucus thickness, suggesting that gastric mucus is not of primary importance (18). Our observations show a biphasic gastroprotective activity of α -tocopherol on the production of stress-induced ulceration. Gastric mucus production in rats exposed to cold-restrain stress. One and 5 mg/kg doses of α -tocopherol reduced the ulcer index and 5 mg/kg dose of it augmented the decrease of mucus production (Figure 4). But this protective activity lacked at high dose. Stimulation of cytoprotective prostanoids and prevention of the formation of toxic oxidation products may help the gastroprotective activity of α -to-

copherol. But the lack of this beneficial activity at high dose was very interesting. It was known that α -tocopherol inhibited the platelet aggregation in vivo (19) and vitamin K-dependent clotting factors (20) and had a prohemorrhagic action (6). These effects of α -tocopherol may be responsible for the reduction of gastroprotective activity at high dose. Further studies seems to be necessary to elucidate its exact mode of action and therapeutic value in the prophylaxy and / or in treatment of peptic ulcer diseases.

REFERENCES

1. Kumashiro R. Antiplatelet aggregators inhibit development of stress ulcer in sprague dawley rats. *Eur Surg Res* 1985;17:44-52.
2. Skilman JJ, Bushnell LS, Goldman H. Respiratory failure, hypotension, sepsis and jaundice: a clinical syndrome associated with lethal hemorrhage from acut stress ulceration of the stomach. *Am J Surg* 1969;117:523-8.
3. Stremple J F, Mori H, Lee R, Jerzy-Glass GB. The stress ulcer syndrom *Curr Probl Surg* 1973:1-64.
4. Itoh M, Gath P H :Role of oxygen derived free radicals in ischemic gastric injury in the rat. *Gastroenterology* 1985; 88:1162-7.
5. Pery MA , Wadhwa S, Parks DA, Pickard W, Granger DN. Role of oxygen radicals in ischemic-induced lessions in the cat stomach. *Gastroenterology* 1987; 92:950-6.
6. Marcus R, Coulston AN. Fat-Soluble Vitamins in Goodman's & Gilman's *The Pharmacological Basis of Therapeutics* In: Hardman JG, Limbert LE, Molinof PB, Ruddon RW, Gilman AG, eds. 9th ed. New York: Mc Graw Hill, 1996: 1573-90.
7. Stampfer MJ, Hennekens CH, Manson JE, Colditz GA, Rosner B, Willet WC. Vitamin E consuption and the risk of coronary disease in woman. *N Engl J Med* 1993; 328; 1444-9.
8. Sokol RJ. Vitamin E deficiency and neurologic disease. *Annu Rev Nutr* 1998;8:351-73.
9. Ogle J, Cho C, Tong M, Koo M. The influence of Verapamil on the gastric effects of stress in rats. *Eur J Pharmacol* 1985;112:399-404.
10. Corne SJ, Morrisney SM, Woods RJ. A method for the quantitative estimation of gastric barrier mucus. *J Physiol Lond* 1974; 242:116p-117p.
11. Koo MWL, Ogle CW, Cho CH. Effects of verapamil, carbenoxolone and N-acetylcysteine on gastric wall mucus and ulceration in stressed rats. *Pharmacology* 1986;32:326-34.
12. Matsumato T, Kaibara N, Sugimach K et al. Pathophysiology and management of acute gastric mucosal hemorrhage. *Jpn J Surg* 1978;8:261-9.

13. Murakami M, Lam SK, Inada M, Miyake T. Pathophysiology and pathogenesis of acute gastric mucosal lesions after hypothermic restraint stress in rats. *Gastroenterology* 1985;88:660-5.
14. Langman A, Kumoshiro R, Kliolously A M, Matsumoto T. Inhibition of stress ulcer formation by aminophylline in rats. *The American Surgeon* 1983;49:428-31.
15. Cochrom T. Dimethylsulfoxide protection against gastric stress ulceration. *Curr Surg* 1983;40:435-7.
16. Bootche W, Goloska EM, Kaufman GL. N-acetylsisteine affords gastric mucosal protection while reducing gel mucus thickness. *Surg Forum* 1982;33:164-6.
17. Kayaalp S. *Tıbbi Farmakoloji*, Feryal Matbaacılık, Ankara, 1997; 3:2893.
18. Robert A, Bottcher W, Golanska E, Kauffman GL. Lack of correlation between mucus gel thickness and gastric cytoprotection in rats. *Gastroenterology* 1985;86:670-4.
19. Jandak J, Steiner M, Richardson PD. Alpha-tocopherol an effective inhibitor of platelet adhesion. *Blood* 1989; 73(1):141-9.
20. Dowd P, Zheng ZB. On the mechanism of the anticlotting action of vitamin E quinone. *Proc Natl Acad Sci USA* 1995;8171-5.