

# Peripheral Dentinogenic Ghost Cell Tumor: Evaluation of Clinical, Histopathologic and Radiological Findings: Case Report

## Periferal Dentinojenik Hayalet Hücreli Tümör: Klinik, Histopatolojik ve Radyolojik Bulguların Değerlendirilmesi

Filiz NAMDAR PEKİNER,<sup>a</sup>  
Bedrettin Cem ŞENER,<sup>b</sup>  
Birsay GÜMRÜ,<sup>a</sup>  
Vakur OLGAÇ,<sup>c</sup>  
M. Oğuz BORAHAN<sup>a</sup>

Departments of

<sup>a</sup>Oral Radiology,

<sup>b</sup>Oral and Maxillofacial Surgery,

Marmara University Faculty of Dentistry,

<sup>c</sup>Department of Oncologic Cytology and

Tumor Pathology,

Istanbul University, Institute of Oncology,  
Istanbul

Geliş Tarihi/Received: 28.02.2011

Kabul Tarihi/Accepted: 07.12.2011

Yazışma Adresi/Correspondence:

Filiz NAMDAR PEKİNER

Marmara University Faculty of Dentistry,

Department of Radiology, Istanbul,

TÜRKİYE/TURKEY

fpekiner@yahoo.com

**ABSTRACT** The dentinogenic ghost cell tumor is a rare solid variant of the calcifying odontogenic cyst. A 77-year-old man presented with a gingival mass on the alveolar crest mucosa of canine to first premolar of the right mandibular region. After clinical and radiological examination, the pre-diagnosis was peripheral ossifying fibroma. An incisional biopsy was performed, and the specimen was submitted for histopathologic evaluation. The lesion was characterized histopathologically by ameloblastoma-like odontogenic epithelial proliferation, presence of ghost cells and dentinoid material. It was finally diagnosed as peripheral dentinogenic ghost cell tumor after excision with a margin of sound bone. In this report, a rare new case is described and the relevant literature is briefly reviewed.

**Key Words:** Odontogenic tumors; odontogenic cyst, calcifying; tomography

**ÖZET** Dentinojenik hayalet hücreli tümör, kalsifiye odontojenik kistin nadir bir solid varyantıdır. Yetmiş yedi yaşında erkek hasta, sağ mandibular bölgede birinci premoların yanındaki köpek dişinin alveol kret mukozası üzerinde gingival bir kitle ile başvurdu. Klinik ve radyolojik muayeneye göre başlangıçta periferel ossifiye fibrom tanısı konuldu. İnsizyonel biyopsi yapılarak, alınan örnek histopatolojik değerlendirmeye gönderildi. Lezyonun, histopatolojik olarak artış gösteren ameloblastik hücrelere benzer odontojenik hücreler, hayalet hücreler ve dentinoid materyal içerdiği gözlemlendi. Histopatolojik olarak periferel dentinojenik hayalet hücreli tümör tanısından sonra lezyon cerrahi olarak eksize edildi. Bu yazıda nadir olarak izlenen dentinojenik hayalet hücreli tümör olgusu tanımlandı ve konuyla ilgili literatür kısaca gözden geçirildi.

**Anahtar Kelimeler:** Odontojenik tümörler; odontojenik kist, kireçlenici; tomografi

**Türkiye Klinikleri J Med Sci 2013;33(2):530-6**

Since Gorlin and his colleagues described the calcifying odontogenic cyst (COC), numerous additional reports dealing with this unusual odontogenic lesion have appeared in the literature.<sup>1-12</sup> In 1971, the World Health Organization described the COC as a non-neoplastic cystic lesion; nevertheless, they classified it under the category of benign tumors related to the odontogenic apparatus.<sup>1</sup> COCs account only for 1% to 2% of all odontogenic tumors, and only 2% to 14% of all COCs are solid tumors.<sup>13</sup> It has been proposed that COC sometimes grows to have a neoplastic potential. The histological variations led some authors to regard the lesion as a neoplasm to be qualified by several descriptive terms. These include cal-

cifying ghost cell odontogenic tumor, cystic calcifying odontogenic tumor, dentinogenic ghost cell tumor, dentinoblastoma, ameloblastic dentinoma, etc.<sup>1,5,14</sup>

Praetorius et al.<sup>4</sup> were the ones who first classified COC into cystic and neoplastic (solid) types, referring to the cystic type of COC as *type 1* and the solid type as *type 2* in their study with 16 patients. They further classified the cystic type (type1) into the subtypes A, B and C\_ A denoting a simple cyst, B an odontome-producing cyst, and C a cyst with ameloblastomatous proliferation, and the term dentinogenic ghost cell tumor was proposed for the type 2 lesion.

Histologically, dentinogenic ghost cell tumor consists of ameloblastoma-like strands and islands of odontogenic epithelial proliferations infiltrating the bone and connective tissue. Ghost cells are present as well as varying amounts of dentinoid material, the latter being closely associated with odontogenic epithelium.<sup>1,15-19</sup> It occurs predominantly in old people and can present as a peripheral (in the gingival soft tissues outside bone) or central (intraosseous) lesion.<sup>8,9</sup>

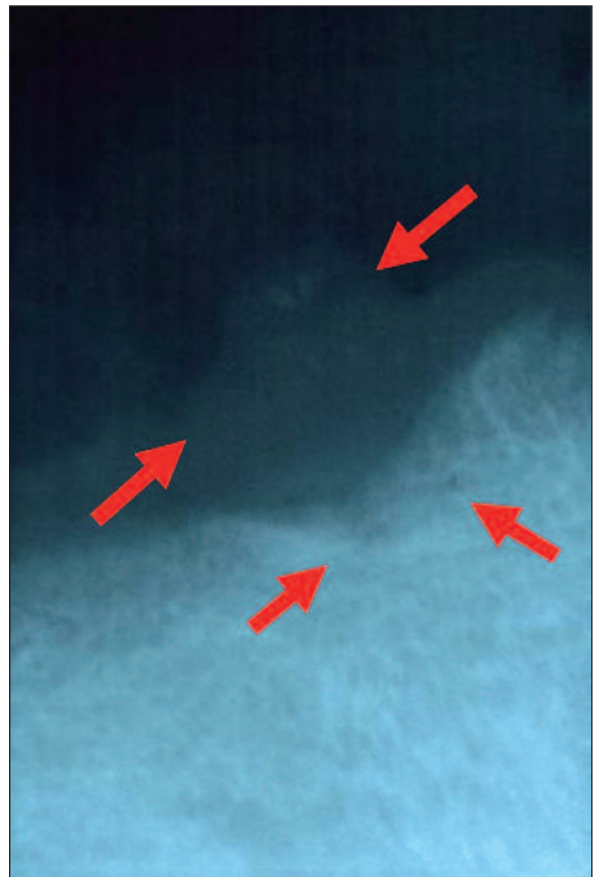The aim of this report is to present a new case of dentinogenic ghost-cell tumor and review the literature.

## CASE REPORT

A 77-year-old male was referred to the Marmara University, Faculty of Dentistry, Department of Oral Diagnosis and Radiology. He complained of a painless swelling on the lower jaw. He stated that the mass had been growing slowly over 5 years. Clinical examination revealed a hard mass of 1cm diameter on the alveolar crest mucosa of canine to first premolar of the right mandibular region, and the patient was found to be partially edentulous. Overlying mucosa was healthy and did not present any differentiation from surrounding tissue. Lymphadenopathies were not evident. The clinical features were nonspecific. The patient's medical and dental histories were non-contributory. A periapical radiograph showed a small radiolucent area in the right mandibular canine-premolar region and diffuse small opacities within the bulk of the lesion

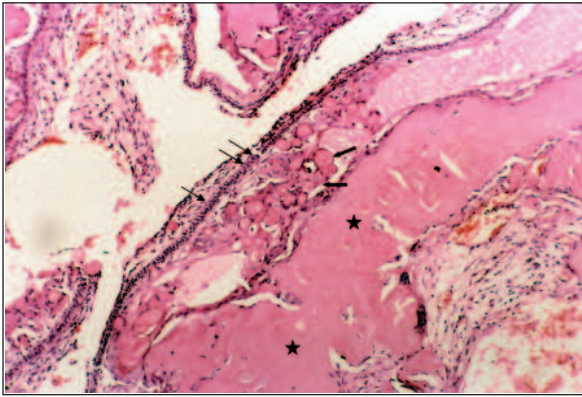
(Figure 1). According to the clinical appearance of the present lesion, it was initially considered as an irritation fibroma. However, this clinical diagnosis was changed after radiographic examination. The osteolytic lesion and the presence of small radiopacities within the lesion suggested a pre-diagnosis of peripheral ossifying fibroma. The patient was also requested to sign a written informed consent statement. An incisional biopsy was performed under local anesthesia. The specimen was sent for histopathological examination to Istanbul University, Institute of Oncology, Department of Oncologic Cytology and Tumor Pathology.

The gross specimen consisted of a yellowish piece of tissue, measuring 0.7x0.6x0.5 cm in size and had a firm consistency. Histopathologic features revealed a solid tumor with an overlying hyperplastic squamous epithelium. The ameloblastoma-

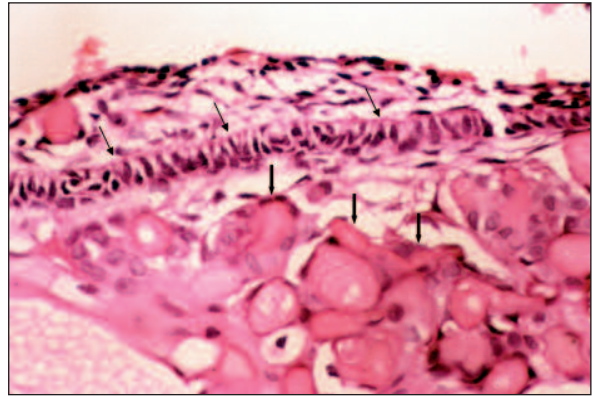


**FIGURE 1:** Periapical radiograph showing evidence of a radiolucent lesion with diffuse small opacities.

(See for colored form <http://tipbilimleri.turkiyeklinikleri.com/>)



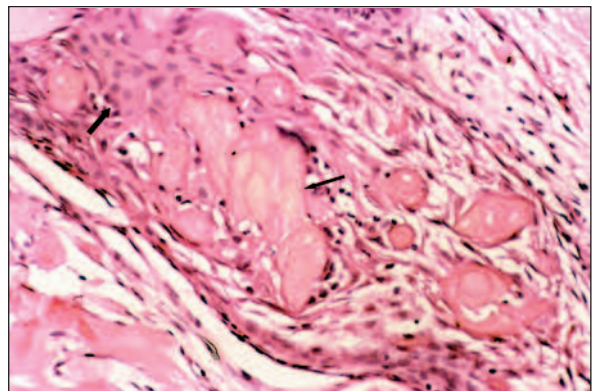
**FIGURE 2a:** Tumor mass with ghost cells (thick arrows) in the center and ameloblastic cells (thin arrows) surrounding the mass. Dentinoid material (stars) is seen neighboring the ghost cells (HE, x100).  
(See for colored form <http://tipbilimleri.turkiyeklinikleri.com/>)



**FIGURE 2b:** Ameloblastic cells (thin arrows) and stellate cells which differentiate into ghost cells (thick arrows) are shown (HE, x400).  
(See for colored form <http://tipbilimleri.turkiyeklinikleri.com/>)

like epithelial nests consisted of a layer of basaloid cells with stellate reticulum-type cells in the centrally. A considerable amount of ameloblastoma-like epithelial elements were noted in association with grouped ghost cells. Some areas showed cyst formation in the tissue sections. In focal areas, ghost cells tended to form stratified masses of variable thickness with several portions entrapped within areas of irregular dentinoid material (Figure 2 a-c). The histopathologic diagnosis was dentinogenic ghost cell tumor. In accordance with the histopathologic report, the treatment plan was changed to extensive resection of the lesion. Therefore the area was examined with computerized tomography (CT) imaging to evaluate bone involvement. The preoperative CT imaging revealed a radiolucent lesion with marked saucerization of the right mandibular canine to first premolar region (Figure 3 a-b). The present case showed a predominant peripheral type (gingival location) with intraosseous infiltration.

Surgery was performed under general anesthesia. A wide local surgical resection was performed with 5 mm safety margin at #42-45 region. The operation site was covered with rotational flap from the vestibular sulcus. The gross specimen consisted of a yellowish piece of tissue, measuring 1.5x0.5x3 cm and had a smooth bone tissue, measuring 1.5x1.0x0.8 cm. Histologically, these specimens were distributed in a fibrous connective



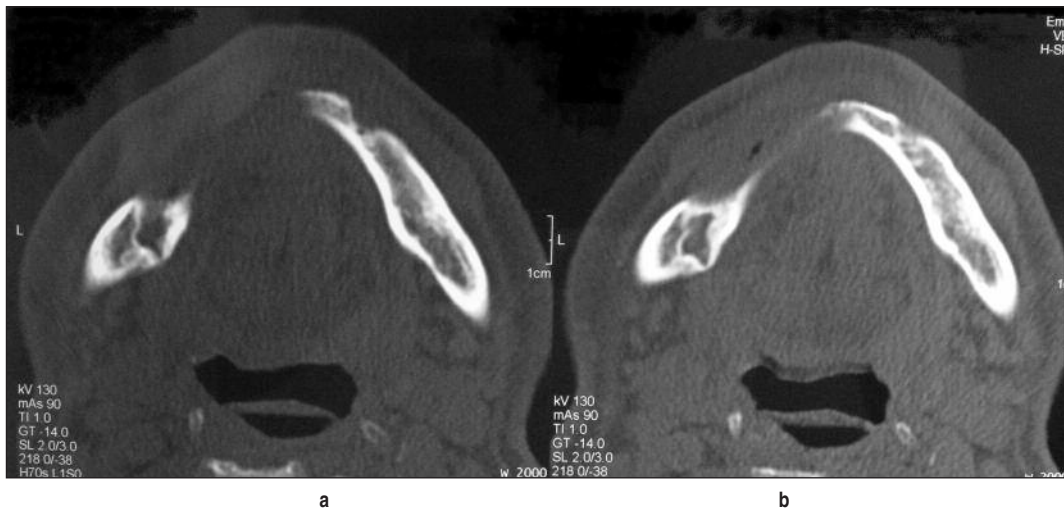
**FIGURE 2c:** Tumoral lesion formed by acanthomatous stellate cells (thick arrows) and ghost cells (thin arrows). (HE, x400).  
(See for colored form <http://tipbilimleri.turkiyeklinikleri.com/>)

tissue and nonspecific chronic inflammation. The patient was followed-up at the 1<sup>st</sup>, 2<sup>nd</sup> and 5<sup>th</sup> weeks after resection. No complication was observed at the operation site. Ten months of follow-up revealed no recurrences.

## DISCUSSION

Peripheral dentinogenic ghost cell tumor (DGCT) is an extremely rare odontogenic tumor.<sup>10,13-19</sup> Ellis<sup>20</sup> reported that the peripheral type is more common than the central type. The largest series was reported by Hong et al.; 8 of 92 cases of calcifying odontogenic cyst were identified as peripheral ghost cell tumors, and only 3 central ghost cell tumors were identified.<sup>21</sup> A case by Wong et al.





**FIGURE 3a, b:** Computerized tomography demonstrating an osteolytic lesion in the right mandibular region.

showed predominant peripheral location with central infiltration.<sup>9</sup> Radiologically, the peripheral DGCT causes no alteration or only mild erosion or saucerization of the cortical bones. The central DGCT has been described as a purely radiolucent or mixed radiolucent-radiopaque lesion. It is unilocular or multilocular and can manifest as either a well-demarcated or poorly defined lesion.<sup>16,19,21</sup> In our case, similar to published data of Wong et al., dentinogenic ghost cell tumor was located peripheral type with central infiltration.<sup>9</sup>

Histologically, DGCTs are composed primarily of ameloblastoma-like areas and odontogenic epithelial islands with varying amounts of ghost cells showing keratinization and calcification.<sup>4,17,22</sup> The most important histological feature of DGCTs that distinguishes it from conventional ameloblastoma and other odontogenic tumors is the presence of ghost cells and dentinoid substances.<sup>20,22</sup> Ghost cells are believed to be transformed into odontogenic epithelial cells, of which the mechanism is still unclear.<sup>17,21,22</sup> Although the presence of ghost cells is a defining feature for the diagnosis of DGCTs, these cells can also be observed in other tumors, such as pilomatricoma, odontoma, and ameloblastic fibro-odontoma.<sup>17,20,22</sup> The nature of the dentinoid substance found in DGCTs is composed of amorphous eosinophilic material containing widely separated cell bodies. It lacks the tubular structure of normal dentin, and appears as an irregular mass within the

connective tissue adjacent to the proliferation of odontogenic epithelium.<sup>20</sup> Another important differential diagnosis for DGCTs is the malignant odontogenic neoplasms. Malignant odontogenic neoplasms are rare; most carcinomas arising within odontogenic cysts have been diagnosed as squamous cell carcinomas.<sup>18,21</sup> Squamous cell carcinoma is defined by the presence of atypical cells with cytoplasmic keratinization, with either epithelial pearls or individual cell keratinization, and intercellular bridges. Distinctive “ghost” cells and dentinoid material are not associated with squamous cell carcinoma.<sup>18</sup> The case in this report is believed to fulfill the criteria of DGCT based upon the histological findings of ameloblastomatous-type epithelial components together with clusters of ghost cells and dentinoid association with the odontogenic epithelium.

In the initial histological diagnosis, it was difficult to diagnose, as only areas of dentinoid with dense fibrous connective tissue were seen, which was inconclusive for any diagnosis. In a immunohistochemical evaluation of a study of DGCTs, there was a strong positivity of the cells of the odontogenic epithelium for B-cell leukemia/lymphoma2 (Bcl-2) and a monoclonal antibody against the recombinant part of the Ki-67 antigen (MIB-1), whereas only a rare positivity for p53 was observed.<sup>23</sup> The ghost cells, giant cells, and dentinoid material were completely negative. In addition, typically, the clinical preoperative diagnosis was

suggestive of a reactive or inflammatory lesion (peripheral giant cell granuloma, pyogenic granuloma, epulis, or irritation fibroma). The clinical appearance of all of these lesions is similar;<sup>24,25</sup> therefore; this emphasized the importance of both histological and immunohistochemical examination in the biological aspect of DGCTs.

Dentinogenic ghost cell tumors are more common in the mandible. However, based on the current literature, it appears that most DGCTs are peripheral lesions arising in the extraosseous gingival or alveolar mucosa, and the canine to first premolar region is most frequently affected area although anterior and posterior segments of the jaws may also be involved (Table 1).<sup>4,7,9,10,13-15,17,24,26-28</sup> Most patients were older than 50 years of age and there was a slight predilection for men.<sup>3,9,14,20</sup> Patients were usually without symptoms, although a few have complained of pain or discomfort.<sup>9,14,15</sup> In the present case, patient's age, gender and localization of the lesion were similar to the published data.

Moreover, the patient could not use his partial denture, leading him to present with this complaint.

Stone et al. divided peripheral and central DGCTs into two subtypes: a) solid and b) aggressive or malignant subtype.<sup>18</sup> The solid subtype has infiltrative architectural features but is composed of cytological bland cells, similar to ameloblastoma, and has a high rate of local recurrence after limited local resection. The aggressive or malignant subtype, otherwise known as odontogenic ghost cell carcinoma combines architectural and cytological malignant features with prominent mitotic activity, infiltrative growth pattern, locally aggressive and destructive behavior. Although there is a question as to the true malignant nature of DGCTs, a peculiar subtype with malignant potential-the so-called aggressive or malignant DGCT, or odontogenic ghost cell carcinoma-has been recognized, with 16 cases reported in the English literature, distant metastasis is uncommon.<sup>3,16,20-22,29-35</sup> To date, only one case with pulmonary metastases has been

**TABLE 1:** Reported cases of peripheral dentinogenic ghost cell tumor.

Sl no:	Reference	No of Cases	Age in years/sex	Site	Radiographic features
1	Sauk <sup>15</sup>	1	67/F	Extraosseous	No significant findings
2	Praetorius et al. <sup>4</sup>	2	52/M	Maxillary left lateral incisor and canine region	Slight erosion of underlying bone
			41/F	Mandibular anterior region	Slight erosion of underlying bone
3	Hirshberg et al. <sup>10</sup>	1	42/M	Mandibular left premolar region (lingual gingiva)	No bone involvement
4	McClatchey et al. <sup>13</sup>	1	57/M	Mandibular anterior region	No bone involvement
5	Buchner et al. <sup>26</sup>	3	57/M	Mandibular central incisor	--
			53/F	Mandibular edentulous ridge	--
			92/F	Mandibular edentulous cuspid-premolar region	--
6	Günhan et al. <sup>17</sup>	1	71/F	Maxillary anterior region	Slight erosion of underlying bone
7	Raubenheimer et al. <sup>14</sup>	1	82/M	Mandibular right alveolar ridge (edentulous)	No bone involvement
8	Castro et al. <sup>7</sup>	1	83/F	Anterior ridge of edentulous mandible	Cup shaped resorption
9	Wong et al. <sup>9</sup>	1	71/M	Maxillary canine region	Slight erosion beneath the growth
10	Iezzi et al. <sup>24</sup>	1	43/M	Maxillary canine region	No bone involvement
11	Ledesma-Montes et al. <sup>27</sup>	1	NS	NS	NS
12	Candido et al. <sup>28</sup>	1	45/M	Mandibular canine region	No bone involvement
13	Our Case	1	77/M	Mandibular edentulous canine-premolar region	Slight erosion of underlying bone

NS: Not Specified.

reported.<sup>32</sup> In the present case, DGCTs was of the solid subtype.

Peripheral ghost cell tumors are easily excised and do not recur. In our case, we performed a wide local surgical mandibular resection with 5 mm safety margins on the saucerizing bone surface as the pathology report indicated no malignancy risk. Stone et al. reported that most peripheral DGCTs are not aggressive and can be controlled by local excision.<sup>18</sup> On the other hand, some central ones

are locally aggressive, similar to ameloblastomas.<sup>16,35</sup> If the tumor is radiographically well demarcated, curettage is probably sufficient. Radiographically ill defined and more destructive tumors should be treated by block or segmental resection of the jaw and long-term follow-up, including periodic CT, is essential.<sup>3,9,22,30,36,37</sup> A further study with more cases of DGCTs is necessary to clearly define its nature, clinical behavior and prognosis.

## REFERENCES

- Tajima Y, Ohno J, Utsumi N. The dentinogenic ghost cell tumor. *J Oral Pathol* 1986;15(6):359-62.
- Gorlin RJ, Pindborg JJ, Clausen FP, Vickers RA. The calcifying odontogenic cyst: a possible analogue of the cutaneous calcifying epithelioma of Malherbe. *Oral Surg Oral Med Oral Pathol* 1962;15:1235-43.
- Kasahara K, Iizuka T, Kobayashi I, Totsuka Y, Kohgo T. A recurrent case of odontogenic ghost cell tumour of the mandible. *Int J Oral Maxillofac Surg* 2002;31(6):684-7.
- Praetorius F, Hjørting-Hansen E, Gorlin RJ, Vickers RA. Calcifying odontogenic cyst. Range, variations and neoplastic potential. *Acta Odontol Scand* 1981;39(4):227-40.
- Fejerskov O, Krogh J. The calcifying ghost cell odontogenic tumor - or the calcifying odontogenic cyst. *J Oral Pathol* 1972;1(6):273-87.
- Mori M, Kasai T, Nakai M, Sato K, Takeuchi H, Takai Y, et al. Dentinogenic ghost cell tumor: histologic aspects, immunohistochemistry, lectin binding profiles, and biochemical studies. *Oral Oncol* 2000;36(1):134-43.
- Castro WH, de Aguiar MC, Gomez RS. Peripheral dentinogenic ghost-cell tumor: a case report. *Quintessence Int* 1997;28(1):45-7.
- Ide F, Obara K, Mishima K, Saito I. Ameloblastoma ex calcifying odontogenic cyst (dentinogenic ghost cell tumor). *J Oral Pathol Med* 2005;34(8):511-2.
- Wong YK, Chiu SC, Pang SW, Cheng JC. Peripheral dentinogenic ghost cell tumour presenting as a gingival mass. *Br J Oral Maxillofac Surg* 2004;42(2):173-5.
- Hirshberg A, Dayan D, Horowitz I. Dentinogenic ghost cell tumor. *Int J Oral Maxillofac Surg* 1987;16(5):620-5.
- Erdem E, Metin M, Dolanmaz D. [Calcifying odontogenic cyst: report of two cases]. *Turkiye Klinikleri J Dental Sci* 2000;6(3):150-4.
- Ertuş Ü, Tozoğlu S, Aktan B. Odontogenic cysts expanding to the maxillary sinus: a retrospective study. *Turkiye Klinikleri J Med Sci* 2009;29(4):845-50.
- McClatchey KD, Stewart JC, Patterson BD. Dentinogenic ghost cell tumor presenting as a gingival mass. *Ann Dent* 1988;47(1):31-2.
- Raubenheimer EJ, van Heerden WF, Sitzmann F, Heymer B. Peripheral dentinogenic ghost cell tumor. *J Oral Pathol Med* 1992;21(2):93-5.
- Sauk JJ Jr. Calcifying and keratinizing odontogenic cyst. *J Oral Surg* 1972;30(12):893-7.
- Colmenero C, Patron M, Colmenero B. Odontogenic ghost cell tumours. The neoplastic form of calcifying odontogenic cyst. *J Cranioaxillofac Surg* 1990;18(5):215-8.
- Günhan O, Sengün O, Celasun B. Epithelial odontogenic ghost cell tumor: report of a case. *J Oral Maxillofac Surg* 1989;47(8):864-7.
- Stone CH, Gaba AR, Benninger MS, Zarbo RJ. Odontogenic ghost cell tumor: a case report with cytologic findings. *Diagn Cytopathol* 1998;18(3):199-203.
- Lombardi T, Küffer R, Di Felice R, Samson J. Epithelial odontogenic ghost cell tumour of the mandibular gingiva. *Oral Oncol* 1999;35(4):439-42.
- Ellis GL. Odontogenic ghost cell tumor. *Semin Diagn Pathol* 1999;16(4):288-92.
- Hong SP, Ellis GL, Hartman KS. Calcifying odontogenic cyst. A review of ninety-two cases with reevaluation of their nature as cysts or neoplasms, the nature of ghost cells, and subclassification. *Oral Surg Oral Med Oral Pathol* 1991;72(1):56-64.
- Kim HJ, Choi SK, Lee CJ, Suh CH. Aggressive epithelial odontogenic ghost cell tumor in the mandible: CT and MR imaging findings. *AJNR Am J Neuroradiol* 2001;22(1):175-9.
- Piattelli A, Fioroni M, Di Alberti L, Rubini C. Immunohistochemical analysis of a dentinogenic ghost cell tumour. *Oral Oncol* 1998;34(6):502-7.
- Iezzi G, Rubini C, Fioroni M, Piattelli A. Peripheral dentinogenic ghost cell tumor of the gingiva. *J Periodontol* 2007;78(8):1635-8.
- Kumar U, Vij H, Vij R, Kharbanda J, Aparna I, Radhakrishnan R. Dentinogenic ghost cell tumor of the peripheral variant mimicking epulis. *Int J Dent* 2010;2010:519494.
- Buchner A, Merrell PW, Hansen LS, Leider AS. Peripheral (extraosseous) calcifying odontogenic cyst. A review of forty-five cases. *Oral Surg Oral Med Oral Pathol* 1991;72(1):65-70.
- Ledesma-Montes C, Gorlin RJ, Shear M, Praetorius F, Mosqueda-Taylor A, Altini M, et al. International collaborative study on ghost cell odontogenic tumours: calcifying cystic odontogenic tumour, dentinogenic ghost cell tumour and ghost cell odontogenic carcinoma. *J Oral Pathol Med* 2008;37(5):302-8.
- Candido GA, Viana KA, Watanabe S, Vencio EF. Peripheral dentinogenic ghost cell tumor: a case report and review of the literature. *Oral Surg Oral Med Oral Pathol Oral Radiol Endod* 2009;108(3):e86-90.
- McCoy BP, O Carroll MK, Hall JM. Carcinoma arising in a dentinogenic ghost cell tumor. *Oral Surg Oral Med Oral Pathol* 1992;74(3):371-8.
- Alcalde RE, Sasaki A, Misaki M, Matsumura T. Odontogenic ghost cell carcinoma: report of a case and review of the literature. *J Oral Maxillofac Surg* 1996;54(1):108-11.
- Kamijo R, Miyaoka K, Tachikawa T, Nagumo M. Odontogenic ghost cell carcinoma: report of a case. *J Oral Maxillofac Surg* 1999;57(10):1266-70.

32. Folpe AL, Tsue T, Rogerson L, Weymuller E, Oda D, True LD. Odontogenic ghost cell carcinoma: a case report with immunohistochemical and ultrastructural characterization. *J Oral Pathol Med* 1998;27(4):185-9.
33. Grodjesk JE, Dolinsky HB, Schneider LC, Dolinsky EH, Doyle JL. Odontogenic ghost cell carcinoma. *Oral Surg Oral Med Oral Pathol* 1987;63(5):576-81.
34. Ellis GL, Shmookler BM. Aggressive (malignant?) epithelial odontogenic ghost cell tumor. *Oral Surg Oral Med Oral Pathol* 1986;61(5):471-8.
35. Scott J, Wood GD. Aggressive calcifying odontogenic cyst--a possible variant of ameloblastoma. *Br J Oral Maxillofac Surg* 1989;27(1):53-9.
36. Sun G, Huang X, Hu Q, Yang X, Tang E. The diagnosis and treatment of dentinogenic ghost cell tumor. *Int J Oral Maxillofac Surg* 2009;38(11):1179-83.
37. Juneja M, George J. Dentinogenic ghost cell tumor: a case report and review of the literature. *Oral Surg Oral Med Oral Pathol Oral Radiol Endod* 2009;107(5):e17-22.