

# VEGF and COX-2 Expression in Endometrial Carcinoma

## Endometriyal Karsinomada VEGF ve COX-2 Ekspresyonu

Y. Azize GÖKSU EROL, MD, Assis.Prof.,<sup>a,b</sup>  
Çiğdem TOKYOL, MD, Assoc.Prof.,<sup>c</sup>  
Öner ÖZDEMİR, MD, Prof.,<sup>d</sup>  
Mehmet YILMAZER, MD, Assoc.Prof.,<sup>e</sup>  
Dağıştan Tolga ARIÖZ, MD, Assoc.Prof.,<sup>e</sup>  
Fatma AKTEPE, MD, Prof.<sup>c</sup>

<sup>a</sup>Department of Medical Genetics,  
Süleyman Demirel University  
Faculty of Medicine, Isparta

<sup>b</sup>Department of Histology and Embryology;

<sup>c</sup>Department of Pathology,

<sup>d</sup>Department of Obstetrics and Gynecology;  
Afyonkocatepe University

Faculty of Medicine, Afyonkarahisar

<sup>e</sup>Göztepe Research and Training Hospital,  
İstanbul

Geliş Tarihi/Received: 27.12.2010

Kabul Tarihi/Accepted: 10.10.2011

Yazışma Adresi/Correspondence:

Y. Azize GÖKSU EROL, MD, Assis.Prof.,  
Süleyman Demirel University  
Faculty of Medicine,  
Department of Medical Genetics, Isparta,  
TÜRKİYE/TURKEY  
yasemin.goksu@gmail.com

**ABSTRACT Objective:** Angiogenesis is a major factor in the development of solid tumors, such as endometrial cancer. Vascular endothelial growth factor (VEGF) and cyclooxygenase-2 (COX-2) are important cytokines that stimulate angiogenesis in vivo. The aim of the current study was to determine VEGF and COX-2 expression in endometrial adenocarcinomas and to investigate the relationship between these parameters and clinicopathologic parameters. **Material and Methods:** Sections obtained from paraffin-embedded tissues in archive material of 23 patients who were diagnosed with endometrial carcinoma were retrospectively evaluated. VEGF and COX-2 expression levels in tumor cells and surrounding stroma on the tumor samples were determined by immunohistochemistry. **Results:** VEGF and COX-2 were expressed both in the cytoplasm of tumor cells and in the stromal cells, but in a lower degree. There was a significant positive correlation between VEGF expressions of cancer cells and the stroma ( $r = 0.705, p < 0.01$ ). A negative correlation was found between histological grade of the tumor and VEGF expression of cancer cells ( $r = -0.622, p = 0.002$ ). A negative correlation was determined between myometrial invasion of the tumor and COX-2 expression of cancer cells ( $r = -0.441, p = 0.035$ ). **Conclusion:** Both VEGF and COX-2 were expressed by both tumor cells and stromal cells in endometrial cancer. While VEGF expression showed a negative correlation with the tumor grade, COX-2 expression exhibited a negative correlation with the myometrial invasion of the tumor. No correlation was determined between their expressions and other clinicopathologic prognostic parameters.

**Key Words:** Vascular endothelial growth factor A; cyclooxygenase-2; endometrial neoplasms; neovascularization, pathologic; immunohistochemistry

**ÖZET Amaç:** Anjiyogenez, endometriyal kanser gibi solid tümörlerin gelişiminde önemli bir faktördür. Vasküler endotelial büyüme faktörü (VEGF) ve siklooksijenaz-2 (COX-2) in vivo ortamda anjiyogenez uyarıcı önemli sitokinlerdir. Bu çalışmanın amacı, endometriyal adenokarsinomlarda VEGF ve COX-2 sunumlarının belirlenmesi ve bu parametrelerin klinikopatolojik parametrelerle ilişkisinin araştırılmasıdır. **Gereç ve Yöntemler:** Endometriyal karsinom tanısı almış 23 hastaya ait arşiv materyalindeki parafine gömülü dokulardan alınan kesitler geriye dönük olarak değerlendirildi. Tümör örneklerinde tümör hücreleri ve çevreleyen stromal dokuda VEGF ve COX-2 sunum düzeyleri immünohistokimyasal olarak saptandı. **Bulgular:** VEGF ve COX-2'nin hem tümör hücrelerinin sitoplazmasında hem de daha düşük derecede olmak üzere tümör stromasındaki hücrelerde sunulduğu görüldü. Kanser hücreleri ve stroma arasında VEGF sunumları açısından anlamlı bir pozitif ilişki vardı ( $r = 0,705, p < 0,01$ ). Tümörün histolojik derecesi ve kanser hücrelerinin VEGF sunumu arasında negatif bir ilişki bulundu ( $r = -0,622, p = 0,002$ ). Tümörün miyometriyal invazyonu ile kanser hücrelerinin COX-2 sunumu arasında negatif bir ilişki saptandı ( $r = -0,441, p = 0,035$ ). **Sonuç:** Hem VEGF'nin hem de COX-2'nin endometriyal kanserde tümör ve stromal hücreler tarafından sunulduğu saptanmıştır. VEGF sunumu tümörün derecesi ile negatif bir ilişki gösterirken; COX-2 sunumu tümörün miyometriyal invazyonu ile negatif bir ilişki sergilemiştir. Her iki göstergenin, diğer klinikopatolojik prognostik parametreler ile aralarında herhangi bir ilişki saptanmamıştır.

**Anahtar Kelimeler:** Damar endoteli büyüme faktörü A; siklooksijenaz-2; endometriyal tümörler; neovaskülarizasyon, patolojik; immünohistokimya

doi: 10.5336/medsci.2010-22258

Copyright © 2012 by Türkiye Klinikleri

Türkiye Klinikleri J Med Sci 2012;32(1):80-7

**E**ndometrial cancer (EC) is the most common cancer of the female genital tract and is estimated to account for 39,080 new cases and 7,400 deaths in 2007.<sup>1</sup> Angiogenesis is critical for the continuous growth of tumors and the development of metastases.<sup>2</sup> The initiation of angiogenesis is mainly regulated by the balance between proangiogenic and antiangiogenic molecules and it is an early and essential event in tumor development and progression.<sup>3,4</sup> Angiogenesis in uterine endometrial cancers is complicated because the hormone dependency in their growth also modifies the angiogenic potential. Therefore, angiogenic potential in uterine endometrial cancers must be thoroughly analyzed.

Vascular endothelial growth factor (VEGF), also known as vascular permeability factor, is a multifunctional cytokine that has been reported to be one of the most important growth factors that regulate vasculogenesis, hematopoiesis, and potentially stimulate angiogenesis lymphangiogenesis, and vascular permeability *in vivo*.<sup>5,6</sup> VEGF expression has been observed in a variety of tumor cell lines and in many types of human solid tumors.<sup>7-11</sup>

Moreover, current studies suggest a clinical significance of Cyclooxygenase-2 (COX-2) expression in various malignancies. Recently, it has been reported that COX-2 contributes to angiogenesis involved in tumor growth and advancement of various tumors such as colon cancers,<sup>12</sup> advanced ovarian serous carcinomas,<sup>13</sup> breast cancers,<sup>14</sup> renal cell carcinomas,<sup>15</sup> and gastric cancers.<sup>16</sup> Colon cancer cells with overexpressed COX-2 co-express VEGF, basic fibroblast growth factor (bFGF), transforming growth factor (TGF)- $\beta$  and platelet derived growth factor (PDGF).<sup>12</sup>

However, to our knowledge, there are a few data assessing the clinicopathologic relationship of VEGF and COX-2 with EC. We aimed to determine VEGF and COX-2 expression in EC and its relation to clinicopathologic implications in tumor prognosis.

## MATERIAL AND METHODS

### PATIENTS

We performed a retrospective study carried out on paraffin-embedded samples obtained from 23 EC

patients who had undergone hysterectomy at the Department of Obstetrics and Gynecology in our hospital. EC was histologically graded by two pathologists (FA and CT) according to the French Fédération Internationale de Gynécologie et d'Obstétrique (FIGO) grading system and was categorized in 3 grades: Grade 1,  $\leq 5\%$  non-squamous, non-morular growth pattern, Grade 2, 6-50% non-squamous, non-morular growth pattern, and Grade 3,  $>50\%$  non-squamous, non-morular growth pattern. Bizaar nuclear atypia raised the grade by one regardless of whether or not squamous or morular growth pattern.<sup>17</sup> Depth of myometrial invasion was divided into 2 subsets: Stage IA, none or less than half-thickness of myometrial invasion, Stage IB, invasion equal to or exceeding half-thickness of myometrium. Cervical invasion without stromal involvement was classified as stage I. A tumor invading the cervical stroma, but not extending beyond the uterus was classified as Stage II according to the TNM and FIGO staging.<sup>18</sup> The ages of patients were between 32 and 81 years. The ages were classified into two groups; Group I  $49 \geq$  and Group 2  $49 <$ .

A total of 23 tumor tissues were analyzed. Thirteen cases were grade 1, 7 cases were grade 2, and 3 cases were grade 3. All cases were endometrioid type and Stage I. Eighteen cases were Stage IA and 5 were Stage IB. Seven patients were  $\leq 49$  years of age, namely in group 1 and 16 cases were more than 49 years of age, namely in group 2.

### IMMUNOHISTOCHEMISTRY (IHC)

The streptavidin-biotin-peroxidase method was used for immunohistochemical staining. For each case of EC, representative blocks were selected. Four micrometer-thick sections were cut and were deparaffinized with xylene and ethanol. In both cases of VEGF and COX-2 staining, to retrieve the antigen, the deparaffinized slides were first heated in a microwave oven for 20 minutes in 1 mM ethylenediaminetetraacetic acid (EDTA) buffer (pH 8.0) for VEGF and in 10 mM citrate buffer (pH 6.0) for COX-2, followed by cooling at room temperature for 20 minutes. and washing twice with phosphate buffered saline (PBS). All sections were incubated with 30 mL/L hydrogen peroxide for 10

minutes to inhibit endogenous peroxidase and then were washed twice with PBS. After incubation with ultra V Bloc, sections were treated with primary antibody at room temperature using mouse monoclonal antibody against VEGF (Neomarkers, ThermoScientific, UK) and rabbit polyclonal antibody against COX-2 (Neomarkers, ThermoScientific, UK) for 30 and 20 minutes., respectively. The dilution for both antibodies was 1:100.

Sections were then incubated with biotinylated goat anti-polyvalent and streptavidin peroxidase each for 15 minutes at room temperature. The color was developed with 3-amino-9-ethyl-carbazole (AEC) (ThermoScientific) for 15 minutes at room temperature and the slides were counterstained with Mayer hematoxylin for 30 seconds.

#### ASSESSMENT OF VEGF AND COX-2 STAINING

Immunohistochemical staining for VEGF and COX-2 both in cancer cells and in the tumor stroma was evaluated semi-quantitatively for each case by two independent observers, one histologist and one pathologist (AYGE, CT) in a blinded fashion. When a disparity occurred between the final staining grades determined by two observers, both observers then re-evaluated the cases together in order to come to a common decision.

For both molecular markers, cytoplasmic staining was defined as positive in cancer cells. The percentage of immunoreactive cells was estimated using a score of 0-3 (0: 0-4% cells stained; 1: 5-29% cells stained; 2: 30-59% cells stained; and 3: 60-100% cells stained). The staining intensity was scored as 0-3 (0, negative; 1, weak; 2, moderate; 3, strong). Values for the quantity and staining intensity scores were then multiplied giving results that ranged from 0 to 9. In the stroma, we also used staining percentage and intensity, and obtained scores ranging from 0 to 9.

The expression levels of VEGF and COX-2 both in cancer cells and the stroma were reported according to the following scoring criteria: grade 1 (score 0); grade 2 (scores 1 to 3); grade 3 (scores 4 to 6); grade 4 (scores 7 to 9).<sup>19,20</sup> Staining grades for both VEGF and COX-2 in cancer cells and tumor

stroma were correlated with clinical parameters and with each other.

#### STATISTICAL ANALYSIS

Statistical analysis was performed by SPSS 11.0 for Windows software. The immunohistochemical data were reported as median (min-max) value. Bivariate correlation between variables was estimated by Spearman's correlation coefficients. A *p* value <0.05 was considered significant.

## RESULTS

#### VEGF EXPRESSION

VEGF was expressed in the cytoplasm of surface/epithelial cancer cells of EC in different staining grades with a median value of 3 (min:1-max:3). Immunoreactivity was also present in the stroma (Figure 1a), but at a lower degree with a median value of 2 (min:1-max:3) (Table 1). VEGF was also expressed in vascular endothelial cells. There was a significant positive correlation between cancer cell and stromal VEGF expressions ( $r=0.705$ ,  $p<0.01$ ). A negative correlation was detected between the histological grade of EC and VEGF expression of cancer cells ( $r=-0.622$ ,  $p=0.002$ ). Thus, patients with highly positive VEGF staining on cancer cells showed significantly lower histological grades (Figures 1a,b,c). However, there was no correlation between VEGF levels and myometrial invasion or age.

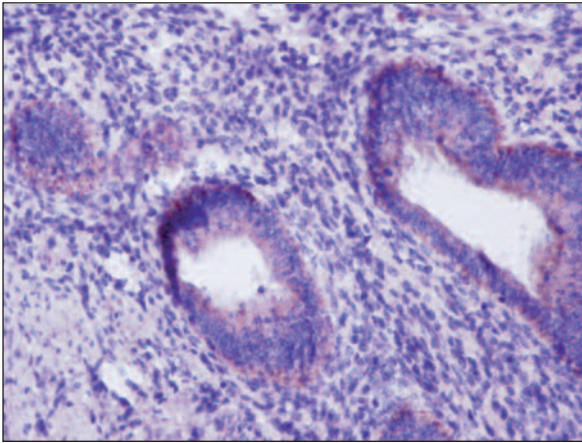
#### COX-2 EXPRESSION

Immunoreactivity was observed in the cytoplasm of surface and epithelial cancer cells. The median value of COX-2 staining grade was 4 (min:3-max:4), namely strong immunostaining was observed for COX-2 in cancer cells. On the other hand, COX-2 was also expressed in the stroma (Figure 2a), but at a lower degree with a median value of 2 (min:1-

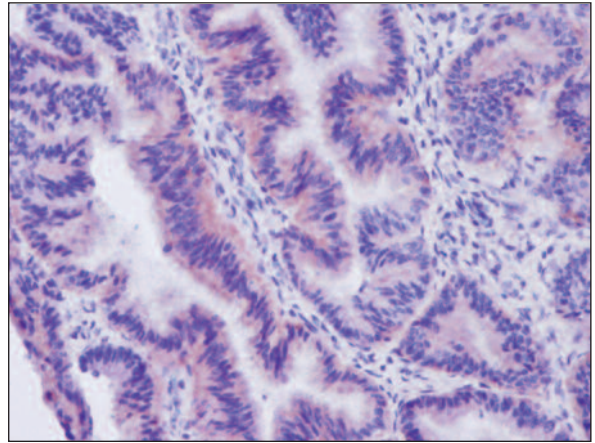
**TABLE 1:** The median (min-max) values of VEGF and COX-2 expressions in cancer cells and the tumor stroma.

Molecular markers	VEGF	COX-2
Cancer Cells	3 (1-3)	4 (3-4)
Tumor Stroma	2 (1-3)	2 (1-3)

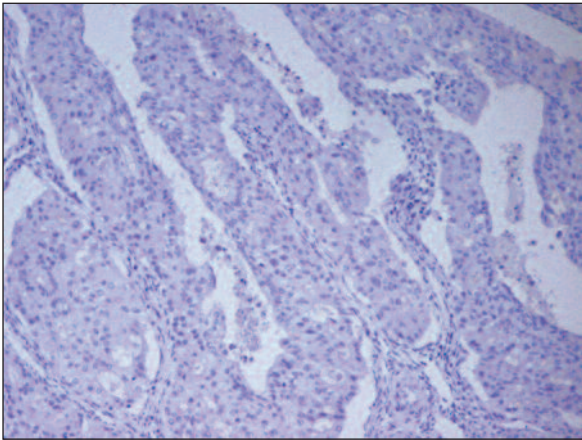
COX-2, Cyclooxygenase-2; VEGF, Vascular endothelial growth factor.



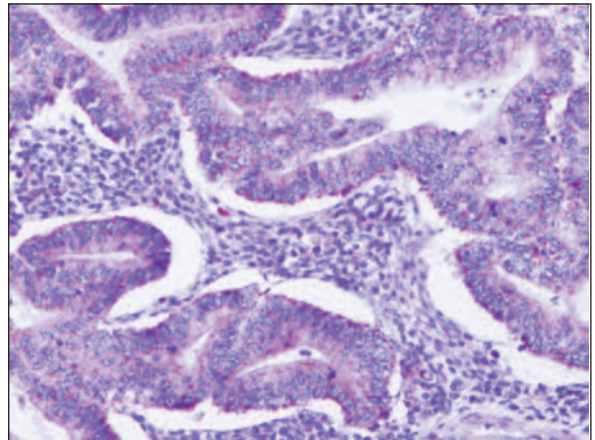
**FIGURE 1a:** Mild immunostaining with vascular endothelial growth factor (staining grade 2) in the stromal cells of endometrial carcinoma (x200).  
(See for colored form <http://tipbilimleri.turkiyeklinikleri.com/>)



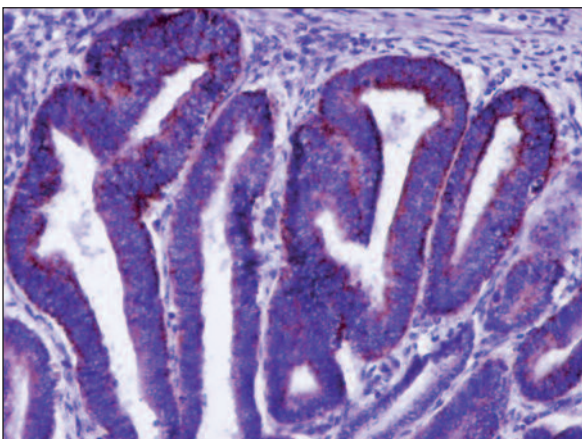
**FIGURE 1b:** Strong immunostaining with vascular endothelial growth factor (staining grade 4) in cancer cells of endometrial carcinoma with histologic grade 1 (well-differentiated type) (x200).  
(See for colored form <http://tipbilimleri.turkiyeklinikleri.com/>)



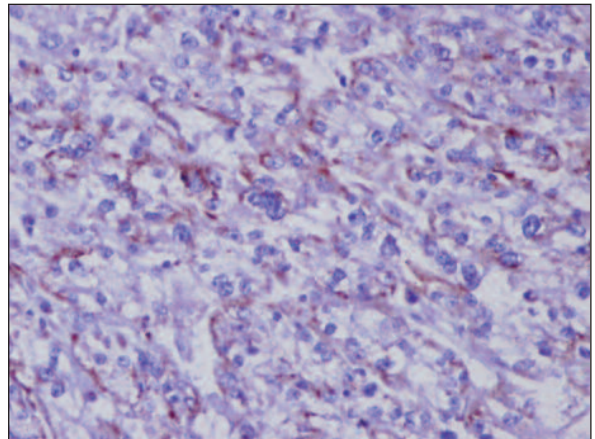
**FIGURE 1c:** No immunostaining with vascular endothelial growth factor (staining grade 1) in cancer cells of endometrial carcinoma with histologic grade 3 (poorly-differentiated type) (x100).  
(See for colored form <http://tipbilimleri.turkiyeklinikleri.com/>)



**FIGURE 2a:** Mild immunostaining with cyclooxygenase-2 (staining grade 2) in the stromal cells of endometrial carcinoma (x200).  
(See for colored form <http://tipbilimleri.turkiyeklinikleri.com/>)



**FIGURE 2b:** Strong immunostaining with cyclooxygenase-2 (staining grade 4) in cancer cells of endometrial carcinoma with histologic grade 1 (well-differentiated type) (x200).  
(See for colored form <http://tipbilimleri.turkiyeklinikleri.com/>)



**FIGURE 2c:** Strong immunostaining with cyclooxygenase-2 (staining grade 3) in cancer cells of endometrial carcinoma with histologic grade 3 (x200).  
(See for colored form <http://tipbilimleri.turkiyeklinikleri.com/>)

max: 3) (Table 1). Contrasting with VEGF expression, we did not determine any correlation of COX-2 expression between cancer cells and the stroma. COX-2 was also expressed in plasma cells. Lower immunostaining of COX-2 was noticed in higher histological grades only in several cases, and overall no correlation was found between the histological grade of EC and COX-2 expression of cancer cells, in contrast with that of VEGF expression. Patients with strong immunostaining for COX-2 also had high histological grades (Figure 2b,c). Furthermore, there was a negative correlation between myometrial invasion of the tumor and COX-2 expression of cancer cells ( $r = -0.441$ ,  $p = 0.035$ ). No other correlation was seen between COX-2 levels and age.

## DISCUSSION

The transition from the latent phase to the invasive and metastatic phase of a cancer is linked to what is called the angiogenic switch. It implies complex cellular and molecular interactions between cancerous cells, endothelial cells and the components of the extra-cellular matrix and namely the existence of specific proteins secreted by the tumoral cells able to stimulate the proliferation of capillary endothelial cells. Among them, VEGF, which was found in different types of tumors has shown a tumoral angiogenic activity *in vitro* and *in vivo*, and thus is a privileged target for the control of angiogenesis in an anti-tumoral goal.<sup>5,21,22</sup>

VEGF is an important endothelial cell mitogen and is associated with aggressive tumor behavior beyond increased angiogenesis. Besides, the angiogenic factor VEGF is suggested to be an important indicator of a poor prognosis in patients with EC.<sup>23</sup> There are several different reports about the relationship between angiogenesis and VEGF, i.e., some reports suggest that co-expression of VEGF and thymidine phosphorylase and/or platelet-derived endothelial cell growth factor expression in EC is necessary to promote angiogenesis.<sup>24,25</sup> Actually, inhibiting angiogenesis is a promising strategy to treat cancer and several other disorders, including intraocular neovascular syndromes.<sup>26</sup>

VEGF inhibitors have been recently approved by the U.S. Food and Drug Administration for the

treatment of cancer.<sup>27</sup> A recent study on esophageal neoplasms suggested that VEGF might be a useful prognostic factor in adjuvant therapy and angiogenesis inhibitory treatment via VEGF was also recommended.<sup>28</sup>

On the other hand, COX-2 is also recognized as an angiogenic factor, which has been shown to increased in various types of human cancers, suggesting that overexpression of COX-2 correlates with carcinogenesis.<sup>29-31</sup> COX-2 was found to be constantly involved in the carcinogenesis and metastatic process of some cancer types, i.e. colorectal cancer.<sup>32</sup>

These data prompted us to study the clinicopathologic implications of VEGF and COX-2 by immunohistochemical analysis of their expressions in resected uterine ECs. We measured their levels both in cancer cells and in the tumor stroma. There is growing evidence that the tumor stroma plays a crucial role in tumorigenesis, and relationship between stromal and cancer cells, as a part of the angiogenic process, remains to be clarified. Actually, in tumor development, the angiogenic switch is associated with the onset of expression and secretion of angiogenic factors by cancer cells, following secretion of growth factors by the stroma.<sup>33</sup> This was our starting point to evaluate VEGF and COX-2 expressions both in cancer cells and the tumor stroma, and determine their possible correlations.

First, we found a positive correlation between tumoral and stromal VEGF expressions. Thus, we think that the cancer cell secretion of VEGF most probably leads to a complex interplay with subsequent stromal secretion of VEGF and activation of endothelial cell receptors, as previously reported.<sup>34</sup> Therefore, VEGF may be an important cytokine in the interaction between a diversity of stromal and cancer cells. Many questions regarding the crosstalk between stromal and cancer cells, as a part of the angiogenic process, remains to be answered and needs further investigations.<sup>35</sup> On the other hand, we did not determine any correlation between cancer cell and stromal COX-2 expressions. Interestingly, in all cases, expression levels for COX-2 in cancer cells were grade 3 or 4, namely strong immunostaining was seen for COX-2. That could have affected the statistical correlation results.

Furthermore, patients with lower histological grades showed highly strong immunostaining for VEGF. Consistently, a recent study by Mărgăritescu et al. had similar findings with VEGF expression being reduced in poorly differentiated oral squamous cell carcinoma compared to moderate and well differentiated forms.<sup>36</sup> Moreover, VEGF expression at the invading tumor front was 4-10 times higher than in the deep tumor areas and was significantly associated with poor prognosis, particularly within stage I endometrial disease.<sup>37</sup> Another study by Toyoki et al. showed that VEGF and COX-2 expressions decreased with tumor de-differentiation.<sup>38</sup> In accordance with the results of that study, we found that VEGF expression showed a significant decline as the histological grade of the tumor increased, namely it de-differentiated. On the other hand, contrasting with that study we did not find any correlation between histological grade and COX-2. We conclude that the down-regulated VEGF staining might reflect more appropriately angiogenic potential with advancement.

No correlation was seen between VEGF levels and myometrial invasion and age in our study. In contrast to our study results, Topolovec et al. showed a significant association between VEGF expression and deep myometrial invasion.<sup>39</sup> Although it is hard to explain these conflicting results, they may be due to wide variations in the timing of the study related to the tumor stage or tumor type as well as different methodologies, and use of different antibodies and immunohistochemical methods. Nevertheless, we conclude that VEGF may contribute to the early process of advancement via angiogenic activity regardless of myometrial invasion.

Finally, no correlation was seen between COX-2 levels and age in our study. Similar to our findings, Li et al. found no correlation between COX-2 and age.<sup>40</sup> On the other hand, we found a negative correlation between myometrial invasion of the tumor and COX-2 expression of cancer cells, which means that ECs in lower stage of myometrial invasion show stronger COX-2 positivity compared to higher stages. Contrasting to our finding, Fujiwaki et al. reported that semi-quantitative COX-2 mRNA

levels did not correlate with any clinicopathologic factor in EC, even with early status.<sup>41</sup> Li et al. and Ferrandina et al. also found no correlation of COX-2 expression with myometrial invasion in EC.<sup>40,42</sup> Actually, COX-2 expression is increased in various tumor types such as gastric cancer<sup>43</sup> and carcinoma of the urinary bladder<sup>44</sup> and its overexpression is even associated with increased activity of the COX-2 gene suggesting its involvement in tumor pathogenesis. In this context, our study findings suggest that overexpression of COX-2 may be more intimately involved in the initial development of EC and may play a significant role in tumor onset rather than tumor invasion or progression.

## CONCLUSION

In conclusion, the significant correlation between high tumoral VEGF expression and early grades confirms previous studies. VEGF might help angiogenesis in EC at an early stage in growth, before myometrial invasion or metastasis. To strengthen our findings, future prospective studies should explore the relation between VEGF, microvessel density, and survival or response to therapy (e.g. antiangiogenic therapy). On the other hand, negative correlation between tumoral COX-2 expression and myometrial invasion suggests COX-2 may be involved in the initial development of EC and may play a role in tumor onset. Moreover, future EC trials should consider lower-dose nonsteroidal anti-inflammatory drugs in combination with VEGF inhibitors. We emphasize here that tumor growth and metastasis are not determined by cancer cells alone but also by a variety of stromal cells. Because cancer cell targets are often elusive due to mutations, most cells in the tumor stroma are genetically more stable and may accordingly be of greater interest for targeted therapies.

## Acknowledgements

*This study was funded for kits and consumables by the Afyonkocatepe University, Scientific Research Projects Foundation (Project number 10.tip.10). We would like to thank to Assoc Prof. Dr. Reha Demirel for his assistance for statistical analysis and to Assoc. Prof. Dr. Hüseyin Göksu for his assistance for language editing.*

## REFERENCES

- Jemal A, Siegel R, Ward E, Murray T, Xu J, Thun MJ. Cancer statistics, 2007. *CA Cancer J Clin* 2007;57(1):43-66.
- Folkman J. What is the evidence that tumors are angiogenesis dependent? *J Natl Cancer Inst* 1990;82(1):4-6.
- Bergers G, Benjamin LE. Tumorigenesis and the angiogenic switch. *Nat Rev Cancer* 2003;3(6):401-10.
- Hanahan D, Folkman J. Patterns and emerging mechanisms of the angiogenic switch during tumorigenesis. *Cell* 1996;86(3):353-64.
- Ferrara N, Gerber HP, LeCouter J. The biology of VEGF and its receptors. *Nat Med* 2003;9(6):669-76.
- Claffey KP, Robinson GS. Regulation of VEGF/VPF expression in tumor cells: consequences for tumor growth and metastasis. *Cancer Metastasis Rev* 1996;15(2):165-76.
- Toi M, Hoshina S, Takayanagi T, Tominaga T. Association of vascular endothelial growth factor expression with tumor angiogenesis and with early relapse in primary breast cancer. *Jpn J Cancer Res* 1994;85(10):1045-9.
- Plate KH, Breier G, Weich HA, Risau W. Vascular endothelial growth factor is a potential tumour angiogenesis factor in human gliomas in vivo. *Nature* 1992;359(6398):845-8.
- Brown LF, Berse B, Jackman RW, Tognazzi K, Manseau EJ, Senger DR, et al. Expression of vascular permeability factor (vascular endothelial growth factor) and its receptors in adenocarcinomas of the gastrointestinal tract. *Cancer Res* 1993;53(19):4727-35.
- Brown LF, Berse B, Jackman RW, Tognazzi K, Manseau EJ, Dvorak HF, et al. Increased expression of vascular permeability factor (vascular endothelial growth factor) and its receptors in kidney and bladder carcinomas. *Am J Pathol* 1993;143(5):1255-62.
- Olson TA, Mohanraj D, Carson LF, Ramakrishnan S. Vascular permeability factor gene expression in normal and neoplastic human ovaries. *Cancer Res* 1994;54(1):276-80.
- Tsuji M, Kawano S, Tsuji S, Sawaoka H, Hori M, DuBois RN. Cyclooxygenase regulates angiogenesis induced by colon cancer cells. *Cell* 1998;93(5):705-16.
- Ali-Fehmi R, Che M, Khalifeh I, Malone JM, Morris R, Lawrence WD, et al. The effect of cyclooxygenase-2 expression on tumor vascularity in advanced stage ovarian serous carcinoma. *Cancer* 2003;98(7):1423-9.
- Davies G, Salter J, Hills M, Martin LA, Sacks N, Dowsett M. Correlation between cyclooxygenase-2 expression and angiogenesis in human breast cancer. *Clin Cancer Res* 2003;9(7):2651-6.
- Miyata Y, Koga S, Kanda S, Nishikido M, Hayashi T, Kanetake H. Expression of cyclooxygenase-2 in renal cell carcinoma: correlation with tumor cell proliferation, apoptosis, angiogenesis, expression of matrix metalloproteinase-2, and survival. *Clin Cancer Res* 2003;9(5):1741-9.
- Joo YE, Rew JS, Seo YH, Choi SK, Kim YJ, Park CS, et al. Cyclooxygenase-2 overexpression correlates with vascular endothelial growth factor expression and tumor angiogenesis in gastric cancer. *J Clin Gastroenterol* 2003;37(1):28-33.
- Creasman WT. Announcement. FIGO stages: 1988 revision. *Gynecol Oncol* 1989;35(1):125-7.
- Creasman W. Revised FIGO staging for carcinoma of the endometrium. *Int J Gynaecol Obstet* 2009;105(2):109.
- Sun WH, Sun YL, Fang RN, Shao Y, Xu HC, Xue QP, et al. Expression of cyclooxygenase-2 and matrix metalloproteinase-9 in gastric carcinoma and its correlation with angiogenesis. *Jpn J Clin Oncol* 2005;35(12):707-13.
- Tokyo C, Aktepe F, Dilek FH, Sahin O, Ariz DT. Expression of cyclooxygenase-2 and matrix metalloproteinase-2 in adenomyosis and endometrial polyps and its correlation with angiogenesis. *Int J Gynecol Pathol* 2009;28(2):148-56.
- Risau W. Mechanisms of angiogenesis. *Nature* 1997;386(6626):671-4.
- Shinkaruk S, Bayle M, Lain G, Déléris G. Vascular endothelial cell growth factor (VEGF), an emerging target for cancer chemotherapy. *Curr Med Chem Anticancer Agents* 2003;3(2):95-117.
- Giatromanolaki A, Sivridis E, Brekken R, Thorpe PE, Anastasiadis P, Gatter KC, et al. The angiogenic "vascular endothelial growth factor/flk-1(KDR) receptor" pathway in patients with endometrial carcinoma: prognostic and therapeutic implications. *Cancer* 2001;92(10):2569-77.
- Seki N, Kodama J, Hongo A, Miyagi Y, Yoshinouchi M, Kudo T. Vascular endothelial growth factor and platelet-derived endothelial cell growth factor expression are implicated in the angiogenesis of endometrial cancer. *Eur J Cancer* 2000;36(1):68-73.
- Fujiwaki R, Hata K, Iida K, Maeda Y, Watanabe Y, Koike M, et al. Co-expression of vascular endothelial growth factor and thymidine phosphorylase in endometrial cancer. *Acta Obstet Gynecol Scand* 1999;78(8):728-34.
- Keklikci U, Çiftci S, Ünlü K. [The association of vascular endothelial growth factor and neovascular glaucoma and the role of anti-vascular endothelial growth factor in treatment: review]. *Turkiye Klinikleri J Ophthalmol* 2008;17(2):124-31.
- Niu G, Chen X. Vascular endothelial growth factor as an anti-angiogenic target for cancer therapy. *Curr Drug Targets* 2010;11(8):1000-17.
- Şahin E, Ökten I. [Effects of the angiogenetic factors on esophageal neoplasms prognosis]. *Turkiye Klinikleri J Surg Med Sci* 2007;3(29):24-8.
- Wolff H, Saukkonen K, Anttila S, Karjalainen A, Vainio H, Ristimäki A. Expression of cyclooxygenase-2 in human lung carcinoma. *Cancer Res* 1998;58(22):4997-5001.
- Hwang D, Scollard D, Byrne J, Levine E. Expression of cyclooxygenase-1 and Cyclooxygenase-2 in human breast cancer. *J Natl Cancer Inst* 1998;90(6):455-60.
- Zimmermann KC, Sarbia M, Weber AA, Borchard F, Gabbert HE, Schrör K. Cyclooxygenase-2 expression in human esophageal carcinoma. *Cancer Res* 1999;59(1):198-204.
- Kasper HU, Konze E, Dienes HP, Stippel DL, Schirmacher P, Kern M. COX-2 expression and effects of COX-2 inhibition in colorectal carcinomas and their liver metastases. *Anticancer Res* 2010;30(6):2017-23.
- Kitada Y. Cancer-stromal cell interaction and tumor angiogenesis in gastric cancer. *Cancer Microenviron* 2010;3(1):109-16.
- Bremnes RM, Camps C, Sirera R. Angiogenesis in non-small cell lung cancer: the prognostic impact of neoangiogenesis and the cytokines VEGF and bFGF in tumours and blood. *Lung Cancer* 2006;51(2):143-58.
- Liotta LA, Kohn EC. The microenvironment of the tumour-host interface. *Nature* 2001;411(6835):375-9.
- Mărgăritescu C, Pirici D, Stîngă A, Simionescu C, Raica M, Mogoantă L, et al. VEGF expression and angiogenesis in oral squamous cell carcinoma: an immunohistochemical and morphometric study. *Clin Exp Med* 2001;10(4):209-14.
- Sivridis E. Angiogenesis and endometrial cancer. *Anticancer Res* 2001;21(6B):4383-8.
- Toyoki H, Fujimoto J, Sato E, Sakaguchi H, Tamaya T. Clinical implications of expression of cyclooxygenase-2 related to angiogenesis in uterine endometrial cancers. *Ann Oncol* 2005;16(1):51-5.
- Topolovec Z, Corusić A, Babić D, Mrcela M, Sijanović S, Müller-Vranjes A, et al. Vascular endothelial growth factor and intratumoral microvessel density as prognostic factors in endometrial cancer. *Coll Antropol* 2010;34(2):447-53.

40. Li W, Xu RJ, Jiang LH, Shi J, Long X, Fan B. Expression of cyclooxygenase-2 and inducible nitric oxide synthase correlates with tumor angiogenesis in endometrial carcinoma. *Med Oncol* 2005;22(1):63-70.
41. Fujiwaki R, Iida K, Kanasaki H, Ozaki T, Hata K, Miyazaki K. Cyclooxygenase-2 expression in endometrial cancer: correlation with microvessel count and expression of vascular endothelial growth factor and thymidine phosphorylase. *Hum Pathol* 2002;33(2):213-9.
42. Ferrandina G, Legge F, Ranelletti FO, Zannoni GF, Maggiano N, Evangelisti A, et al. Cyclooxygenase-2 expression in endometrial carcinoma: correlation with clinicopathologic parameters and clinical outcome. *Cancer* 2002;95(4):801-7.
43. Uefuji K, Ichikura T, Mochizuki H. Cyclooxygenase-2 expression is related to prostaglandin biosynthesis and angiogenesis in human gastric cancer. *Clin Cancer Res* 2000;6(1):135-8.
44. Ristimäki A, Nieminen O, Saukkonen K, Hottakainen K, Nordling S, Haglund C. Expression of cyclooxygenase-2 in human transitional cell carcinoma of the urinary bladder. *Am J Pathol* 2001;158(3):849-53.