

Clinical Evaluation of Papillitis and Macular Edema After Blepharoplasty: Case Report

Blefaroplasti Sonrası Gelişen Papillit ve Maküler Ödemın Klinik Değerlendirilmesi

Burcu ÇALIK, MD,^a
Muzaffer ÖZTÜRK, MD,^a
Feyza ALTIN, MD,^a
Necdet CİNHÜSEYİNOĞLU, MD,^a
Mustafa ELÇİOĞLU, MD^a

^aDepartment of Ophthalmology,
Okmeydanı Training and
Research Hospital, İstanbul

Geliş Tarihi/Received: 17.05.2010
Kabul Tarihi/Accepted: 11.04.2011

*This article was presented as a poster at
42nd National Ophthalmology Congress
(2008, Antalya, Turkey)*

Yazışma Adresi/Correspondence:
Burcu ÇALIK, MD
Okmeydanı Training and
Research Hospital,
Department of Ophthalmology, İstanbul,
TÜRKİYE/ TURKEY
dr_burcuoz@yahoo.com

ABSTRACT Complications involving eyelids can be seen after blepharoplasty but vision loss after blepharoplasty is rarely reported. In this study we report clinical evaluation of a patient who developed papillitis and macular edema after upper eyelid blepharoplasty. It was noted that best corrected visual acuity decreased from 20/20 to 10/20 in both eyes at the second week after surgery. Fundus examination revealed macular edema. In fundus fluorescein angiography (FFA) papillitis and cystoid macular edema (CME) was seen and in optical coherence tomography (OCT) cystoid spaces with subretinal fluid were observed. The patient was observed without treatment. After 5 weeks, patients uncorrected visual acuity improved to 18/20 in both eyes. Optic disc edema and CME resolved in repeated FFA. Central foveal thickness markedly decreased in OCT. Papillitis and macular edema seen after blepharoplasty can resolve without treatment.

Key Words: Blepharoplasty; macular edema

ÖZET Blefaroplasti sonrasında göz kapağı ile ilgili komplikasyonlar görülebilmekte, fakat görme kaybı nadir olarak tarif edilmektedir. Bu yazıda, kliniğimizde üst kapak blefaroplastisi sonrasında papillit ve kistoid makula ödemi gelişen bir hastanın klinik değerlendirilmesi sunulmaktadır. Cerrahiden 2 hafta sonra hastanın görme keskinliğinin her iki gözde 20/20'den 10/20'ye gerilediği gözlemlendi. Fundus muayenesinde maküler ödem tespit edilen hastanın fundus floresan anjiyografisi (FFA)'nde papillit ve kistoid maküler ödem izlendi ve optik koherens tomografi (OCT)'de subretinal sıvı ile birlikte kistoid boşluklar mevcut idi. Hasta tedavi verilmeden izlendi. Beş hafta sonra düzeltilmemiş görme keskinliği her iki gözde 18/20'ye ilerledi. Tekrarlanan FFA'da optik disk ödemi ve maküler ödem geriledi. OCT'de artmış santral foveal kalınlık belirgin olarak azaldı. Blefaroplasti sonrası gelişebilen papillit ve maküler ödem tedavisiz de gerileyebilmektedir.

Anahtar Kelimeler: Blefaroplasti; makula ödemi

Türkiye Klinikleri J Ophthalmol 2011;20(3):150-3

Blepharoplasty is a functional and cosmetic surgical procedure intended to reshape the upper eyelid or the lower eyelid. It includes the removal of skin, muscle and fat in varying proportions from the eyelids. The most common complications of blepharoplasty are dry eye, infection, ptosis, lagophthalmos, extraocular muscle dysfunction and ectropion. Vision loss after blepharoplasty is reported to be a rare but serious complication related to orbital hematoma formation during the operation.¹ In this article, we will report a patient who presented with vision loss after cosmetic blepharoplasty surgery in our clinic. We evaluated the cause of vision loss as cystoid macular edema (CME). Possible causes of this rare case report will be discussed.

CASE REPORT

A 42-year-old woman underwent bilateral upper lid blepharoplasty with fat removal under local anesthesia without complication. Patient had informed consent before surgery. In her past ocular history she had bilateral laser in situ keratomileusis (LASIK) surgery for the correction of 4.00 hypermetropia and +1.00 astigmatism one year before blepharoplasty. Her uncorrected visual acuity after the LASIK was 20/20 in the right eye and 20/20 in the left eye. No complication related to LASIK was reported. Two weeks after blepharoplasty she presented with sudden vision loss. She didn't have any systemic or metabolic diseases. Examination of the patient revealed no proptosis, eyelid edema or other signs of orbital hematoma. Best corrected visual acuity of the patient was 10/20 in the right eye and 10/20 in the left eye. Color vision especially for red color and contrast sensitivity were impaired. In her pupillary examination afferent pupillary defect was not detected. Anterior segment examination showed the pre-

existing sectorial iris atrophy. In fundus examination, macular edema was seen. In fundus fluorescein angiography (FFA) shown in Figure 1, CME and subclinical papillitis was observed in both eyes. Macular edema seen in the FFA was not consistent with central serous chorioretinopathy. In the macular Optical coherence tomography (OCT) of the patient, intraretinal cystoid spaces and subretinal fluid was observed (Figure 2). Central foveal thickness was 649 microns in the right eye and 651 microns in the left eye. General reduction of sensitivity was seen in her visual field. Firstly, we wanted to rule out multiple sclerosis since FFA showed hyperfluorescence of the optic disc. Neurology consultation was made. Cranial MRI of the patient showed no demyelinating plaques. Evaluation of CME was made.

The patient received no treatment. We decided to observe and give medication in case of more vision loss. After 5 weeks, patients' uncorrected visual acuity improved to 18/20 in both eyes. Repeated FFA showed resolved optic disc edema and CME as seen in Figure 3. Central foveal thickness

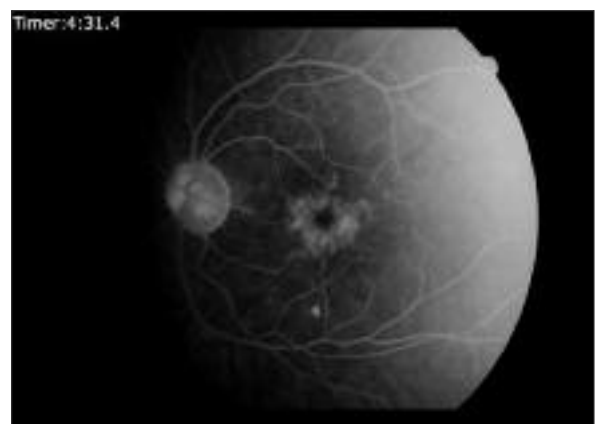
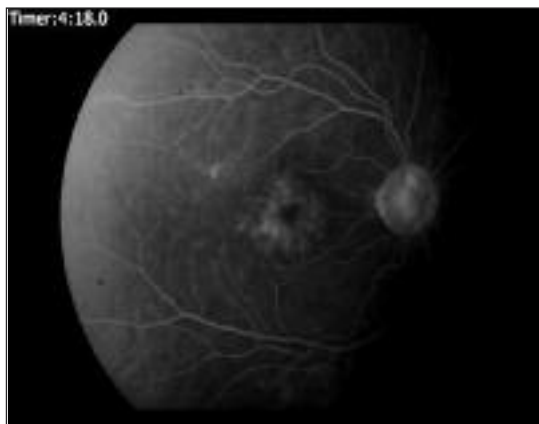
FIGURE 1: FFA images 2 weeks after blepharoplasty. Subclinical papillitis (hyperfluorescence of optic disc) and cystoid macular edema can be seen in right and left eye.

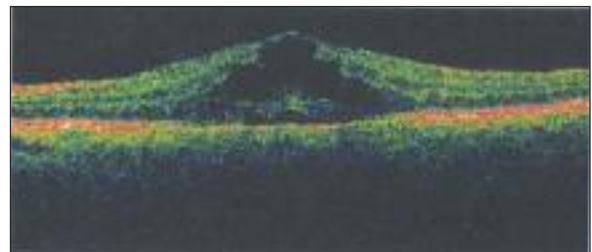
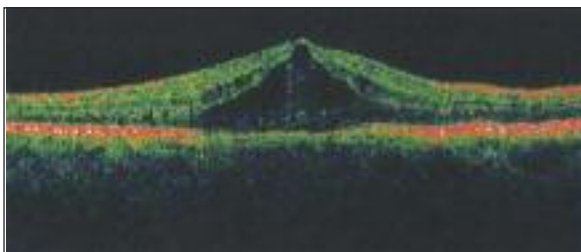


FIGURE 2: OCT images 2 weeks after blepharoplasty. Intraretinal cystoid spaces and subretinal fluid can be observed in both eyes.

in control OCT was 354 in right and 354 in left eye. Macular OCT at the 5th week is shown in Figure 4.

DISCUSSION

One of the most commonly seen complications of blepharoplasty is dry eye syndrome. The increased frequency of dry eye syndrome in six patients who have undergone both LASIK and blepharoplasty was described.² They developed significant exposure keratopathy postoperatively requiring surgical intervention. In our case, the patient had both LASIK and blepharoplasty too; but dry eye symptoms and signs were not seen.

Vision loss after cosmetic blepharoplasty is rare but since it's important, it's well documented in the literature. There are many causes of vision loss following blepharoplasty; increased intraorbital pressure because of intraorbital hemorrhage is the most serious complication seen.¹ Hepler et al reported that sudden or complete loss of vision following blepharoplasty was caused by;

1. Orbital hemorrhage causing increased orbital pressure which compromised the vascular circulation in the eye,

2. Acute angle-closure glaucoma in susceptible individuals or,

3. Optic nerve ischemia, possibly due to orbital manipulation and/or pressure or secondary systemic hypotension from preoperative medications.³ Most of the reported cases include fat removal and deep orbital hemorrhage at the time of surgery.⁴

Hass et al reported the incidence of postblepharoplasty orbital hemorrhage associated with vision loss by the help of a questionnaire.⁵ The incidence of orbital hemorrhage associated with cosmetic eyelid surgery is 0.055% (1:2.000), and orbital hemorrhage with permanent visual loss is 0.0045% (1:22.000). Development of orbital hemorrhage is most common within the first 24 hours after surgery, especially within the first 0 to 3 hours.

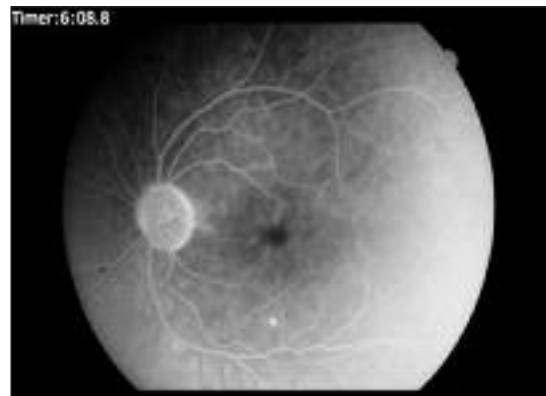
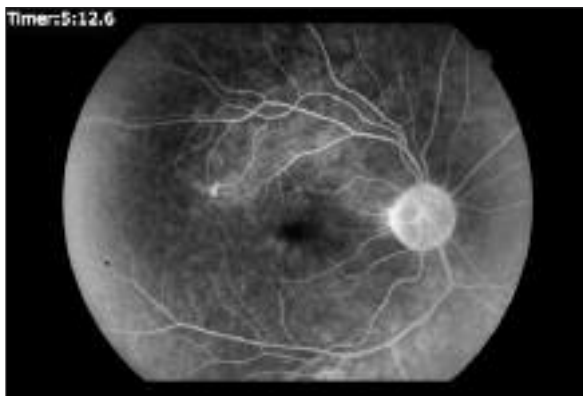
FIGURE 3: FFA images 5 weeks after blepharoplasty. Optic disc edema and cystoid macular edema has been resolved but some hyperfluorescence of optic disc persists.

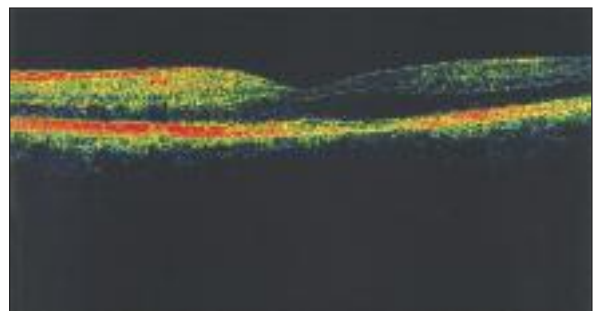
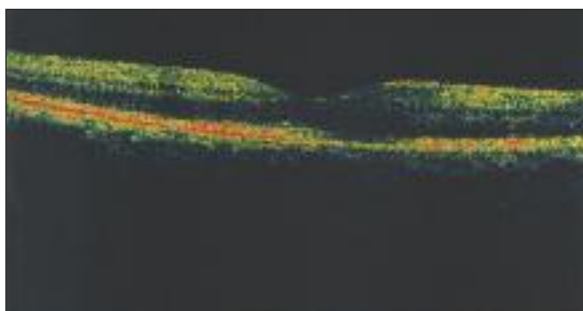


FIGURE 4: OCT images 5 weeks after blepharoplasty. Cystoid macular edema has been resolved.

In our case during the surgery orbital hemorrhage wasn't seen. There were also no signs of delayed hemorrhage. So we ruled out orbital hemorrhage as the cause of vision loss.

Another cause of vision loss after blepharoplasty can be ischemia. Ischemia unrelated to intra-orbital bleeding is caused by the spasm within the concerned vessels. Theoretically it could be caused by pulling on the fat pedicles or by the use of vasopressor agents such as adrenaline in the local anesthetic infiltrates, or by the action of vasoactive agents released from extravasated blood.⁶

A case of perioperative posterior ischemic optic neuropathy was reported with vision loss 3 days after the operation without orbital hemorrhage. The mechanism leading to optic nerve damage in this patient may include compromised small arteries perfusing the optic disk due to direct mechanical compression and a probable vasoconstrictive activity of the anesthetic agent.⁷

In our case, vision loss was seen 2 weeks after the blepharoplasty. Since there was no complication during the surgery, we thought optic neuritis could be related with multiple sclerosis (MS), since it is the common cause. But in the cranial MRI of the patient no demyelinating plaques was seen. Papillitis can follow a prodromal viral disease. Our patient didn't report any prior viral disease. In multiple sclerosis patients, CME doesn't accompany papillitis.

Differential diagnosis of CME was made since it was the major cause of vision loss. CME is the response of the retina to a variety of possible insults. It has been reported in association with vas-

cular problems (such as diabetes and retinal vein obstruction), inflammatory conditions (such as pars planitis), inherited diseases (such as retinitis pigmentosa or dominant CME), tractional problems (such as vitreomacular traction syndrome), and use of medications such as epinephrine (adrenaline) or latanoprost, but its most common setting is following cataract surgery⁸ Although it is common after intraocular surgery procedures, it is not reported after blepharoplasty.

Medications such as epinephrine, nicotinic acid, and latanoprost can cause CME. Topical epinephrine may produce cystoid changes by reducing blood flow in the retina and choroid.⁹ We think that epinephrine found in jetocaine used for local anesthesia can be responsible for the macular edema in our case since there were no inflammatory, vascular, tractional or inherited possible cause for spontaneously resolved edema.

CME can be treated with anti-inflammatory medications. We preferred to wait and start treatment in case of more vision loss. Cystoid macular edema and papillitis resolved spontaneously.

Vision loss after cosmetic blepharoplasty is a rare and serious complication and should be evaluated immediately. Orbital hemorrhage should be ruled out first since it can cause irreversible vision loss if it is not noticed in time. In case of CME like in our case, differential diagnosis of CME, vascular, inflammatory conditions are evaluated. Optic disc edema can be seen with CME. Also local anesthesia containing epinephrine can be responsible for CME. Macular edema caused by epinephrine can resolve without treatment.

REFERENCES

- Morax S, Touitou V. Complications of blepharoplasty. *Orbit* 2006;25(4):303-18.
- Korn BS, Kikkawa DO, Schanzlin DJ. Blepharoplasty in the post-laser in situ keratomileusis patient: preoperative considerations to avoid dry eye syndrome. *Plast Reconstr Surg* 2007;119(7):2232-9.
- Kelly PW, May DR. Central retinal artery occlusion following cosmetic blepharoplasty. *Br J Ophthalmol* 1980;64(12):918-22.
- Goldberg RA, Marmor MF, Shorr N, Christenbury JD. Blindness following blepharoplasty: two case reports, and a discussion of management. *Ophthalmic Surg* 1990;21(2):85-9.
- Hass AN, Penne RB, Stefanyszyn MA, Flanagan JC. Incidence of postblepharoplasty orbital hemorrhage and associated visual loss. *Ophthalm Plast Reconstr Surg* 2004;20(6):426-32.
- Mahaffey PJ, Wallace AF. Blindness following cosmetic blepharoplasty- a review. *Br J Plast Surg* 1986;39(2):213-21.
- Kordic H, Flammer J, Mironow A, Killer HE. Perioperative posterior ischemic optic neuropathy as a rare complication of blepharoplasty. *Ophthalmologica* 2005;219(3):185-8.
- Yanoff M, Duker JS. Cystoid macular edema. *Ophthalmology*. 3rd ed. St Louis: Mosby; 2008. p.696-701.
- Grant WM. Toxicology of The Eye: effects on the eyes and visual system from chemicals, drugs, metals and minerals, plants, toxins and venoms also, systemic side effects from eye medications. 3rd ed. Springfield, IL: Thomas; 1986. xiii, p. 1083.