

# Focal Dermal Hypoplasia (Goltz Syndrome): Case Report

## Fokal Dermal Hipoplazi (Goltz Sendromu)

Arzu KILIÇ, MD,<sup>a</sup>  
Seçil SOYLU, MD,<sup>a</sup>  
Erkan ARSLAN, MD,<sup>a</sup>  
Ülker GÜL, MD,<sup>a</sup>  
Murat DEMİRİZ, MD<sup>b</sup>

<sup>a</sup>2<sup>nd</sup> Dermatology Clinic,  
Ankara Numune Education and  
Research Hospital

<sup>b</sup>Department of Pathology,  
GATA, Ankara

Geliş Tarihi/Received: 03.09.2007  
Kabul Tarihi/Accepted: 31.10.2007

Yazışma Adresi/Correspondence:  
Arzu KILIÇ, MD  
Ankara Numune Education and  
Research Hospital,  
2<sup>nd</sup> Dermatology Clinic, Ankara,  
TÜRKİYE/TURKEY  
kilicarzu2004@yahoo.com

**ABSTRACT** Focal dermal hypoplasia (Goltz syndrome) is a rare genetic disorder characterized by cutaneous lesions including telangiectasias, hypopigmentation, hyperpigmentation, and/or dermal atrophy following Blaschko's lines. In addition to cutaneous findings, dental, skeletal, eye and other organ abnormalities may occur. A 21-year-old woman applied to our clinic with atrophic and hyperpigmented linear streaks following Blaschko's lines, yellow-soft nodules and aplasia cutis congenita that had been present since birth. Detailed examination of the patient revealed dental, skeletal and ocular abnormalities. Based upon clinical and histopathological findings, she was diagnosed as Goltz syndrome. In this report, a case of Goltz syndrome was reported because of its rare presentation and relevant literature was discussed.

**Key Words:** Focal dermal hypoplasia; ectodermal dysplasia

**ÖZET** Fokal dermal hipoplazi (Goltz sendromu), Blaschko çizgilerini izleyen telanjiektazi, hipopigmentasyon, hiperpigmentasyon ve/veya dermal atrofiyi içeren kutanöz bulgularla karakterize nadir görülen genetik bir hastalıktır. Kutanöz bulgulara ek olarak, dental, iskelet, göz ve diğer organ anomalileri de eşlik edebilir. Yirmi bir yaşında kadın hasta, doğumdan beri olan, Blaschko çizgilerini izleyen atrofik, hiperpigmente çizgiler şeklinde lezyonlar, sarı-yumuşak nodüller ve aplazia kutis konjenita ile kliniğimize başvurdu. Detaylı incelemede hastada dental, iskelet ve göz anomalileri saptandı. Klinik ve histopatolojik bulgulara dayanarak olguya Goltz sendromu tanısı konuldu. Bu yazıda nadir görülmesi nedeniyle Goltz sendromlu bir olgu sunuldu ve ilişkili literatür gözden geçirildi.

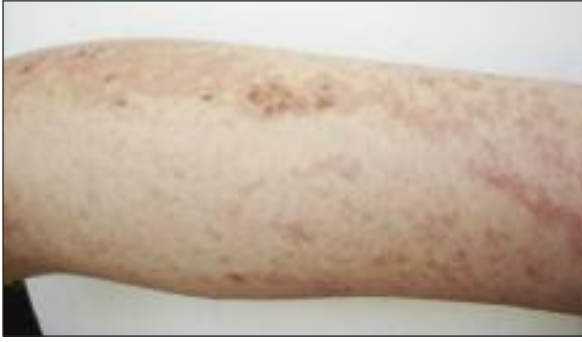**Anahtar Kelimeler:** Fokal dermal hipoplazi; ektodermal displazi

**Türkiye Klinikleri J Dermatol 2009;19(2):107-10**

Focal dermal hypoplasia (FDH) or Goltz syndrome is a rare genodermatosis, characterized by multiple abnormalities of ectodermal and mesodermal origins.<sup>1</sup> In spite of a variety of abnormalities accompanying to Goltz syndrome, until now only a few reports indicating the coexistence of Goltz syndrome together with aplasia cutis congenita have been reported.<sup>2</sup> In this report, we present a case of Goltz syndrome with accompanied by aplasia congenita cutis, skin, dental and skeletal findings.

### CASE REPORT

A 21-year old woman applied to our clinic with the complaint of erythematous and atrophic skin lesions that had been present since birth. On dermatological examination, widespread, multiple, pigmented, depigmented,



**FIGURE 1:** The appearance of hyperpigmented, erythematous, atrophic lesions in a linear configuration localized on upper extremity.

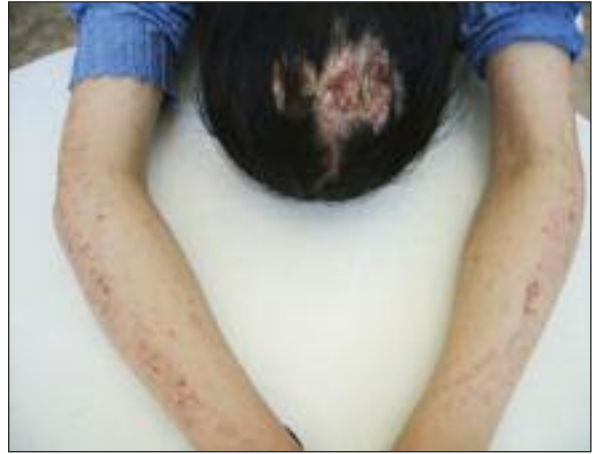

**FIGURE 2:** The yellowish nodule (fat herniation) on arm is seen.

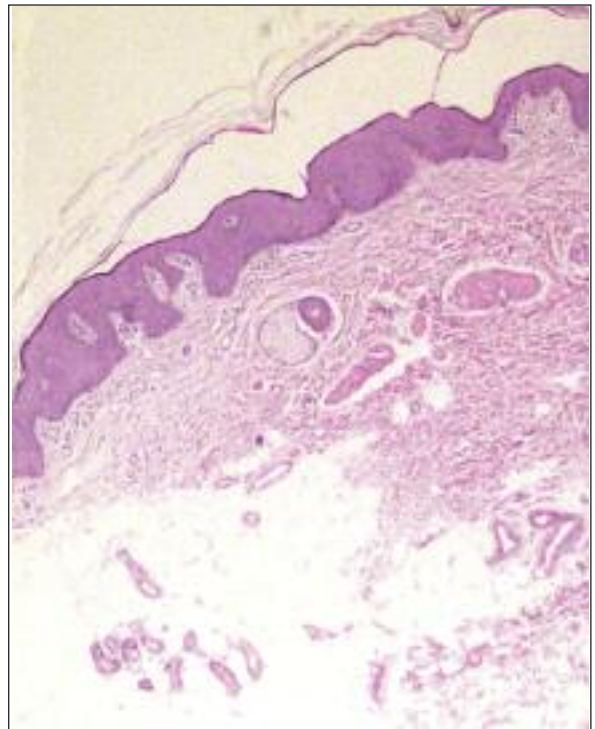
erythematous and atrophic patches in a linear and swirl configuration following Blaschko's lines were detected (Figure 1,2). Moreover, soft, yellow nodules (localized herniations of subcutaneous fat) were detected on the bilateral upper and lower extremities and on the trunk. Telangiectases were more prominent on her face. The patient had an asymmetrical face. Examination of the hands nails revealed grooving. In addition to these findings, alopecia with an atrophic base on the vertex of the scalp was detected. (Figure 3). Our patient was not a product of consanguineous marriage and none of her family members had a similar disease. The histopathological examination of the skin biopsy revealed hypoplasia of dermis, a few adnexial structures and adipose tissue in upper dermis, which were consistent with the features of Goltz syndrome (Figure 4). The biopsy taken from the scalp showed fibrosis in entirely dermis. No adnexial structures were detected. (Figure 5). These histo-

pathological features were consistent with aplasia cutis congenita.

No pathology was found in routine laboratory tests, X-ray graphy of the lung, abdominopelvic ultrasonography and cranial magnetic resonance examinations. Bone X-rays revealed decrease in lumbar lordosis, thoracal antero-spondylolisthesis



**FIGURE 3:** Aplasia cutis accompanying the linear lesions of Goltz syndrome is seen.



**FIGURE 4:** Hypoplastic dermis. Note a few adnexial structures and adipose tissue in upper dermis (HE, x50).

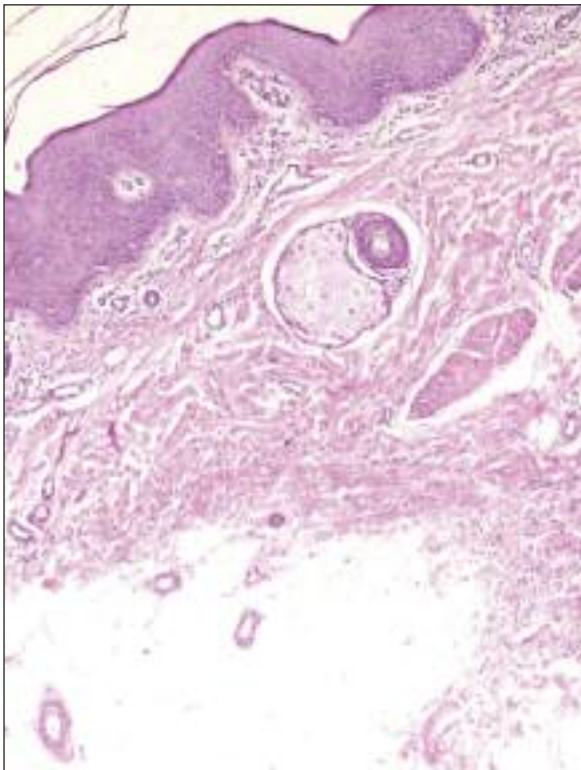


FIGURE 5: Dermal fibrosis in aplasia cutis (HE, x25).

in thoracal vertebrae 3-4 and thoracal vertebrae 4-5 levels, cysts in bilateral metacarpal bones. Radiographic examination of the teeth and the dental pantogram revealed hypodontia, microdontia, enamel defects, teeth loss and short root formation of the permanent teeth.

The patient was consulted with ophthalmologist and afferent pupil defect was detected.

In the present case classic skin lesions, skeletal and dental defects with supportive histopathological findings confirmed the diagnosis of Goltz syndrome. The patient was taken under our clinical follow-up.

## DISCUSSION

FDH or Goltz syndrome is a rare genodermatosis characterized by multiple abnormalities of ectodermal and mesodermal origin.<sup>1,2</sup> The clinical spectrum in Goltz syndrome can either has systemic involvement or can be limited to skin.<sup>2,3</sup> Abnormalities include cutaneous findings such as linear and reticular pigmentation, telangiectasies

and papillomas, as well as skeletal, dental, and ocular defects.<sup>1-4</sup>

The preponderance of female cases (approximately 90%) and the occurrence of frequent miscarriages and stillbirths suggest that condition is inherited in an X-linked dominant fashion with lethality in most affected males.<sup>1-3,5</sup> Approximately 95% of cases are sporadic.<sup>1-3</sup>

Cutaneous findings include hypoplastic and atrophic skin changes, linear and reticular areas of hypo and hyperpigmentation, lipomatous nodules, verrucous papillomas with a linear arrangement that follows the lines of Blaschko, periorificial and mucous membrane papillomas, and telangiectasies.<sup>1-4</sup> Xerosis with mild pruritus and photosensitivity are also frequently noted.<sup>3</sup> Nail changes include atrophy, dystrophy, grooving, or even absence of the nail and have been noted in more than 40% of cases. Thirty percent of the patients have alopecia, and the hair is often described as sparse and brittle.<sup>1</sup> Cicatricial alopecia and hypertrichosis have also been reported.<sup>5,6</sup> Our patient did not have cicatricial alopecia on scalp, had aplasia cutis congenita. This distinction was made clinically and histopathologically.

Ocular abnormalities are present in 40% of cases. Colobomas, microphthalmia, strabismus, nystagmus and lens subluxation can occur.<sup>1-5</sup>

In addition to cutaneous and ocular findings, nearly all cases of Goltz syndrome demonstrate skeletal defects. These include short stature, syndactyly, hypoplastic or absent digits, scoliosis and asymmetry of the face. A lobster-claw deformity is a unique feature of Goltz syndrome.<sup>1,5</sup> Vertical radiopaque stripes in the metaphyseal region on long bones, called osteopathia striata, is a major finding in the radiological examination and can be seen in 20% of gene carriers.<sup>7</sup>

Anomalies of the teeth have been reported in approximately 40% of cases and include hypodontia, microdontia, irregular spacing, malocclusion, rotated teeth, malformed teeth, hypoplastic enamel, and so forth.<sup>2,8,9</sup> Our case also had skeletal and dental abnormalities.

Mental retardation is reported in approximately one-third of cases.<sup>7</sup> Several renal or genitourinary anomalies have been found, including horseshoe kidney. Different types of hernias can occur as the result of the defective connective tissue.<sup>2</sup> Turkmen et al, reported case having both features of FDH and Adams-Oliver syndrome.<sup>10</sup> Our case had a normal level of intelligence and did not have any systemic involvement.

Our patient is a typical case of Goltz syndrome, displaying the specific cutaneous findings of the disease. In addition to cutaneous manifestations, she had also dental and skeletal defects. It is of our interest that she had been suffering from the absence of scalp skin of the vertex localization since birth. We present this case due to its rare occurrence and review the features of this rare genodermatosis.

## REFERENCES

1. Sacoor MF, Motswaledi MH. Three cases of focal dermal hypoplasia (Goltz syndrome). *Clin Exp Dermatol* 2005;30(1):35-7.
2. Landa N, Oleaga JM, Ratón JA, Gardeazabal J, Díaz-Pérez JL. Focal dermal hypoplasia (Goltz syndrome): an adult case with multi-systemic involvement. *J Am Acad Dermatol* 1993;28(1):86-9.
3. Kilmer SL, Grix AW Jr, Isseroff RR. Focal dermal hypoplasia: four cases with widely varying presentations. *J Am Acad Dermatol* 1993;28(5 Pt 2):839-43.
4. Alster TS, Wilson F. Focal dermal hypoplasia (Goltz's syndrome). Treatment of cutaneous lesions with the 585-nm flashlamp-pumped pulsed dye laser. *Arch Dermatol* 1995;131(2):143-4.
5. Miteva L. Focal dermal hypoplasia syndrome in a male. *Acta Derm Venereol* 2001;81(3):218-9.
6. Lotfi M, Firooz A, Nosrati A, Tabatabai H, Dowlati Y. Off-center fold: linear atrophy, telangiectases, and soft nodules along the lines of Blaschko with skeletal abnormalities. *Arch Dermatol* 2001;137(8):1095-100.
7. Sule RR, Dhumawat DJ, Gharpuray MB. Focal dermal hypoplasia. *Cutis* 1994;53(6):309-12.
8. Tejani Z, Batra P, Mason C, Atherton D. Focal dermal hypoplasia: oral and dental findings. *J Clin Pediatr Dent* 2005;30(1):67-72.
9. Al-Ghamdi K, Crawford PJ. Focal dermal hypoplasia -- oral and dental findings. *Int J Paediatr Dent* 2003;13(2):121-6.
10. Türkmen M, Altıncık A, Ulucan H, Uslu M, Çopcu E, Akdilli A. [Adams-Oliver Syndrome associated with focal dermal hypoplasia]. *Ege Pediatri Bülteni* 2006;13(2):115-8.