

# Basaloid Squamous Cell Carcinoma of the Larynx: Case Report

## Larinksin Bazaloid Skuamöz Hücreli Karsinomu

Güler BERKİTEN,<sup>a</sup>  
Ayça TAZEGÜL MUTLU,<sup>a</sup>  
Tolgar Lütfi KUMRAL,<sup>a</sup>  
Kamil AKDAĞ,<sup>a</sup>  
Yavuz UYAR,<sup>b</sup>  
Gülçin KAMALI<sup>a</sup>

Clinics of  
<sup>a</sup>Otorhinolaryngology Head and Neck Surgery,  
<sup>b</sup>Pathology,  
Okmeydanı Training and Research Hospital, İstanbul

Geliş Tarihi/Received: 20.02.2013  
Kabul Tarihi/Accepted: 30.03.2014

Yazışma Adresi/Correspondence:  
Tolgar Lütfi KUMRAL  
Okmeydanı Training and Research Hospital,  
Clinic of Otorhinolaryngology Head and Neck Surgery, İstanbul,  
TÜRKİYE/TURKEY  
tolgins@hotmail.com

**ABSTRACT** Basaloid squamous cell carcinoma (BSCC), which is a high-grade and rare variant of squamous cell carcinoma, is often located in the head and neck region. It is usually localized in the oropharynx (base of the tongue), hypopharynx (pyriform sinus), and supraglottic laryngeal regions of the upper aerodigestive tract. It is characterized as clinically aggressive and usually diagnosed in its advanced stage as distant metastases. Therefore, aggressive surgical intervention is essential. A 55-year-old patient with a diagnosis of laryngeal squamous cell carcinoma underwent total laryngectomy and bilateral neck dissection because of disease recurrence after radiotherapy. Histological examination revealed the presence of a basaloid squamous cell carcinoma of the larynx. Chemotherapy was planned because of laryngeal recurrence. In our case report, a rare variant (poorly differentiated BSCC of the larynx) is presented with a review of the relevant literature.

**Key Words:** Laryngeal neoplasms; carcinoma, basosquamous; carcinoma, squamous cell; pathology; radiotherapy

**ÖZET** Bazaloid yassı hücreli karsinom, sıklıkla baş boyun bölgesine yerleşmiş, yassı hücreli karsinomun yüksek gradeli ve çok nadir rastlanan varyantıdır. Yerleşim yeri sıklıkla üst aerodigestif traktta orofarinks (dil kökü), hipofarinks (piriform sinüs), ve supraglottik larenks bölgeleridir. Klinik olarak agresif seyredir. Genellikle uzak metastaz yapmış olarak ileri evrede tanı konulur ve bu nedenle agresif cerrahi gerektirir. Yassı hücreli larenks kanseri tanısı ile radyoterapi alan 55 yaşında hastaya 1 yıl sonra larengeal nüks nedeniyle total larenjektomi ve bilateral boyun diseksiyonu uygulandı. Histopatoloji sonucu kötü diferansiye bazaloid tip yassı hücreli karsinomla uyumlu olan hastaya kemoterapi planlandı. Çalışmamızda nadir rastlanan bir varyant olması nedeniyle kötü diferansiye bazaloid tip yassı hücreli larenks kanseri olgusu literatür verileri eşliğinde sunulmuştur.

**Anahtar Kelimeler:** Larinks tümörleri; karsinom, bazoskuamöz; karsinom, skuamöz hücre; patoloji; radyoterapi

Türkiye Klinikleri J Case Rep 2015;23(3):235-8

**B**asaloid squamous cell carcinoma (BSCC) is a high-grade variant of squamous cell carcinoma that comprises several subtypes, such as verrucous, spindle cell, and basaloid carcinoma. BSCC is a rare, aggressive variant that is characterized by proliferation of basaloid cells and intimately associated with squamous cell carcinoma, dysplasia, or focal squamous differentiation.<sup>1</sup> BSCC is localized in mainly the head and neck region. The most frequent localization in the upper aerodigestive tract is the oropharynx (base of the tongue), hypopharynx (pyriform sinus), and supraglottic larynx.<sup>2</sup> Al-

doi: 10.5336/caserep.2013-34739

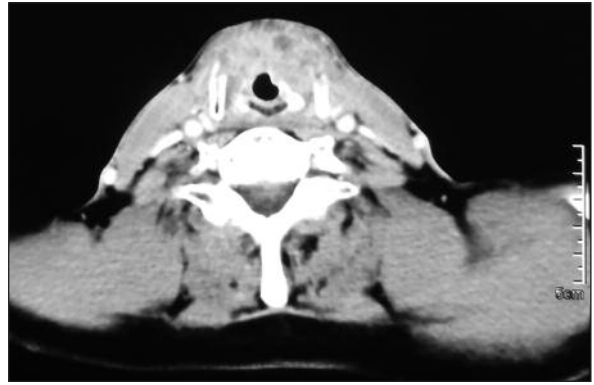
Copyright © 2015 by Türkiye Klinikleri

though BSCC is often present in the cervicofacial region, it can be seen in areas such as the esophagus, lung, thymus, anus, and cervix uteri.<sup>3</sup> It is frequently seen in males with cervical lymph node metastases in the sixth to seventh decades of life.

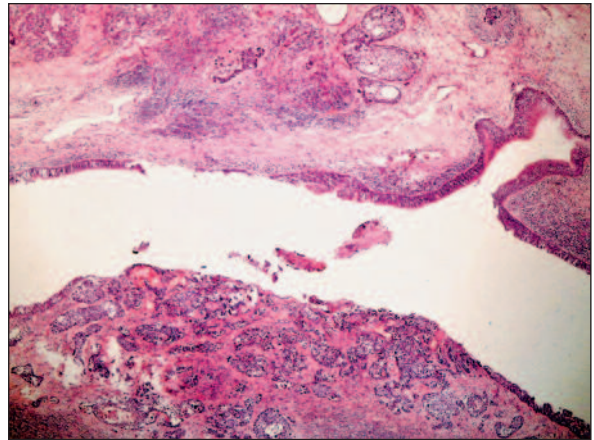
## CASE REPORT

A 55-year-old male patient presented to our clinic with a 2-year history of hoarseness. He had smoked one pack/day for 30 years and had no history of alcohol use. There was an ulcero-vegetative mass along the left vocal cord that restricted the movement of the vocal fold and invaded the anterior commissure as seen on indirect laryngoscopy. There was no invasion in the right vocal cord or subglottic region (Figure 1). Biopsy was performed under general anesthesia with direct laryngoscopy, and the pathological findings were consistent with epidermal in situ carcinoma. There were no pathological lymph nodes on neck computed tomography (CT). Chest X-ray showed no evidence of metastasis. The patient was considered to have T1N0M0 (Stage 1) disease based on these findings. Because the patient refused to undergo an operation, radiotherapy was planned for the primary tumor. The patient underwent curative radiotherapy comprising 66 Gy given in 33 fractions with a 6-meV X-ray device under a thermoplastic linear accelerator mask to the head and neck region.

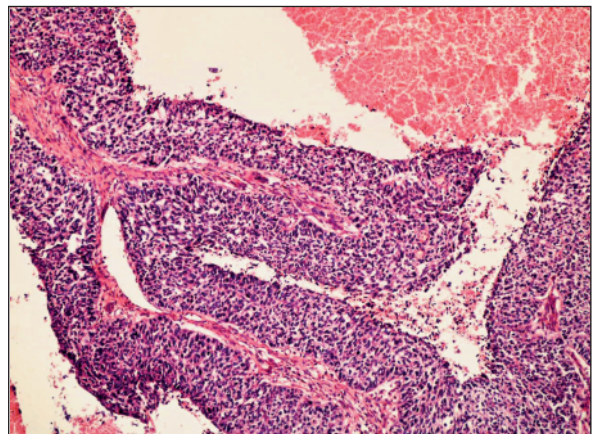
At 18 months, indirect laryngoscopy revealed a left vocal cord lesion extending to the anterior commissure and right vocal cord. The left vocal cord was paralytic. Positron emission tomography-CT (PET-CT) revealed an intense hypermetabolic appearance in the larynx at the level of the anterior commissure. These findings were consistent with malignancy. A biopsy of the left vocal cord mass extending to the anterior commissure and the right cord without subglottic extension was performed under direct laryngoscopy. The biopsy results showed moderately differentiated squamous cell carcinoma. These findings were considered to represent T4N0M0 Stage IV disease. The patient underwent total laryngectomy and bilateral modified radical neck dissection. Pathologic examination confirmed the diagnosis of poorly differentiated BSCC (Figures 2,3). The surgical



**FIGURE 1:** In the axial computed tomography scan (CT), BSCC of the larynx invaded the thyroid cartilage, arytenoid cartilage and showed extralaryngeal extension to the neck.



**FIGURE 2:** BSCC of the larynx in the vocal fold and ventricular fold (HE, x40).



**FIGURE 3:** Islands of uniform basaloid cells with narrow cytoplasm and areas of necrosis (HE, x100)

margins were negative, and there were no metastatic lymph nodes in the neck. Because the tumor was considered to be a recurrence, postoperative chemotherapy was planned to apply the appropriate dose of preoperative RT. Postoperatively, cisplatin (125 mg/m<sup>2</sup>) and docetaxel (120 mg/m<sup>2</sup>) were administered once every 21 days in three cycles. There was no evidence of recurrence at the 1-year follow up.

## DISCUSSION

BSCC is seen in less than 1% of laryngeal carcinomas.<sup>4</sup> BSCC is usually localized in the supraglottic region, but in rare cases can be outside of this region and is sometimes diagnosed at an early stage.<sup>4,5</sup> BSCC is characterized by typically small, crowded cell groups associated with nested in situ and/or invasive squamous cell carcinoma areas that are considered to be highly malignant. These cells usually have hyperchromatic nuclei, little cytoplasm, small cystic spaces, necrosis, and prominent hyalinization. The prognosis is notably poor in patients with nuclear atypia and stromal desmoplasia.<sup>6</sup> Although alcohol and tobacco use plays a role in the etiology of some cases of BSCC, HPV and HSV are more commonly involved.<sup>7,8</sup> The differential diagnoses include squamous cell carcinoma, small-cell neuroendocrine carcinoma, adenoid carcinoma, basal cell adenocarcinoma, adenosquamous carcinoma, spindle-cell squamous cell carcinoma, and mucoepidermoid carcinoma.<sup>9,10</sup> Adenoid carcinoma and small-cell undifferentiated carcinomas can be differentiated by immunohistochemical techniques. In BSCC, 34βE12 is positive and synaptophysin and chromogranin are negative.<sup>10</sup> The signs and symptoms of the disease do not differ from those of squamous cell carcinoma, but the aggressive course attracts attention. BSCC usually appears as a locally advanced tumor at time of diagnosis. BSCC may be multifocal or metastatic. Both regional and distant metastases are common.<sup>11</sup> In a series of 20 patients diagnosed with head and neck

BSCC, Paulino et al. reported five regional lymph node metastases and one lung metastasis.<sup>2</sup> In addition, secondary primary BSCC may develop in cases of primary BSCC.<sup>12</sup> Although there are reports that BSCC can be identified by fine-needle aspiration biopsy (FNAB), the biopsy should be as deep and wide as possible for diagnosis. For this reason, basaloid cells are not included in FNAB samples. Especially in these cases, BSCC may be difficult to distinguish from adenoid carcinoma and undifferentiated small cell carcinoma.<sup>13,14</sup> Because the tumor grows under the surface epithelium, it is not well demarcated. BSCC, even if in the initial view, often shows metastatic or multifocal and deeply invasive features.<sup>1,8</sup> In our patient, BSCC has been reported hardly in the total laryngectomy specimen.

An important method of BSCC staging and follow-up is the combination of CT and fluorodeoxyglucose PET (FDG-PET) imaging of the head and neck. In the literature, radical surgery is recommended after diagnosis and staging. BSCC has a poor prognosis because of its locally aggressive behavior and early regional and distant metastases.<sup>15</sup> Erdamar et al. reported that BSCC is associated with worse survival rates than squamous cell carcinoma.<sup>16</sup> The generally accepted treatment method is radiation therapy after surgery. If there is no distant metastasis, surgical eradication can be achieved with partial or total laryngectomy. Neck dissection should be performed because of the high rate of metastasis in the head and neck region. Because of the aggressive behavior of the tumor, postoperative radiation therapy is recommended.

In general, because BSCC is diagnosed in the advanced stages of the tumor, radiotherapy with surgery should be performed for local control. Because distant metastases are common, adjuvant chemotherapy is recommended.<sup>2,17</sup> Most BSCC show recurrence in the first year; thus, close follow-up should be performed after aggressive treatment.<sup>11</sup>

## REFERENCES

- Bannur HB, Harugop AS, Malur PR, Suranagi VV, Davanageri R, Mastiholmath RD. Basaloid squamous cell carcinoma of the larynx, a rare variant: A case report. *Al Ameen J Med Sci* 2010;3(2):172-4.
- Paulino AF, Singh B, Shah JP, Huvos AG. Basaloid squamous cell carcinoma of the head and neck. *Laryngoscope* 2000;110(9):1479-82.
- Zbären P, Nuyens M, Stauffer E. Basaloid squamous cell carcinoma of the head and neck. *Curr Opin Otolaryngol Head Neck Surg* 2004;12(2):116-21.
- Ferrario F, Spriano G, Macchi A, Piantanida R, Della Vecchia L. [Basaloid-squamous cell carcinoma of the larynx: a new morphologic entity. Case report]. *Acta Otorhinolaryngol Ital* 1998;18(5):338-41.
- Cox JD, Stetz J, Pajak TF. Toxicity criteria of the Radiation Therapy Oncology Group (RTOG) and the European Organization for Research and Treatment of Cancer (EORTC). *Int J Radiat Oncol Biol Phys* 1995;31(5):1341-6.
- Sak SD, Dursun G, Erekuş S, Keser R, Beder E, Gençeker M, et al. [The prognostic significance of histopathologic parameters in squamous cell carcinoma of the larynx]. *Türkiye Klinikleri J Med Res* 1993;11(4):199-201.
- Khalidi L, Apostolidis TCh, Pappa DA, Apostolidis MT, Apostolidis TI. Basaloid squamous carcinoma of the larynx. A potential diagnostic pitfall. *Ann Diagn Pathol* 2006;10(5):297-300.
- Unal M, Polat A, Görür K, Karabacak T, Akbaş Y. Basaloid squamous carcinoma of the larynx and hypopharynx: immunohistopathologic features of two cases. *J Otolaryngol* 2005;34(3):212-5.
- Erisen LM, Coskun H, Ozuysal S, Basut O, Onart S, Hizalan I, et al. Basaloid squamous cell carcinoma of the larynx: a report of four new cases. *Laryngoscope* 2004;114(7):1179-83.
- Choussy O, Bertrand M, François A, Blot E, Hamidou H, Dehesdin D. Basaloid squamous cell carcinoma of the head and neck: report of 18 cases. *J Laryngol Otol* 2011;125(6):608-13.
- Ferlito A, Devaney KO, Rinaldo A. Squamous neoplastic component in unconventional squamous cell carcinomas of the larynx. *Ann Otol Rhinol Laryngol* 1996;105(11):926-32.
- Wan SK, Chan JK, Tse KC. Basaloid-squamous carcinoma of the nasal cavity. *J Laryngol Otol* 1992;106(4):370-1.
- Raslan WF, Barnes L, Krause JR, Contis L, Killeen R, Kapadia SB. Basaloid squamous cell carcinoma of the head and neck: a clinicopathologic and flow cytometric study of 10 new cases with review of the English literature. *Am J Otolaryngol* 1994;15(3):204-11.
- Barnes L, Ferlito A, Altavilla G, MacMillan C, Rinaldo A, Doglioni C. Basaloid squamous cell carcinoma of the head and neck: clinicopathological features and differential diagnosis. *Ann Otol Rhinol Laryngol* 1996;105(1):75-82.
- Sheen Ts, Chang Yi, Ko Jy, Wu Ct, Lee Sy. Basaloid squamous cell carcinoma of the larynx. *Otolaryngol Head Neck Surg* 1999;121(5):647-50.
- Erdamar B, Suoglu Y, Sirin M, Karatay C, Katircioglu S, Kiyak E. Basaloid squamous cell carcinoma of the supraglottic larynx. *Eur Arch Otorhinolaryngol* 2000;257(3):154-7.
- Ferlito A, Altavilla G, Rinaldo A, Doglioni C. Basaloid squamous cell carcinoma of the larynx and hypopharynx. *Ann Otol Rhinol Laryngol* 1997;106(12):1024-35.