

Histopathological Comparison of the Effects of Omeprazole Nitrendipine and Famotidine on Healing of Process of Stress-Induced Gastric Lesions in Rats

OMEPRAZOL, NITRENDİPİN VE FAMOTİDİNİN PATLARDA STRES KAYNAKLI GASTRİK LEZYONLARIN İYİLEŞMESİNE OLAN ETKİLERİNİN HISTOPATOLOJİK AÇIDAN KARŞILAŞTIRILMASI

Serap S.İNALÖZ*, Yurdağül CANBERK**, Mehmet ÖZAYDIN***, Engin YENİLMEZ**, İbrahim SARI***, Güner ULAK****, Vedat GÖRAL*****, Necati YENİCE*****

Depts. of 'Histology&Embr/ology, ""Pathology, ""Pharmacology, ""Gastroenterology, Faculty of Medicine, University of Dicle, DİYARBAKIR

"Dept. of Histology&Embryology, Faculty of Medicine, University of Istanbul, ISTANBUL

SUMMARY

In this study, the healing effects of omeprazole, nitrendipine and famotidine against gastric stress ulcers were investigated in rats. Forty male Wistar-albino rats were separated into five groups (n=8), a control (non-stress) and four experimental (stress) groups. Experimental rats were treated with omeprazole, nitrendipine, famotidine or a placebo after the stresses of starvation and cold-restraint. Omeprazole inhibits gastric acid by blocking the proton pump of the gastric parietal cell. Nitrendipine is a derivative of the dihydropyridine group of calcium channel blockers and administrated for angina and hypertension. Famotidine is one of the newer histamine H2 receptor antagonists and heals the gastric and duodenal ulcers by reducing gastric acid output.

In conclusion, the effects of omeprazole, nitrendipine and famotidine against stress ulcers were investigated histologically and comparatively for healing process in the stress groups. Pronounced vascular congestion and coagulation necrosis of the mucosa were noticed in the placebo group. In the omeprazole treated group, chronic inflammatory cells infiltrate was significantly reduced in the lamina propria. The regeneration effect of omeprazole was found superior to nitrendipine and famotidine.

Key Words: Famotidine, Histopathology, Nitrendipine, Omeprazole, Stress ulcer

T Klin J Gastroenterohepatol 1996, 7:76-80

Stress ulcers may occur rapidly after starvation, immobility, hemorrhage, sepsis, head injury, respiratory failure, major physical or thermal trauma. They

Geliş Tarihi: 21.05.1996

Yazışma Adresi: Dr.Serap S.İNALÖZ
Dept. of Histology&Embryology,
Faculty of Medicine, University of Dicle,
DİYARBAKIR

ÖZET

Bu çalışmada raflarda strese bağlı gastrik ülserlerine karşı Omeprazol, nitrendipin ve famotidin'in iyileştirici etkileri araştırıldı. Kırk adet erkek Wistar-albino rat biri kontrol (non stres), dördü deney (stres) olmak üzere beş gruba ayrıldı. Ratlara açlık ve soğuk- hareketsizlik stresi sonrası Omeprazol, nitrendipin, famotidin veya placebo ile tedavi uygulandı. Omeprazol mide parietal hücre/erindeki proton pompasını bloke etmek suretiyle mide asidini inhibe etmektedir. Nitrendipin, dihidropiridin türevi bir kalsiyum kanal blokeri olup anjina ve hipertansiyon için kullanılmaktadır. Famotidin histamin H2 reseptör antagonistlerinden biridir ve gastrik ve duodenal ülserleri gastrik asit salımını azaltarak iyileştirir.

Sonuç olarak stres gruplarında, omeprazol, nitrendipin ve famotidin'in stres ülserlerinin iyileşme sürecine olan etkisi histolojik ve karşılaştırmak olarak incelendi. Placebo grubunda mukozada vasküler konjesyon ve koagülasyon nekrozu dikkati çekti. Omeprazol ile tedavi grubunda lamina propriada kronik inflamatuvar hücre infiltrasyonu anlamlı derecede az bulundu. Omeprazolün rejenerasyon etkisi nitrendipin ve famotidinden daha fazla bulundu.

Anahtar Kelimeler. Famotidin, Nitrendipin, Omeprazol, Stres ülseri, Histopatoloji

T. Klin J Gastroenterohepatoloji 1996, 7:76-80

are characterised by superficial and multiple erosions that occurs primarily in the fundus of the stomach (1). The basic mechanisms involved in the development of stress ulcers have been significantly understood in the last decade. The pathological basis for the development of this lesion has been postulated to be multifactorial: 1) increased gastric motility, 2) increased gastric acid secretion, 3) diminished gastric mucosal blood flow, 4) disruption of gastric mucosa barrier, 5) in-

hibition of gastric mucus and bicarbonate secretion, 6) inhibition of mucosal prostaglandin synthesis (2-5).

Although we have learned considerably more about the pathogenesis of stress ulcers, treatment decisions have become more complicated. Before 1977, the treatment of gastroduodenal ulcer disease consisted primarily of dietary, antacid and anticholinergic programs (6). Nowadays, various drugs are administered for the treatment of gastroduodenal ulcer disease. Omeprazole inhibits gastric acid by blocking the hydrogen-potassium adenosine triphosphatase enzyme system (the proton pump) of the gastric parietal cell (7). Nitrendipine is a member of dihydropyridine group of calcium channel blockers and has been reported to protect against stress-induced ulcer formation in rats (8). Famotidine is a histamine H₂ receptor antagonist and has been shown to prevent the formation of gastric mucosal lesions by inhibiting the secretion of gastric acid in rats (9).

There are many studies concerning the efficacy of omeprazole, nitrendipine and famotidine against stress-induced gastric ulcers, however; a few histopathologic reports have been encountered on this issue in the literature. The aim of the present study is to assess and compare histologically the therapeutic effects of omeprazole, nitrendipine and famotidine on stress-induced gastric lesions in rats.

MATERIALS AND METHODS

Forty male adult Wistar-albino rats (200-250 gr) were separated into five groups (n=8), a control (non-stress) group and four experimental (stress) groups. Experimental rats (n=32) were kept without food two days and without water one day before the experiment. They were packed so as to be immobile with wire mesh and put in a refrigerator at 4°C for four hours. Experimental rats were confined in lattice cages to prevent coprophagy during the experiment. All rats were fed standard pellet food during the experiment. The first stress group was only given saline or DMSO (Dimethyl sulfoxide) during two weeks. Omeprazole (Ilsan-İltas) was administered by oral gavage (intra-gastric) in 40 mg/kg/day dosage to the second stress group for two weeks. Nitrendipine (Bayer) was given by oral gavage (i.g.) in a dosage of 40 mg/kg/day to the third stress group for two weeks. The third stress group was given famotidine (Fako) by oral gavage in the same dosage and duration. After two weeks, experimental rats were sacrificed and their stomachs were removed. The dissected pieces were put into 10% formaldehyde fixative solution and were embedded into paraffin blocks. The tissues were cut into 4 µm (micron) thickness with microtome and stained with Hematoxylin-Eosin (H&E). Histological assessments were done under a light microscope.

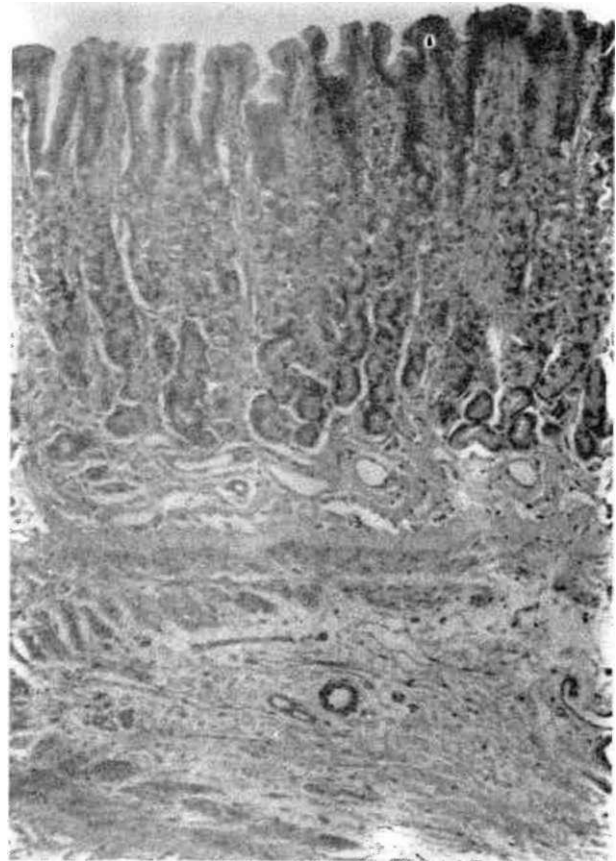


Figure 1. Normal gastric mucosa with simple columnar mucous epithelium and normal lamina propria, in the control group (H&E, original magnificationx41)

RESULTS

In histological examination, normal gastric mucosa with a simple columnar mucous epithelium and normal lamina propria were seen in the control group (Figure 1). Gastric mucosal lesions were noticed in all stress groups. Pronounced vascular congestion and coagulation necrosis of the mucosa were noticed particularly in the first stress (placebo) group (Figure 2,3). Mixed type dense inflammatory cell infiltrate was seen in the lamina propria which predominantly consisted of eosinophils. Microscopic appearances were similar to the eosinophilic gastritis in the placebo group (Figure 3).

Vascular congestion was considerably diminished and regeneration tissue was conspicuous in the second stress group rats which were treated with omeprazole. Chronic inflammatory cell infiltrate was significantly reduced in the lamina propria and predominantly consisted of eosinophils (Figure 4).

Similar findings were also noticed in the third stress group rats administered with nitrendipine. However, conspicuous vascular congestions were seen in the mucosa. In some areas, eosinophilic inflammatory

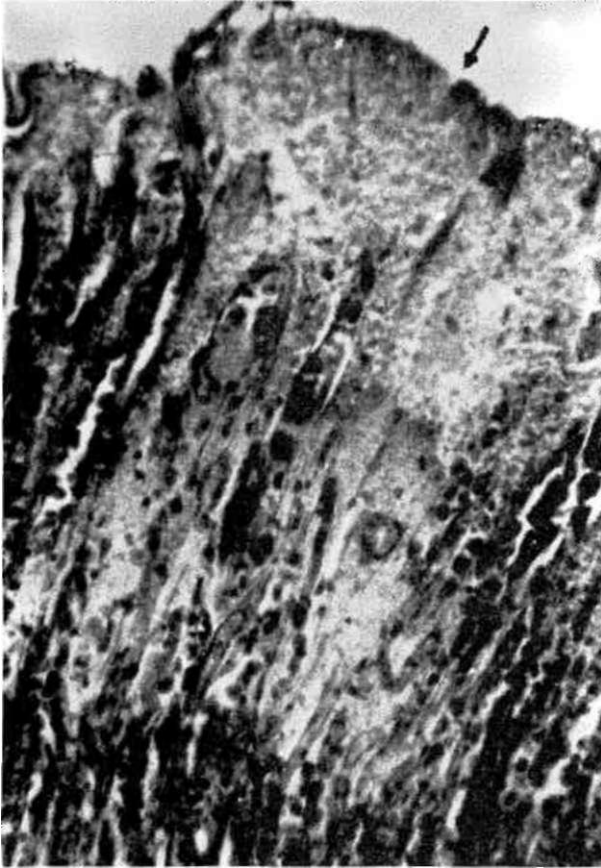


Figure 2. The area of a coagulation necrosis of the mucosa (arrow), in the stress (placebo) group (H&E, original magnificationx82).

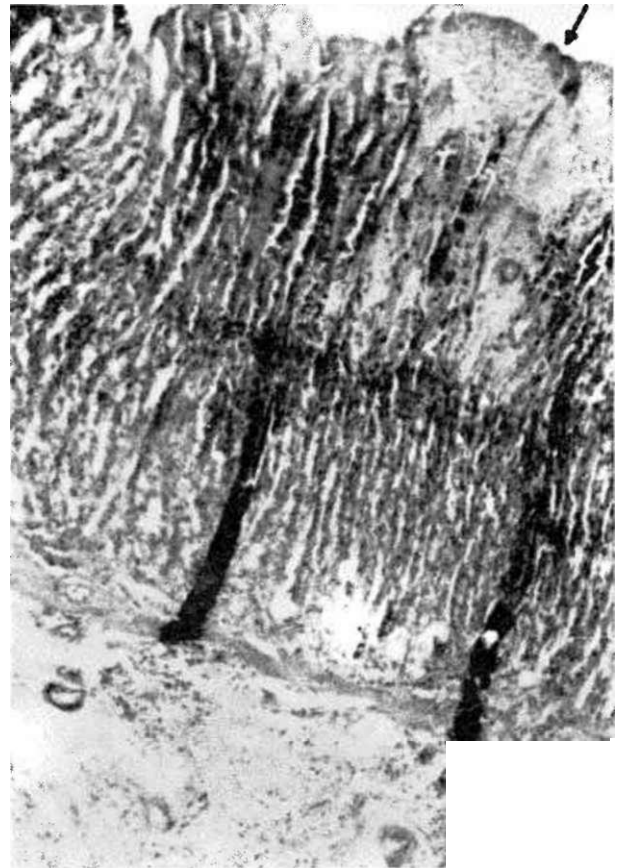


Figure 3. in the stress (placebo) group, coagulation necrosis of the mucosa (arrow) and mixed type dense inflammatory cell infiltrate which predominantly consists of eosinophils in the lamina propria (H&E, original magnificationx41).

cell infiltrate was noticed in the lamina propria. Tissue regeneration was observed, however, it was not conspicuous as in the omeprazole treated group (Figure 5).

Tissue regeneration was slightly observed in the famotidine treated group. Dense mononuclear inflammatory cell infiltrate was seen in some areas of the lamina propria. In one area, dense lymphocytic inflammatory cell infiltration particularly in the submucosa was progressed into the tunica mucosa near to the gastric lumen (Figure 6). The regenerative effect of famotidine was less noticed than in the omeprazole and nitrendipine treated groups.

DISCUSSION

The development in the medical treatment of peptic ulcers is leading to reduce the number of the elective surgical operations. It has been recently shown that the H⁺/K⁺-ATPase inhibitor omeprazole, is effective in the management of severe resistant reflux disease with peptic stricture formation, leading to a reduction in the number of oesophageal dilatations which required by up to 60% of these patients (10). Omeprazole was found to cause no changes in the pa-

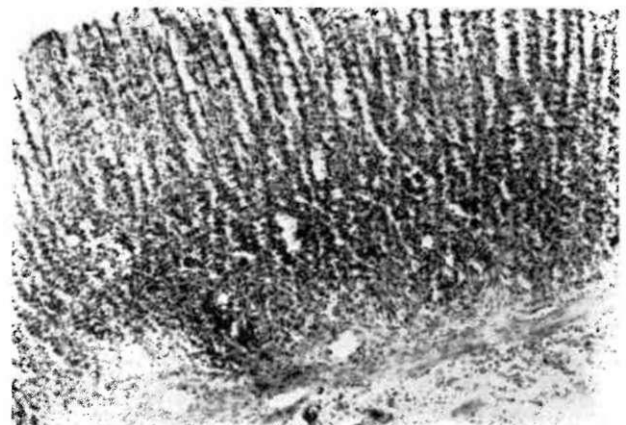


Figure 4. in the omeprazole treated group, normal architecture of the epithelium and sparse inflammatory cell infiltrate which predominantly consists of eosinophils in the lamina propria and submucosa (H&E, original magnificationx41).

rietal cell structure (11). The effects of omeprazole on developing rat stomach mucosa were investigated in a



Figure 5. in the nitrendipine treated group, vascular formation with conspicuous congestion in the mucosa (arrow) and eosinophilic inflammatory cell infiltrate with congestive vascularity in the lamina propria and submucosa (arrowheads) (H&E, original magnificationx41).

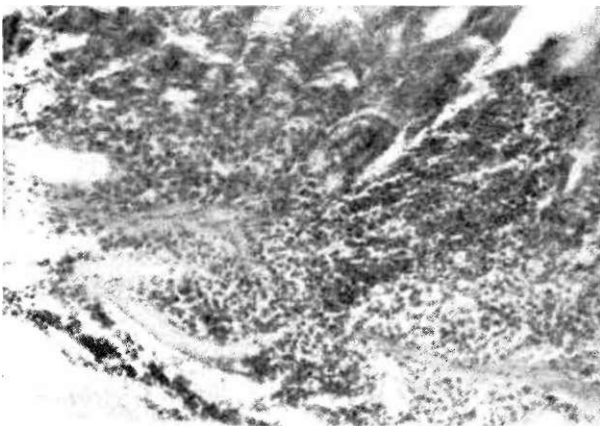

Figure 6. In the famotidine treated group, regression area of a progressive lymphocytic inflammatory cell infiltrate from the submucosa into the gastric lumen (H&E, original magnificationx82).

study and found to cause an elevation of mucosal pH and a suppression in mucosal pepsinogen and its mRNA levels during stomach development. Histolog-

ically these changes were associated with a reduction in mature pepsinogen-producing cells throughout stomach mucosa (12). Omeprazole may exert an effect on gastric mucosal proliferation by inhibiting gastric acid secretion and long term omeprazole therapy in humans results in moderate hypergastrinemia (13,14). In one study, omeprazole was found to inhibit stress ulcer formation which is caused by thyrotropin-releasing hormone (TRH). Furthermore, in this study it has been suggested that omeprazole has an inhibitory effect on TRH release under stress ulcer (15).

Nitrendipine is a derivative of the dihydropyridine group calcium channel blockers and is released for prophylaxis and treatment of angina and hypertension (7). However, calcium was found as an important element in gastric ulcer pathophysiology in several studies (18,17). Calcium has a positive effect on gastrin releasing and gastric acid secretion (17) and is also important in the release of histamine from the mast cells within the gastric mucosa (18).

The concept of the administration of calcium channel blockers in the treatment of gastric lesions basically depends on the positive effects of calcium on the releasing of gastrin, gastric acid, and histamine respectively.

The effects of nitrendipine on stress-induced acute gastric lesions were investigated in rats and they suggested that the gastroprotective effects of calcium channel blockers is of great value in the development of new and improved therapies for treatment and prevention of gastric ulcers in humans (8). In our study, nitrendipine was found effective against stress ulcer formation (Figure 5).

It has been shown that histamine has an essential role in the pathogenesis of stress ulcers since it is a potent stimulant of gastric acid secretion (19). The structural similarities of H₂ receptor antagonists to histamine cause a competitive inhibition for H₂ receptors in the parietal cell. This results in inhibition of gastric acid secretion and thus prevents the gastric mucosal barrier damage produced by HCl. Famotidine was found to significantly increase duodenal pH (20). However, the gastroprotective effect of famotidine is thought to be attributable not only to the suppression of acid secretion, but also to the activation of the mucosal defensive factors such as mucosal blood flow, mucus glycoproteins and bicarbonate secretion (21). In a group study, it was found that famotidine had no protective effect against the formation of gastric lesions induced by absolute ethanol and 1% NH₃, but, famotidine inhibited the acetylsalicylic acid and water-immersion stress-induced gastric lesions in rats (22). In our study, the regeneration effect of famotidine against stress ulcer formation was found to be less than omeprazole and nitrendipine (Figure 6).

In conclusion, omeprazole, nitrendipine and famotidine were found effective against gastric stress ulcer formation. However, omeprazole was superior to nitrendipine and famotidine in the healing process with conspicuous tissue regeneration (Figure 4,5,6).

REFERENCES

1. Cheung LY. Pathogenesis, prophylaxis, and treatment of stress gastritis. *The Am J Surg* 1988; 156:437-40.
2. Miller T. protective effects of prostaglandins against gastric mucosal damage: current knowledge and proposed mechanism. *Am J Physiol* 1983; 245:601-23.
3. Bresalier RS. The clinical significance and pathophysiology of stress-related gastric mucosal hemorrhage. *J Clin Gastroenterol* 1991; 13(suppl 2):35-43.
4. Garrick T, Buack S, Bass P. Gastric motility is a major factor in cold restraint-induced lesion formation in rats. *Am J Physiol* 1986; 250:191-9.
5. Andrew HS. Gastric, duodenal, and stress ulcer. In: Sleisenger MH, ed. *Gastrointestinal disease*, Vol 1, 5th ed. Philadelphia: WB Saunders Co, 1993:652-79.
6. Clearfield HR. Challenges in acid/peptic disorders. A symposium overview. *Aliment Pharmacol Ther* 1991; 1(5): 1-4.
7. Kayaalp SO. Rasyonel tedavi yönünden tıbbi farmakoloji, e.baskı. Ankara: Feryal Matbaacılık, 1992:1125,1214, 1993:2929-30, 3153-4.
8. Ulak G, Cingi Mİ, Erol K. Gastroprotective effect of nitrendipine on stress-induced gastric lesions in rats. *Pharmacology* 1991; 43(4):220-4.
9. Okase S, Nobuhara Y. Effects of famotidine, a histamine H₂-receptor antagonist, on gastric secretion and duodenal lesions in rats. *Pharmacometrics* 1984; 27:56-9.
10. Carr SC, Wicks AC. Management of peptic duodenal stricture. *Dig Dis* 1993; 11(4-5):197-205.
11. Rubinstein E, Hojgaard L. The effect of intravenous omeprazole on the gastric and duodenal potential difference and pH in healthy subjects. *Digestion* 1993; 54(1):15-8.
12. Kakei N, Ichinose M, Tsukada S et al. Effects of omeprazole on gastric mucosal growth and differentiation in developing rat. *Biochem Biophys Res Commun* 1994; 197(1):310-8.
13. Lamberts R, Creutzfeldt W, Struber HG et al. Long-term omeprazole therapy in peptic ulcer disease: Gastrin, endocrine cell growth, and gastritis. *Gastroenterology* 1993; 104(5):1356-70.
14. Valentin M, Bortoluzzi F, Cernigoi C et al. Effect of short and long-term treatment with omeprazole on cycle distribution in the gastric mucosa. Results of a flow cytometric study. *Scand J Gastroenterol* 1993; 28(7):617-21.
15. Uchida K, Mitsuma T, Morise K et al. The role of thyrotropin releasing hormone (TRH) in the pathogenesis of water-immersion stress in rats inhibition of TRH release from the stomach by atropine, ranitidine or omeprazole. *Gastroenterol Jpn* 1993; 28(1):1-9,
16. Christiansen J, Kirkegaard P, Olsen PS et al. Interaction of calcium and gastrin on gastric acid secretion in duodenal ulcer patients. *Gut* 1984; 25:174-7.
17. Harty RF, Maico DG, Mc Guigon JE. Role of calcium in antral gastrin release. *Gastroenterology* 1981; 80:491-7.
18. Rangachari PK. Histamine release by gastric stimulants. *Nature* 1975; 253:53-4.
19. Dai S, Ogle CW, Lo CH. The effects of metiamide on gastric secretion and stress ulceration in rats. *Eur J Pharmacol* 1975; 33:277-81.
20. Kusano M, Sekiguchi T, Nishioka T, Kawamura O et al. Gastric acid inhibits antral phase III activity in duodenal ulcer patients. *Dig Dis Sci* 1993; 38(51):824-31.
21. Miyata K, Kamato T, Nishida A, Honda K. Studies on the mechanism for the gastric mucosal protection by famotidine in rats. *Japan J Pharmacol* 1991; 55:211-22.
22. Sekiguchi H, Hamada K, Taga F, Nishino K. Effects of the new histamine H₂ receptor antagonist N-ethyl-N-[3-(3-(piperidinomethyl) phenoxy) propyl]urea with potent gastric mucosal protective activity on acute gastric lesions and duodenal ulcers in rats. *Arzneimittelforschung* 1993; 43(2): 134-8.