

Anesthetic Management in Patients with Epidermolysis Bullosa: Two Case Reports

Epidermolizis Büllozal Hastada Anestezi Yönetimi: İki Olgu Sunumu

- Enes ÇELİK,^a
 Zeynep BAYSAL YILDIRIM,^a
 Feyzi ÇELİK,^a
 Gönül ÖLMEZ KAVAK,^a
 Mustafa BIÇAK^a

^aDepartment of Anesthesiology and Reanimation,
 Dicle University Faculty of Medicine,
 Diyarbakır

Received: 02.02.2018
 Received in revised form: 19.05.2018
 Accepted: 24.05.2018
 Available online: 26.09.2018

Correspondence:
 Enes ÇELİK
 Dicle University Faculty of Medicine,
 Department of Anesthesiology and Reanimation, Diyarbakır,
 TURKEY/TURKİYE
 ec_1907@hotmail.com

This study was carried out in TARK-2017 -
 Turkish Anesthesiology and Reanimation
 Association 51st National Congress
 (25-29 October 2017, Antalya)
 presented as a paper.

ABSTRACT Epidermolysis bullosa (EB) is a genetic disorder characterized by spontaneous or post-traumatic bullae developed in the skin and mucous membranes. General characteristics of these patients: scars that limit the opening of the mouth, esophageal constriction, dehydration, malnutrition, anemia, hypoalbuminemia, electrolyte imbalance, thrombocytosis, and infections. Lesions that may spread throughout the body in cases with EB may lead to bleeding, scar tissues, contractures and edema, difficult airway, and difficult vascular access. The most important approach in these groups of patients who need anesthesia for treatment and therapeutic interventions is to protect the integrity of skin and mucous membranes, to secure a reliable airway, to prevent the loss of heat and liquid, and to provide efficient perioperative analgesia. In this report, the anesthetic approach for two cases with an EB diagnosis is presented accompanied by the literature.

Keywords: Epidermolysis bullosa; general anesthesia; difficult airway; peroperative care

ÖZET Epidermolizis bülloza (EB), cilt ve mukozalarda kendiliğinden veya travma sonrası gelişen büllelerle karakterize genetik geçişli bir hastalıktır. Bu hastaların genel özellikleri; ağız açıklığını kısıtlayan skarlar, özofageal darlıklar, dehidratasyon, malnütrisyon, anemi, hipoalbuminemi, elektrolit dengesizliği, trombositoz ve enfeksiyonlardır. EB'li olgularda vücudun geneline yayılabilen lezyonlar, kanama, skar dokusu, kontraktürler ve ödem, zor havayolu ve zor damar yolu erişimine neden olabilir. Tanı ve tedavi edici girişimler için anestezi alması gereken bu grup hastalardaki en önemli yaklaşım, cilt ve müköz membranların bütünlüğünün korunması, güvenli bir havayolu sağlanması, ısı ve sıvı kaybının önlenmesi ve etkili bir perioperatif analjezi sağlanmasıdır. Bu yazıda EB tanısı konulmuş iki olguya uygulanan anestezi yaklaşım literatür eşliğinde sunulmuştur.

Anahtar Kelimeler: Epidermolizis bülloza; genel anestezi; zor havayolu; perioperatif bakım

Epidermolysis bullosa (EB) is a rare disease characterized by vesiculobullous lesions developed with minimal trauma to the skin and mucous membranes. It is observed at a frequency of 1/30 000. General characteristics of these patients: scars that limit the opening of the mouth, esophageal constriction, dehydration, malnutrition, anemia, hypoalbuminemia, electrolyte imbalance, thrombocytosis, and infections.¹

In addition, temporomandibular joint involvement, which is very important in terms of maintaining the airway opening, can be seen, and unwanted airway problems may be encountered due to the bullae that may

develop at the pharynx and larynx. Amyloidosis, porphyria, multiple myeloma, hypercoagulability, and mitral valve prolapse can be seen in conjunction with this disease.²

In these two cases, we wanted to draw attention to the difficult airways in patients with EB and to the causes leading to the formation of new perioperative bullae and to share the applications that may be implemented for this purpose.

CASE PRESENTATION

CASE 1

Thirteen year old girl, 40 kg, who referred to the plastic and reconstructive surgery clinic due to pseudosyndactyly, was prepared for the operation. The Mallampati evaluation was not carried out in the anesthesia assessment at the polyclinics due to the fact that mouth opening was restricted. Pseudosyndactyly was also present on the feet of the patient. There were no abnormalities in her hemogram and blood biochemistry tests other than hypochrome microcytic anemia. The patient, whose vascular access was established earlier, was taken to the operating room before premedication procedures were carried out as the patient might have a difficult airway. Contact with the patient was restricted as much as possible because every kind of contact and trauma could lead to edema with EB patients. For this reason, the patient was asked to go to the surgery table herself. Care was taken to ensure that the bedding underneath the patient was flat. The patient's position was set by pulling from the cover cloth. Wet cotton was placed under the blood pressure machine and her blood pressure was checked as less frequently as possible, about once every 10-15 minutes. This way, efforts were made to prevent the development of new bullae and edemas. ECG electrodes were not used as mentioned in new approaches. Experiences we had from previous trials have shown us that even if electrodes are made of special material, they may cause the development of new bullae. For oxygen saturation and pulse monitoring, a pulse oximeter was used that did not exert

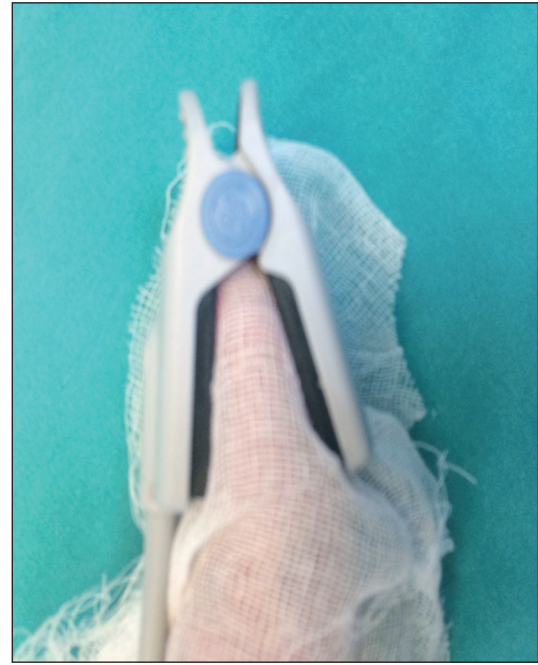


FIGURE 1: Oxygen saturation and pulse monitoring.

any pressure on the finger, was non-adhesive, and held the finger on both sides (Figure 1). Eye ointment was applied to the eyes to prevent damage to the eyelids or to prevent corneal injuries. When facial masks were used, care was taken to apply as little force as possible to avoid any force that may peel the skin and to prevent the formation of edema. In order to reduce the effect of a serious trauma, the masks were lubricated with vaseline. Likewise, in order to reduce trauma in the mouth and the pharynx, the blade and the intubation tube to be used were lubricated with a water-based gel. Due to the possibility of difficult intubation and difficult airway, LMA, I-gel, endotracheal intubation tubes, laryngoscope blades, and video laryngoscope were prepared in different sizes before starting to induction of anesthesia. After applying pre-oxygenation, 1 mg midazolam, 2 mg/ kg propofol, 0,6 mg/ kg rocuronium, and 40 mcg fentanyl were injected by using intravenous (iv) catheter during induction of anesthesia. Ventilation was intermittently provided with minimal contact with the mask, and, with the help of an experienced anesthetist, the patient was intubated with a cuffed endotracheal tube no. 5.5 using a video laryngoscope. In order to re-

duce pressure on the airway, a small-sized tube was preferred. The cuff was inflated with the lowest pressure in order to make sure that no air leak took place. The tube was fixed by binding it with a large wrapping cloth so as not to press on the skin (Figure 2). 2% sevoflurane, 50% air/O₂ thus continuing to administer anesthesia. At the end of the operation, which lasted for 160 minutes, as the subject had a difficult airway, the non-depolarizing muscle relaxant effect was antagonized by using 100 mg sugammadex. In order to prevent traumas that may be caused by agitations due to post-operative pain, multimodal pain method was implemented. For this purpose, 300 mg paracetamol and 20 mg tramadol were administered. In order to prevent any trauma from happening as a result of post-operative itching, the use of opioids was restricted. The patient was taken to the recovery room, and after about 20 minutes of monitoring in the recovery room, was sent to the clinic without any problems.

CASE 2

Fourteen year old male patient, 25 kg was referred to surgery for pseudosyndactyly on the hand by the plastic and reconstruction surgery clinic. During the physical examination of the patient, who had growth and development retardation, pullae lesions were discovered in different phases on the body, and pseudosyndactyly was seen on his hands. Mallampati could not be evaluated as his mouth opening was constricted (Figure 3). The patient, who was not premedicated was put on the table without help. Cotton was wrapped around the blood pressure apparatus encircling the patient's arm, ECG electrodes were not attached (Figure 4). The face mask was lubricated with vaseline and placed on the patient's face without pressure. Midazolam 1 mg, propofol 2 mg/ kg , rocuronium 0.6 mg/ kg, and fentanyl 25 mcg were administered, and endotracheal intubation was performed with a 5,0 cuffed endotracheal tube by using a video laryngoscope due to the probability of difficult intubation (Figure 5) Eye protection was provided with antibiotic pomade. The patient's anesthesia was administered with 50% O₂ / air, 2% sevoflurane. 300

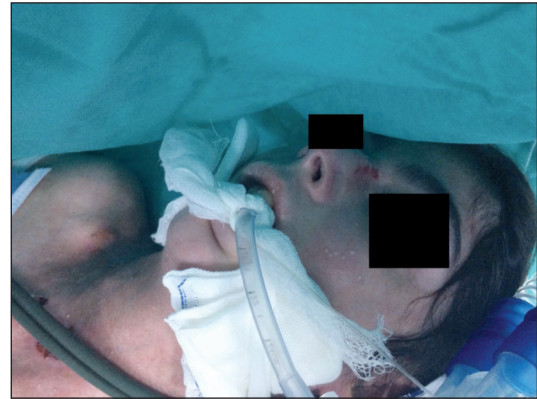

FIGURE 2: Endotracheal tube binding.

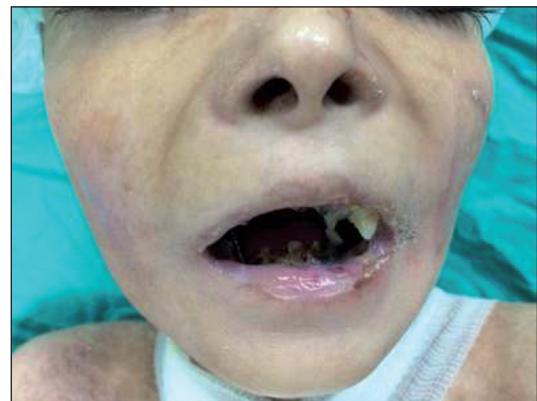

FIGURE 3: Mouth opening.

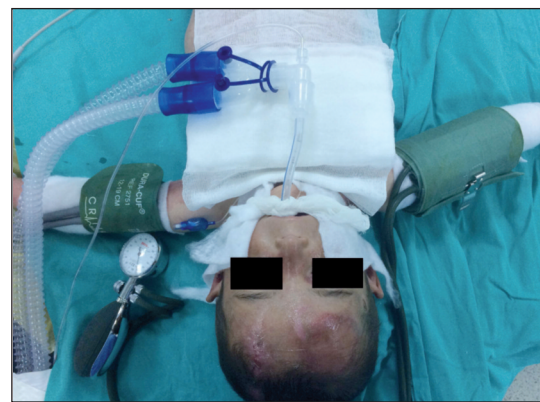

FIGURE 4: The blood pressure apparatus encircling the patient's arm.

mg paracetamol and 10 mg tramadol were used for postoperative analgesia. The patient was treated with 1 mg/ kg sugammadex and no complications occurred in the surgical operation and anesthesia management that lasted 100 minutes. He was evaluated by pulse monitorization in the recovery room. The Aldrete scoring system was used for de-

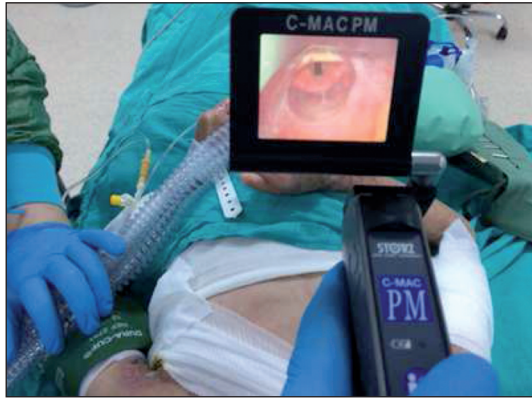

FIGURE 5: Endotracheal intubation with Videolaryngoscope.

termining when patient can be discharged from recovery room. The patient's Aldrete score was determined to be 12 at the 15th minute. And the patient was transferred to the clinic.

DISCUSSION

Given the level of the development of bullae at the epidermal basal membrane zone, together with the fact that epidermal bullae has over 20 subtypes, it can be classified as simplex type, junctional type, and dystrophic type. Dystrophic epidermolysis bullosa is the most commonly seen group. Patients with EB may undergo surgical operations several times during their life, depending on the nature of the disease. As it most commonly affects the skin and soft tissues, the most widely performed surgical operations are those carried out on reconstructive operations on the extremities, dental operations, pseudosyndactylia, caesarean, esophageal dilation that includes the gastrointestinal system, gastronomy, and colon interposition operations.³

In epidermolysis bullosa patients preoperative evaluation is very important. Because due to the restriction in the mouth opening of this patient group and because of the probability of the development of scar tissue in the vicinity of their mouths, difficulties may be encountered in the intubation process. Moreover, as observed in our cases as well, EB patients are generally found to have a cachectic appearance and suffer from malnutrition, anaemia, and electrolyte disorders. Because of these disor-

ders, hypoalbuminemia is seen among them, which affects the pharmacokinetic and pharmacodynamic properties of the anaesthetic drugs used.⁴

Regional anesthesia should be preferred, if possible, in patients with EB because of the increased restriction in the airways of these patients, and the probable development of new bullae on the airway, as well as on the oral mucus membranes of these patients.⁵ In contemporary literature, the development of new bullae and the emergence of complications have not been observed in procedures where intubation tubes and laryngoscope blades have been lubricated with water-based creams or antibiotic pomades. Yet again, contrary to the prevailing belief, the fact that regional anaesthesia does not cause the development of bullae and the fact that it provides appropriate anaesthesia with sedation, even in children, regional anesthesia is more preferred nowadays.⁶ In a study involving 19 patients, including children, regional anaesthesia was performed with axillary block anaesthesia such as pseudosyndactyly without any complications.^{7,8}

In cases where intubation is difficult, fiberoptic nasal intubation is preferred.^{9,10}

Propofol is preferred in patients with epidermolysis bullosa in intravenous induction. Succinylcholine as a myorelaxant is not preferred because of the probability of minor trauma due to fasciculation and because of the risk of hyperkalemia. Non-depolarizing agents are used for this purpose.¹¹

Fentanyl is the most commonly used agent for analgesia. However, due to the fact that it may cause itching, the dose should be reduced and necessary precautions should be taken. For this purpose, opiate dose should be reduced and multimodal pain management should be applied. Multimodal pain approach should be preferred for postoperative analgesia. It should not be forgotten that good pain management will reduce the agitation of the postoperative patient, and prevent the formation of new traumas. For this reason, the combination of non-steroidal drugs and opiates should be preferred.

Prevention of new bullea in EB patients is as important as airway and anaesthesia management. Anxiety should be reduced by giving the patient detailed knowledge.¹² Afterwards, if possible the patient must be handed over the operating table by himself or herself. There should be as little contact with the patient as possible during patient transfer and taking the patient to the operating table. If the operating table is hard, it should be made appropriate with covers or tampons.¹³ New lesions may be caused during ECG monitoring even if gels are applied to electrodes or if special material are used. We refrain from performing ECG as much as possible. We followed up the cardiac rhythm in our patients with saturation probe.¹⁴ Wrapping with cotton where the blood pressure apparatus touches the arm prevents the formation of new lesions. Antibiotic pomades may be used and the eyes may be covered with wet pads to prevent corneal damages.

Anaesthesia management should start with the referral of the epidermolysis bullosa patient to the anaesthesia polyclinic. For the management of the patient, the surgical team should collaborate with the operating room staff and the assistant healthcare staff in an organized manner, to manage the surgical process of the patient comfortably and without causing new trauma to him/her. Keeping in mind that

every new trauma may cause serious complications such as infection or squamous cell carcinoma, one can comprehend how important this is.

Informed Consent

Oral and written consent was obtained from the first degree relatives of the patient and the patient.

Source of Finance

During this study, no financial or spiritual support was received neither from any pharmaceutical company that has a direct connection with the research subject, nor from a company that provides or produces medical instruments and materials which may negatively affect the evaluation process of this study.

Conflict of Interest

No conflicts of interest between the authors and / or family members of the scientific and medical committee members or members of the potential conflicts of interest, counseling, expertise, working conditions, share holding and similar situations in any firm.

Authorship Contributions

Idea/Concept: Enes Çelik, Zeynep Baysal Yıldırım; **Design:** Enes Çelik; **Supervision/Consultancy:** Enes Çelik; **Data Collection and / or Processing:** Enes Çelik; **Analysis and/or Interpretation:** Mustafa Bıçak; **Source Browsing:** Feyzi Çelik; **Author of the Production:** Enes Çelik; **Critical Review:** Gönül Ölmez Kavak; **Resources and Funding:** Feyzi Çelik; **Materials:** Mustafa Bıçak.

REFERENCES

- Nandi R, Howard R. Anesthesia and epidermolysis bullosa. *Dermatol Clin* 2010;28(2): 319-24.
- Smith MF. Skin and connective tissue diseases. In: Katz J, Stevert DJ, eds. *Anesthesia and Uncommon Pediatric Diseases*. 2nd ed. Philadelphia: WB Saunders Company; 1995. p.509-12.
- Şahin SH, Alkin Ç, Cavidan A, Ali S. [Anesthetic management of a patient with epidermolysis bullosa: case report]. *Turkiye Klinikleri J Anest Reanim* 2010;8(2):57-60.
- Hagen R, Langenberg C. Anaesthetic management in patients with epidermolysis bullosa dystrophica. *Anaesthesia* 1988;43(6):482-85.
- Culpepper TL. Anaesthesia implications in epidermolysis bullosa dystrophica. *AANA J* 2001;69(2):114-8.
- Englbrecht JS, Langer M, Hahnenkamp K, Ellger B. Ultrasound-guided axillary plexus block in a child with dystrophic epidermolysis bullosa. *Anaesth Intensive Care* 2010;38(6): 1101-5.
- van den Heuvel I, Gottschalk A, Langer M, Hahnenkamp K, Ellger B. Feasibility, efficacy, and safety of ultrasound-guided axillary plexus blockade in pediatric patients with epidermolysis bullosa dystrophica. *Paediatr Anaesth* 2016;26(4):405-8.
- Lin YC, Golianu B. Anesthesia and pain management for pediatric patients with dystrophic epidermolysis bullosa. *J Clin Anesth* 2006;18(4):268-71.
- Maxwell LG, Goodwin SR, Mancuso TJ, Victor CB, Zuckenberg AL, Morgan PG, et al. *Systemic disorders. Smith's Anaesthesia for Infants and Children*. 8th ed. Philadelphia: Elsevier Mosby; 2011. p.1171-84.
- Lindemeyer R, Wadenya R, Maxwell L. Dental and anaesthetic management of children with dystrophic epidermolysis bullosa. *Int J Paediatr Dent* 2009;19(2):127-34.

11. Kelly RE, Koff HD, Rothaus KO, Carter DM, Artusio JF Jr. Brachial plexus anesthesia in eight patients with recessive dystrophic epidermolysis bullosa. *Anesth Analg* 1987; 66(12):1318-20.
12. James I, Wark H. Airway management during anesthesia in patients with epidermolysis bullosa dystrophica. *Anesthesiology* 1982;56(4): 323-6.
13. Saraf SV, Mandawade NJ, Gore SK, Padhye UD, Pereira CS. Epidermolysis bullosa: careful monitoring and no touch principle for anesthesia management. *J Anaesthesiol Clin Pharmacol* 2013;29(3):390-3.
14. Canbay Ö, Özgen S. [Anesthesia in plastic surgery]. Keçik Y, Alkış N, Yörükoğlu D, Ayanoğlu Z, editörler. *Temel Anestezi*. 2. Baskı. Ankara: Güneş Tıp kitabevi; 2016. p.755-56.