

Cyst Hydatid Causing Sinistral Portal Hypertension and Massive Gastric Variceal Hemorrhage: Case Report

Kist Hidatiğe Bağlı Sinistral Portal Hipertansiyon ve Masif Gastrik Varisyal Kanama

Burhan ÖZDİL, MD,^a
Hikmet AKKIZ, MD,^a
Macit SANDIKÇI, MD,^a
Haluk DEMİRÜREK, MD^b

Departments of
^aGastroenterology,
^bGeneral Surgery,
Çukurova University Faculty of Medicine,
Adana

Geliş Tarihi/Received: 16.09.2008
Kabul Tarihi/Accepted: 12.03.2009

Yazışma Adresi/Correspondence:
Burhan ÖZDİL, MD
Çukurova University Faculty of Medicine,
Department of Gastroenterology, Adana,
TÜRKİYE/TURKEY
burhanozdil@gmail.com

ABSTRACT The case with portal hypertension and variceal hemorrhage due to cyst hydatid mass at the splenic hilum was reported. Endoscopic examination revealed isolated gastric varices type I. Abdominal ultrasonography showed a 5-cm diameter cystic mass between the tail of the pancreas and the hilar region of the spleen. The cyst was compressing the hilar vessels which resulted in dilatation and variceal formation. The indirect haemagglutination test for hydatid cyst was positive. The patient underwent laparotomy since medical therapy failed to control active bleeding. Peroperatively, splenic vein pressure was found as high but portal vein pressure was in the normal ranges. The liver appearance was normal. Splenectomy and cyst excision were performed. Postoperative endoscopy showed disappearance of the gastric varices. No rebleeding was observed in the recovery period. Considering this case, it must be noticed that hydatid cysts can proceed with atypic findings and cause sinistral portal hypertension with notably severe complications.

Key Words: Echinococcosis, hepatic; esophageal and gastric varices; hypertension, portal; hematemesis, echinococcosis

ÖZET Splenik hilustaki kist hidatik kitlesi nedeniyle oluşan portal hipertansiyon ve varis kanamalı vaka rapor edildi. Endoskopide izole tip I gastrik varis izlendi. Abdominal ultrasonografide dalak hilus bölgesi ile pankreas kuyruğu arasında 5 cm çapında kistik kitle saptandı. Kist, hilus damarlarında dilatasyon ve varis oluşumu ile sonuçlanan baskı oluşturuyordu. Kist hidatik indirekt hemagglütinasyon testi pozitif idi. Aktif kanama kontrolünde medikal tedavi başarısız olduğu için hastaya laparotomi uygulandı. Peroperatif ölçülen splenik ven basıncı yüksekti fakat portal ven basıncı normal sınırlarda idi. Karaciğer görünümü normaldi. Hastaya splenektomi ve kist eksizyonu uygulandı. Postoperatif endoskopide gastrik varislerde kaybolma izlendi. İyileşme döneminde tekrar kanama gözlenmedi. Bu vaka dolayısıyla kist hidatiğin atipik bulgularla seyredebileceği ve sinistral portal hipertansiyona neden olup oldukça ciddi komplikasyonlara yol açabileceğine dikkat edilmelidir.

Anahtar Kelimeler: Hepatik ekinokokkus; özefageal ve gastrik varis; portal hipertansiyon; hematemesis, ekinokokus

Türkiye Klinikleri J Gastroenterohepatol 2010;17(1):40-3

Splenic vein pathologies are important causes of extrahepatic portal hypertension which accounts for 5-10% of all portal hypertension cases.^{1,2} This kind of portal hypertension is described by various terms in the literature, as sinistral, segmental, left-sided, regional, lineal and spleno-portal hypertension.³⁻⁷ Although sinistral portal hypertension is a rare clinical condition, it is the most common cause of isolated gastric varices. It can cause massive gastric variceal hemorrhage due to deteriorated splenic

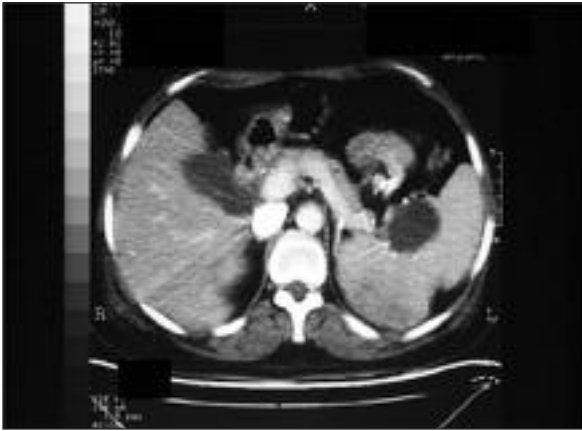

FIGURE 1: The cystic lesion (arrow) located in splenic hilus observed in abdominal tomography.

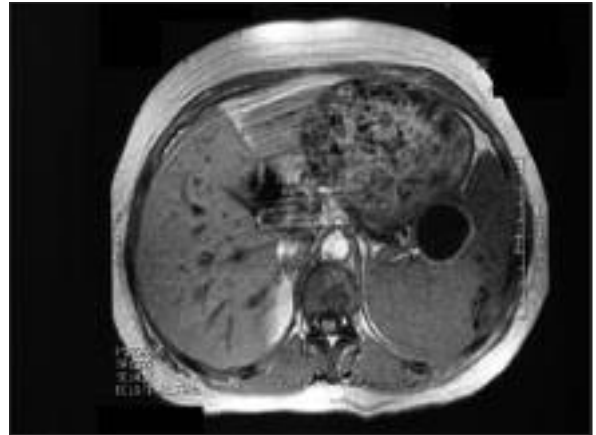


FIGURE 2: The appearance of the lesion located in splenic hilus in abdominal MR, The Cyst is observed as thick-walled (arrow).

venous flow by pancreatiko-hilar pathologies.⁸ The splenic vein is susceptible for lesions of pancreas, splenic flexura or splenic hilus due to its close anatomical location. Any obstruction, blockage or compression of splenic vein due to pancreatitis, pancreatic pseudocysts and benign or malign pancreatic neoplasms, can lead to sinistral portal hypertension.⁹ Hydatid masses are unusual causes of splenic vein obstruction.¹⁰ They can cause back pressure changes in the left portal system secondary to external compression by mass effect. On Current management approach usually needs surgery for treating the underlying pathology. In the presence of major gastrointestinal hemorrhage and subsequent blood transfusions, splenectomy is the appropriate choice for decompressing the left-sided portal hypertension.¹¹ We report a case with hyda-

tid cyst located at splenic hilus which caused left-sided portal hypertension with a patent portal vein and normal hepatic function and abundant gastrointestinal tract hemorrhage.

CASE REPORT

The 38-year-old woman was referred to our clinic with recurrent upper gastrointestinal hemorrhage. The patient was treated with blood transfusion more than 20 units for last three months. She was investigated based on this medical history of cirrhosis. Her laboratory test results were; prothrombin time: 12.7 sec, INR: 1, thrombocyte count: 306 000/mm³, AST: 63 U/L, ALT: 96 U/L, ALP: 192 U/L, GGT: 12 U/L, total bilirubin: 0.6 mg/dl, direct bilirubin: 0,1 mg/dl, total protein: 6 gr/dl, albumin: 3 gr/dl. Hepatitis markers, HBsAg (-), anti

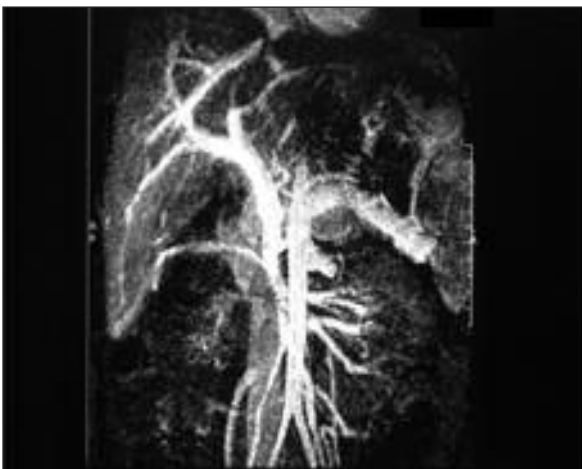


FIGURE 3: Abdominal MR show a mild compression signs on splenic vein.

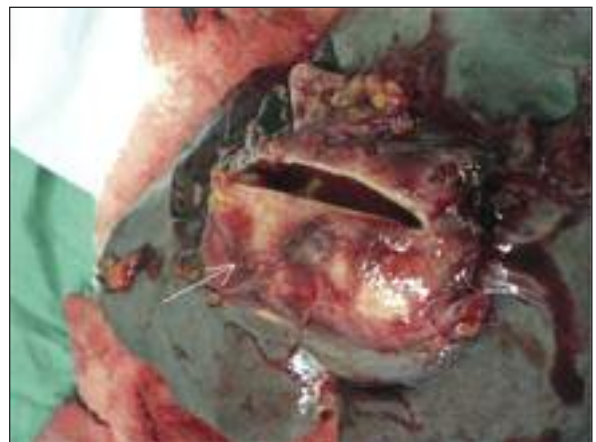

FIGURE 4: After the spleen was resected with the cyst, the thick-walled structure of the cyst (arrow).

Hbs (-), AntHbe(-), HbeAg(-), antiHCV(-). In abdominal ultrasonography (USG), the liver was heterogeneous. The portal vein was measured as 15 mm and the spleen was 137 mm. A cystic lesion with dimensions of 52x31 mm located at splenic hilus was observed. Cyst hydatid indirect hemagglutination test was positive (1/1280 titer). Abdominal tomography revealed changes secondary to chronic liver disease and a subcapsular cystic lesion in splenic hilus (Figure 1, 2). Abdominal MR angiography revealed a mild compression on splenic vein. (Figure 3, 4) In endoscopic examination, isolated fundal varices were detected. Liver biopsy was performed and macronodular cirrhosis was detected. Endoscopic cyanoacrylate injection was administered for gastric variceal hemorrhage. Transjugular intrahepatic portosystemic shunt (TIPS) was performed since bleeding couldn't be controlled. Because the TIPS procedure technically failed, laparotomy performed. In surgical exploration, the liver was observed in normal appearance. Portal venous pressure was measured and found as normal limits. A cystic lesion was detected at the splenic hilus which compressed the splenic vein considerably. The spleen was resected with the cystic hilar lesion (Figure 4). The wall of the cyst was thick, and daughter vesicles and germinative membrane were identified. It was confirmed as hydatid disease by histopathologic examination. Postoperative recovery was uneventful and rehemorrhage did not occur. The control endoscopy showed disappearance of the gastric varices.

DISCUSSION

Chronic liver disease is the main cause of the portal hypertension. Increased resistance to portal blood flow through a cirrhotic liver initiates the development of portal hypertension. Portal hypertension may develop secondary to many different etiologies.¹² Less common causes of extrahepatic portal hypertension have been reported such as; cyst, tumor, abscess, venous compression secondary to aneurysm, tumor infiltration, chronic pancreatitis, thrombosis and congenital anomalies.¹³⁻¹⁵ Developments of gastric varices are commonly seen in left-sided portal hypertension. Treatment is rel-

atively difficult and gastric varices can be a cause of serious bleeding, as in our case, bleeding can be difficult to manage.¹⁶

Percutaneous USG guided liver biopsy was performed to our patient to verify a suspicion of cirrhosis and it was diagnosed as macronodular cirrhosis histopathologically. The normal macroscopic appearance of the liver at laparotomy was the main suspicion of the histopathologic misdiagnosis of cirrhosis. The ratio of making diagnosis of cirrhosis with microscopy in normal macroscopic liver is less common entity (0.8%).¹⁷ Furthermore the false positivity chance of these single liver biopsies are considerably high (10-30%) and these defects are seen in macronodular cirrhotic patients especially.¹⁸ In our case, it was found to be interesting that the hydatid cyst located at the splenic hilus was presented with a serious gastrointestinal tract hemorrhage. Although case series of sinistral portal hypertension due to different etiologies have been found in the literature; hydatid cyst is very rarely reported as a cause.^{19,20} This compression causes backpressure in the left portal venous system and subsequent gastric varices. Gastrointestinal tract hemorrhage in the patient was quite massive, constituting a serious mortality risk. Cyanoacrylate injection showed no efficacy in this case, although it provides positive results in cases of gastric varices secondary to different etiologies.^{21,22} In cases of left-sided portal hypertension, splenomegaly is one of the findings identified as well as gastric varices. In the literature, occurrence rate of splenomegaly is reported to be 42-71%.^{23,24} Splenomegaly was present in our case. Management of this condition is usually surgical to treat the underlying primary pathology if possible, combined with splenectomy to decompress the left portal venous system. TIPS is a safe and effective treatment for bleeding esophageal and gastric varices.^{25,26} In our case, this procedure could not be performed. Because portal venous pressure was in normal ranges and portal hypertension was left-sided (sinistral portal hypertension) due to compression of the cyst. In such cases, it is very important to determine the etiology exactly and plan the treatment accordingly. In this case if percutaneous treatment of the cyst could be

done before splenic venous pressure reached to a critical level, surgery might not be required.

CONCLUSION

We present a patient with upper gastrointestinal bleeding due to portal hypertension caused by the involvement and compression of the splenic hilus with a cystic mass. Hydatid cysts or benign cysts

which tend to grow, can compress other organs like vein or arteria and subsequently can be presented with serious complications. Therefore, their percutaneous treatment in early period is important. In the evaluation of patients with isolated gastric varice type I, extrinsic compressions due to a cyst or a mass should be taken into consideration as well as pancreatic cancers and splenic venous thrombosis.

REFERENCES

- Hamilton DW, Hunt AH. Extrahepatic portal obstruction. *Med J Aust* 1970;1(10):493-9.
- Novis BH, Duys P, Barbezat GO, Clain J, Bank S, Terblanche J. Fiberoptic endoscopy and the use of the Sengstaken tube in acute gastrointestinal haemorrhage in patients with portal hypertension and varices. *Gut* 1976;17(4):258-63.
- Sutton JP, Yarborough DY, Richards JT. Isolated splenic vein occlusion. Review of literature and report of an additional case. *Arch Surg* 1970;100(5):623-6.
- Turrill FL, Mikkelsen WP. "Sinistral" (left-sided) extrahepatic portal hypertension. *Arch Surg* 1969;99(3):365-8.
- Lavender S, Lloyd-Davies RW, Thomas ML. Retroperitoneal fibrosis causing localized portal hypertension. *Br Med J* 1970;3(5723):627-8.
- Salam AA, Warren WD, Tyras DH. Splenic vein thrombosis: a diagnosable and curable form of portal hypertension. *Surgery* 1973;74(6):961-72.
- Rasch W. Isolated gastric varices: a hint of pancreatic disorders. *Endoscopy* 1974;6(4):217-20.
- Madsen MS, Petersen TH, Sommer H. Segmental portal hypertension. *Ann Surg* 1986;204(1):72-7.
- Evans GR, Yellin AE, Weaver FA, Stain SC. Sinistral (left-sided) portal hypertension. *Am Surg* 1990;56(12):758-63.
- Klomp maker IJ, Haagsma EB, Slooff MJ. Splenic vein obstruction due to a solitary echinococcal splenic cyst, resulting in gastric fundus varices: an unusual cause of variceal bleeding. *HPB Surg* 1993;6(3):229-32.
- Babb RR. Editorial: Splenic vein obstruction: a curable cause of variceal bleeding. *Am J Dig Dis* 1976;21(6):512-3.
- Friedman LS, Sleisenger MH. Portal hypertension and gastrointestinal bleeding. In: Klein S, ed. *Sleisenger and Fordtran's Gastrointestinal and Liver Disease*. Volume 2. 6th ed. Philadelphia: Saunders; 1998. p.1285-7.
- Bok EJ, Cho KJ, Williams DM, Brady TM, Weiss CA, Forrest ME. Venous involvement in islet cell tumors of the pancreas. *AJR Am J Roentgenol* 1984;142(2):319-22.
- Hamano K, Hiraoka H, Kouchi Y, Fujioka K, Esato K. Klippel-Trenaunay syndrome associated with splenomegaly: report of a case. *Surg Today* 1995;25(3):272-4.
- Ben-Ari G, Mitty H, Kark AE, Rudick J. Segmental portal hypertension due to congenital cavernous malformation of splenic vein. *Mt Sinai J Med* 1972;39(3):271-8.
- Sarin SK, Lahoti D, Saxena SP, Murthy NS, Makwana UK. Prevalence, classification and natural history of gastric varices: a long-term follow-up study in 568 portal hypertension patients. *Hepatology* 1992;16(6):1343-9.
- Poniachik J, Bernstein DE, Reddy KR, Jeffers LJ, Coelho-Little ME, Civantos F, et al. The role of laparoscopy in the diagnosis of cirrhosis. *Gastrointest Endosc* 1996;43(6):568-71.
- Afdhal NH, Nunes D. Evaluation of liver fibrosis: a concise review. *Am J Gastroenterol* 2004;99(6):1160-74.
- El Fortia M, Bendaoud M, Taema S, Bahei El Din I, Ben Musa A, Shaban A, et al. Segmental portal hypertension due to a splenic Echinococcus cyst. *Eur J Ultrasound* 2000;11(1):21-3.
- Thompson RJ, Taylor MA, McKie LD, Diamond T. Sinistral portal hypertension. *Ulster Med J* 2006;75(3):175-7.
- Akahoshi T, Hashizume M, Shimabukuro R, Tanoue K, Tomikawa M, Okita K, et al. Long-term results of endoscopic Histoacryl injection sclerotherapy for gastric variceal bleeding: a 10-year experience. *Surgery* 2002;131(1 Suppl):S176-81.
- Rengstorff DS, Binmoeller KF. A pilot study of 2-octyl cyanoacrylate injection for treatment of gastric fundal varices in humans. *Gastrointest Endosc* 2004;59(4):553-8.
- Muhletaler C, Gerlock AJ Jr, Goncharenko V, Avant GR, Flexner JM. Gastric varices secondary to splenic vein occlusion: radiographic diagnosis and clinical significance. *Radiology* 1979;132(3):593-8.
- Røder OC. Splenic vein thrombosis with bleeding gastroesophageal varices. Reports of two splenectomized cases and review of the literature. *Acta Chir Scand* 1984;150(3):265-8.
- Shiffman ML, Jeffers L, Hoofnagle JH, Tralka TS. The role of transjugular intrahepatic portosystemic shunt for treatment of portal hypertension and its complications: a conference sponsored by the National Digestive Diseases Advisory Board. *Hepatology* 1995;22(5):1591-7.
- Özakyol AH. [Treatment options in variceal upper gastrointestinal bleeding]. *Turkiye Klinikleri J Surg Med Sci* 2006;2(15):14-20.