

The Association of Rothmund Thomson Syndrome and Cystic Fibrosis: Case Report

Rothmund Thomson Sendromu ve Kistik Fibrozisin Birlikteliği

Aysun ŞİKAR AKTÜRK, MD,^a
Rebiay KIRAN, MD,^a
Metin AYDOĞAN, MD,^b
Cengiz ERÇİN, MD,^c
Emin Sami ARISOY, MD^b

Departments of ^aDermatology,
^bPediatrics, ^cPathology,
Kocaeli University Faculty of Medicine,
KOCAELİ

Geliş Tarihi/Received: 21.12.2006
Kabul Tarihi/Accepted: 03.04.2007

Yazışma Adresi/Correspondence:
Aysun ŞİKAR AKTÜRK, MD,
Kocaeli University Faculty of Medicine
Department of Dermatology
aysun9442@ekolay.net

ABSTRACT Rothmund Thomson Syndrome (RTS) is a rare autosomal recessive genophotodermatosis with heterogeneous clinical profile. It is characterized poikiloderma, growth retardation, congenital bone defects, brittle hair, hipogonadizm and alopecia. Cystic fibrosis (CF) is a common genetic disease which leads premature respiratory failure. Airway abnormalities have been reported in patients with RTS. The association of RTS and CF has been initially described. Here, we report a four-year old boy with RTS and CF.

Key Words: Rothmund-Thomson syndrome; cystic fibrosis

ÖZET Rothmund Thomson sendromu (RTS) farklı klinik özellikleri olan nadir otozomal resesif bir genofotodermatozdur. Alopesi, kırılğan saç, hipogonadizm, büyüme geriliği, konjenital kemik defektleri ve poikiloderma ile karakterizedir. Kistik fibroz (KF) erken dönemde solunum yetmezliğine yol açan yaygın genetik bir hastalıktır. RTS'li hastalarda hava yolu anomalileri bildirilmiştir, RTS ve KF birlikteliği bir kere tanımlanmıştır. Burada, RTS ve KF'li 4 yaşında bir erkek çocuk olgu sunuyoruz.

Anahtar Kelimeler: Rothmund Thomson sendromu; kistik fibroz

Türkiye Klinikleri J Dermatol 2008, 18:134-137

Rothmund Thomson Syndrome (RTS) is a rare autosomal recessive genophotodermatosis which has heterogeneous clinical profile and radiological manifestations.¹⁻⁶ RTS is characterized primarily a sun sensitive rash that usually begins between the first 3 and 6 months of life. At acute phase, the rash begins as erythema, swelling and blistering especially on the cheeks and face. Then it spreads to the buttocks, the flexural areas of extremities, chest, back and abdomen. After the active phase which lasts about a few months to several years, the characteristic appearance of poikiloderma (reticulated pigmentation, telangiectasies and areas of punctuate dermal atrophy) develops on the affected areas and can persists throughout life.^{2,5,7} Premalignant warty keratoses may develop during the progress of the disease.⁷ Additionally, growth retardation, congenital bone defects, brittle hair, hypogonadizm, alopecia, dystrophic teeth and nails, juvenile cataract, anemia and high incidence of cutaneous and noncutaneous malignancies can be seen.¹⁻¹⁰ Cystic fibrosis (CF) is the most common genetic disease, inherited by autosomal recessive trait, within the Caucasian po-

pulation which is resulted in premature respiratory failure.¹¹ It is characterized chiefly by obstruction and infection of airway and by maldigestion and its consequences. CF is the major cause of severe chronic lung disease in children and is responsible for most exocrine pancreatic insufficiency during early life. The other features of CF are failure to thrive, abnormal stools, intestinal obstruction, electrolyte and acid-base abnormality, vitamin deficiency states, acrodermatitis-like rash, edema and the existence of family history.¹² The association of CF with albinism¹³ and eczema¹⁴ has also been reported. Airway abnormalities may be found in patients with RTS.¹ To the best of our knowledge, the association of CF and RTS has been initially described by Lewis in 1972¹⁵ Herein, we report a four-year-old boy with RTS and CF.

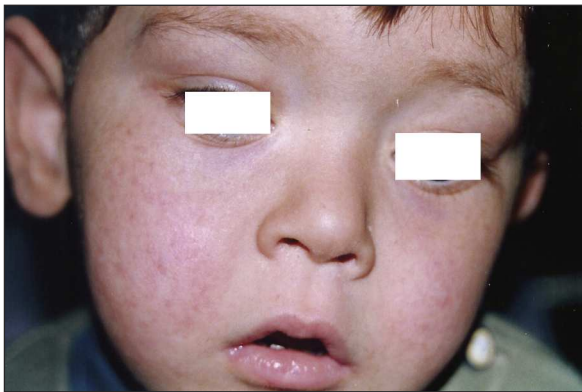

FIGURE 1: Poikilodermatous changes of the cheeks at two years old.

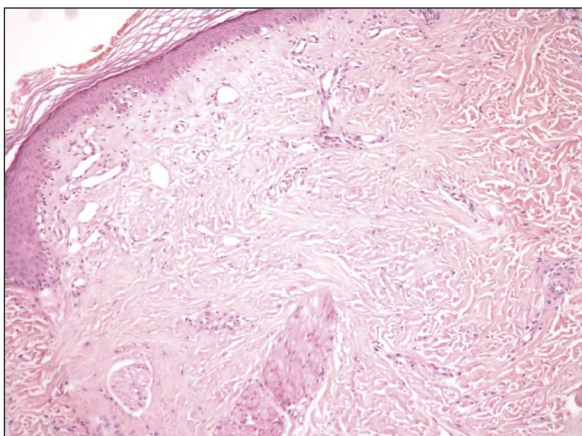


FIGURE 2: Lamellar hyperkeratosis, epidermal atrophy, hydropic degeneration of the basal cell layer, telangiectatic vascular proliferation in superficial and deep dermis, increased and homogenization of collagen fibers in dermis (HE x100).

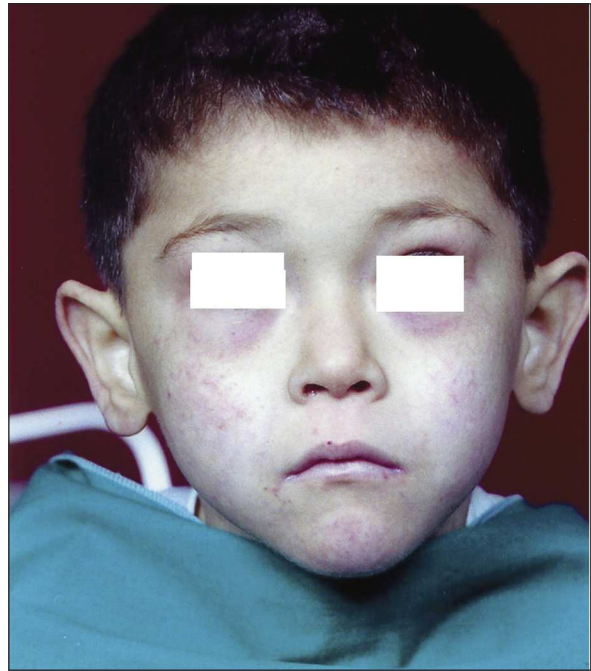

FIGURE 3: Poikilodermic appearance on the cheeks at four-years old.

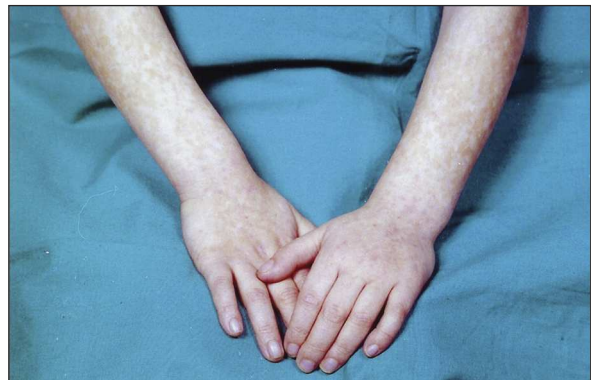


FIGURE 4: Poikilodermic appearance on the forearms and cudgel fingers at four-years old.

CASE REPORT

A 2 year-old boy presented with generalized discolorations and erythema. The clinical onset of lesions was about 6 months of age. He had a history of recurrent respiratory tract infections beginning early in infancy. He was delivered at full term with no complication throughout the pregnancy. He was the third child of the family and his siblings had normal physical and dermatological examination.

Physical examination revealed hepatomegaly and expiratory rhoncus. The patient was well be-

low the 25th percentile for weight and length and at the 50th percentile for head circumference. On laryngeal examination, laryngeal adhesions were detected. He had normal intelligence. Other physical findings were unremarkable. Dermatological examination revealed erythema on the cheeks (Figure 1) and dorsal aspects of the hands. In addition to hyperpigmentation, erythematous papules and atrophy on extensor aspects of arms, forearms, trunk and the legs, subungual hyperkeratosis was found on the both first toe nails. Hematological and biochemical tests were normal except elevated ESR (65 mm/hr) and an abnormal sweat test (Na^+ 104 mmol/L). Immunoglobulin (IgG, IgM, IgA, IgE) and hormone (fT3, fT4, TSH) levels were within normal limits. Direct mycological examination and mycological cultures of first toe nails were negative. Radiological examination showed widespread infiltration at the right lung and normal appearance of bones. Histopathological examination of skin lesions on the distal limb showed lamellar hyperkeratosis, epidermal atrophy, hydropic degeneration of the basal cell layer, telangiectatic vascular proliferation in superficial and deep dermis, increase and homogenization of collagen fibers (Figure 2). Chromosomal analysis could not be performed in our case due to technical insufficiencies. RTS and CF were diagnosed based on clinical, laboratory and histopathological findings. Sunscreen cream was suggested for UV-protection. After 2 years-follow up period, characteristic appearance of poikiloderma on the affected areas especially on the cheeks and hyperkeratotic papules particularly on the extensor surfaces of the extremities and cudgel fingers have been detected (Figure 3, 4).

DISCUSSION

Chromosomal anomalies, ultraviolet-A (UVA) induced DNA damage and abnormal repair processes, lymphocyte and fibroblast radio sensitivity, growth hormone deficiency,^{2,4} a defect in connective tissue metabolism are suggested from the mechanism which is responsible for the increase of carcinogenesis and photosensitivity in RTS.² As in our case the location of lesions especially on photo-exposed areas supports the role of UV in the etiology of RTS.

The diagnosis of RTS is made currently on clinical findings since diagnostic laboratory test for RTS is unavailable. Skin biopsy may show poikiloderma. Molecular tests may be useful in confirming the diagnosis.⁵ Mutational heterogeneity and environmental factors appear to be responsible for highly variable involvement of the lung, pancreas and other organs in CF.¹² In our case, there was poikilodermic appearance on predominantly photo-exposed areas in addition to recurrent respiratory tract infections from his early infancy and laryngeal adhesions that may be developed due to both RTS and CF presence. Histological examination of a skin biopsy showed poikilodermatous skin reaction pattern. He had no clinical and laboratory findings of other congenital poikiloderma such as ataxia telangiectasia, Fanconi's anaemia and Bloom's syndrome.

RTS is an autosomal recessive skin disorder.^{1,2,3,7} and genetic defect is mutations in the RECQL4 gene (human DNA helicase gene) of chromosome 8.^{3,5-7} Hallman and Patiala also described autosomal dominant inheritance in a patient.² Sex linked inheritance was not reported and spontaneous mutation was accused for RTS.² It has been reported patients with RTS who have abnormalities including trisomy 7 and trisomy 8.⁵

CF is inherited as an autosomal recessive trait. Skin symptoms in CF are rare. But, the association of CF with albinism, eczema and acrodermatitis enteropatica-like eruption has also been reported.¹²⁻¹⁴ All of the more than 700 gene mutations that contribute to the cystic fibrosis syndrome occur at a single locus on the long arm of chromosome 7.¹² There was not family history of RTS and CF in our case.

Lewis reported the association of RTS and CF that was the first case in 1972. CF was called as a fibrocystic disease of the pancreas in this literature.¹⁵

In our case which is the second report in the literature, although chromosome analyses were not able to perform due to technical insufficiencies, we think that this association might be either due to a mutation in both chromosome 7 and 8 or due to coincidence.

REFERENCES

1. Hafidh MA, Sheahan P, Russell JD. Multiple airway abnormalities in a patient with Rothmund-Thomson syndrome. *Int J Pediatr Otorhinolaryngol* 2004;68:469-72.
2. Vennos EM, Collins M, James WD. Rothmund-Thomson syndrome: review of the world literature. *J Am Acad Dermatol* 1992;27:750-62.
3. Piquero-Casals J, Okubo AY, Nico MM. Rothmund-thomson syndrome in three siblings and development of cutaneous squamous cell carcinoma. *Pediatr Dermatol* 2002;19:312-6.
4. Clark C, Ferguson J. Photosensitivity and the Rothmund-Thomson syndrome. *Br J Dermatol* 1998;139:1113-5.
5. Wang LL, Levy ML, Lewis RA, Chintagumpala MM, Lev D, Rogers M, Plon SE. Clinical manifestations in a cohort of 41 Rothmund-Thomson syndrome patients. *Am J Med Genet* 2001;102:11-7.
6. Gelaw B, Ali S, Becker J. Rothmund-Thomson syndrome, Klippel-Feil syndrome, and osteosarcoma. *Skeletal Radiol* 2004;33:613-5.
7. Dahele MR, Benton EC, Hennessy A, MacDougall RH, Price A, Mitchell R, et al. A patient with Rothmund-Thomson syndrome and tongue cancer--experience of radiation toxicity. *Clin Oncol (R Coll Radiol)* 2004;16:371-2.
8. Ogunbiyi AO, Ogunbiyi JO, Baiyeroju-Agbeja AM. Congenital poikiloderma with unusual hypopigmentation and acral blistering at birth. *J Eur Acad Dermatol Venereol* 1999;12:54-8.
9. Shinya A, Nishigori C, Moriwaki S, Takebe H, Kubota M, Ogino A, et al. A case of Rothmund-Thomson syndrome with reduced DNA repair capacity. *Arch Dermatol* 1993;129:332-6.
10. Balraj P, Concannon P, Jamal R, Beghini A, Hoe TS, Khoo AS, et al. An unusual mutation in RECQ4 gene leading to Rothmund-Thomson syndrome. *Mutat Res* 2002;508:99-105.
11. Aris RM, Merkel PA, Bachrach LK, Borowitz DS, Boyle MP, Elkin SL, et al. Guide to bone health and disease in cystic fibrosis. *J Clin Endocrinol Metab* 2005;90:1888-96.
12. Boat TF. Cystic fibrosis. In: Behrman RE, Kliegman RM, Jenson HB, eds. *Nelson Textbook of Pediatrics*. 16th ed. Philadelphia: WB Saunders, 2000. p.1315-28.
13. Pruszewicz A, Sokolowski Z, Goncarzewicz A. Mucoviscidosis coexisting with generalized albinism. *Otolaryngol Pol* 1978;32:93-5.
14. Brand PL, Gerritsen J, van Aalderen WM. A baby with eczema and an abnormal sweat test. *Lancet* 1996;348:932.
15. Lewis MB. Rothmund-Thompson syndrome and fibrocystic disease. *Australas J Dermatol* 1972;13:105-6.