

A Case of Tuberculosis Verrucosa Cutis, Misdiagnosed and Treated as a Wart

Siğil Tanısı Konarak Tedavi Edilen Bir Tüberkülozis Verrükoza Kutis Olgusu

Serap UTAŞ, MD, Prof.,^a
Ebru GÜLER, MD, Msc,^a
Serpil POSTGİL YILMAZ, MD, Msc^b

^aDepartment of Dermatology,
Erciyes University Faculty of Medicine,
^bUyum Pathology & Cytology Center,
Kayseri

Geliş Tarihi/Received: 15.02.2010
Kabul Tarihi/Accepted: 06.08.2010

Yazışma Adresi/Correspondence:
Ebru GÜLER, MD, Msc
Erciyes University Faculty of Medicine,
Department of Dermatology,
Kayseri,
TÜRKİYE/TURKEY
drebruguler@hotmail.com

ABSTRACT Tuberculosis is still among the major community health problems worldwide. The clinical diversity of cutaneous tuberculosis depends on the route of acquisition of infection and on the patient's immune system. Tuberculosis verrucosa cutis (TVC) results from an exogenous inoculation of *Mycobacterium tuberculosis*, at sites prone to trauma. The lesion begins as a small, asymptomatic, indurated wart-like papule with a subtle inflammatory rim. It gradually enlarges in a serpiginous manner to form a firm reddish-brown verrucous plaque. The center of the lesion can become fluctuant and pus and keratinaceous debris may be expressed by slight pressure. We presented a case of TVC, which was misdiagnosed as verruca vulgaris and had received prior treatments including topical salicylic acid, topical 5-fluorouracil, and several successive cryotherapy and cautery sessions.

Key Words: Tuberculosis, cutaneous; warts

ÖZET Tüberküloz halen dünya üzerinde en önemli halk sağlığı sorunu olmaya devam etmektedir. Kutanöz tüberkülozun klinik tablosunda farklılık, enfeksiyonun vücuda giriş yeri ve hastanın immün sisteminin yapısına bağlı olarak ortaya çıkmaktadır. Tüberkülozis verrükoza kutis (TVK), travmaya sık maruz kalan bölgelerde *Mycobacterium tuberculosis*'in inokülasyonu sonucu ortaya çıkmaktadır. Lezyon, çevresinde hafif belirginlikte bir inflamasyon halkası olan küçük, asemptomatik, endürasyonlu, siğil benzeri bir papül olarak ortaya çıkmaktadır. Daha sonra lezyon serpiginöz tarzda büyüyerek sert kırmızımsı kahverengi verüköz bir plak halini almaktadır. Lezyonun merkezi fluktuasyon gösterebilir ve hafif basmakla püy ve keratinöz akıntı gelebilir. Bu makalede, daha önceden yanlışlıkla verrüka vulgaris tanısı almış, topikal salisilik asit, topikal 5-fluorourasil ile tedavi edilmiş ve birkaç kez koter ve kriyoterapi uygulanmış bir TVK olgusu sunulmuştur.

Anahtar Kelimeler: Tüberküloz, deri; siğiller

Türkiye Klinikleri J Med Sci 2012;32(3):822-6

Cutaneous tuberculosis may manifest as either primary (previously uninfected/non-sensitized host) or secondary (presensitized host) forms. It was classified by Beyt et al. into a clinically relevant scheme consisting of four categories depending on whether the skin lesion arises from an exogenous, endogenous or haematogenous source or whether it is a tuberculid.¹ TVC is a paucibacillary form of cutaneous tuberculosis caused by exogenous re-infection in previously sensitized individuals. Inoculation occurs at sites of minor wounds or abrasions. We presented a case of TVC, which was misdiagnosed as verruca vulgaris and had received prior treat-

ments including topical salicylic acid, topical 5-fluorouracil, and several successive cryotherapy and cauterization sessions.

CASE REPORT

A 40-year-old female patient with a poor socioeconomic status presented with an 18-month history of slowly enlarging painless, firm, warty nodule bordered with a purple halo on the dorsal aspect of her right hand. She stated that the lesion had continued to enlarge to a warty plaque with fissures despite topical salicylic acid, topical 5-fluorouracil and several courses of liquid nitrogen cryotherapy and cauterization. Pus has been discharged from the lesion from time to time.

She declared that she has been milking. Although the patient could not remember sustaining any injury, she noticed a painless small papule on her right hand 18 months ago. Her medical history was not significant, and she did not have current or past history of weight loss, cough, expectoration or fever. There was no personal or family history of tuberculosis.

The lesion was located on the second metacarpophalangeal area and was measured 2.5x2.0 cm. The well-circumscribed verrucous plaque with a rough surface and fissures was bordered with a thin, purple halo. The upper side of the lesion resembled a cauliflower including pinpoint crusts and little squams. The lesion before and after treatment were shown on the Figure 1a and 1b. There was no regional or generalized lymphadenopathy. The patient had received Bacillus Calmette-Guérin (BCG) vaccination in childhood and a BCG scar was identified on her left deltoid area. Systemic examination did not reveal any abnormalities. Complete blood count, erythrocyte sedimentation rate, and renal and liver function tests were normal. A Mantoux test with intradermal injection of 0,1 mL purified protein derivative (PPD) revealed a strong positive reading of 30 mm after 72 h (Figure 2). Chest X-Ray and computerized tomography scan were normal.

We performed a skin biopsy of the lesion. TVC, chromoblastomycosis and verruca vulgaris were considered in the differential diagnosis.

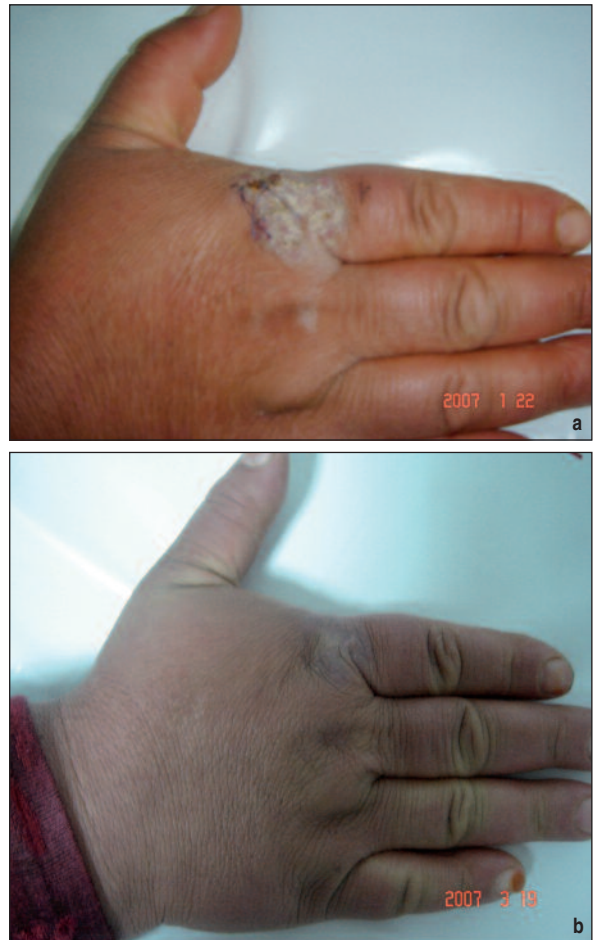

FIGURE 1: a. Before treatment: A well circumscribed plaque with irregular surface on dorsum of the right hand.

b. Complete improvement with hyperpigmentation after 2 months of antituberculosis treatment.

(See for colored form <http://tipbilimleri.turkiyeklinikleri.com/>)

Haematoxylin-eosin-stained sections of the biopsy specimen revealed hyperkeratosis, acanthosis and papillomatosis. There was an acute inflammatory infiltrate beneath the epidermis, abscess formation in the upper dermis and within the downward extensions of the epidermis. The histology showed features of an epithelioid cell granuloma with a moderate amount of necrosis, numerous aggregates of histiocytes and lymphocytes, and Langhans' type giant cells in the middermis (Figure 3a, b). There were neither acid-fast bacilli nor spores with Fites' stain. Erlich-Ziehl-Nielsen staining and culture of skin biopsies were negative for *Mycobacterium tuberculosis* and atypical mycobacteria. The clinical, laboratory and histological features of the lesion suggested a case of TVC. In our case, the causative

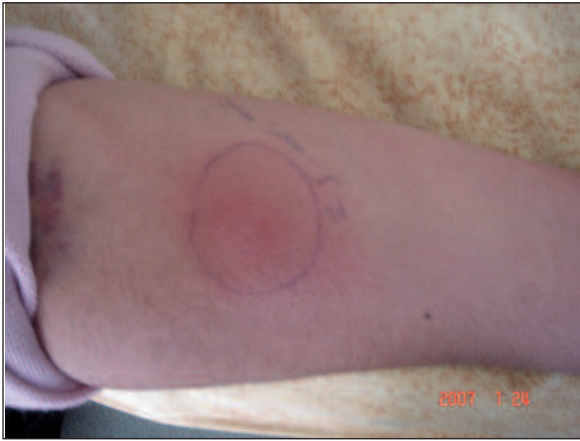

FIGURE 2: A strong positive Mantoux test with intradermal injection of 0.1 mL purified protein derivative after 72 hours.

(See for colored form <http://tipbilimleri.turkiyeklinikleri.com/>)

agent was most likely *Mycobacterium bovis* considering the patient's contact with an infected cow.

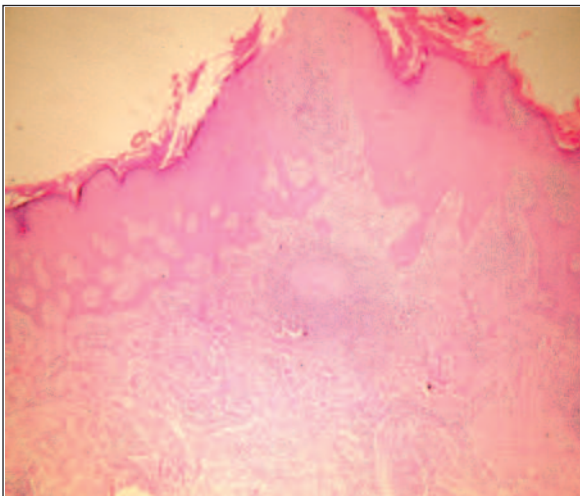
Antituberculosis therapy was initiated with rifampicin 600 mg, isonicotinic acid hydrazide 300 mg, ethambutol 1500 mg and pyrazinamide 1500 mg daily for 2 months. After a two-month-treatment period, the lesion healed leaving only a slight hyperpigmentation in a small area. The patient was advised to continue the treatment in which rifampicin and isonicotinic acid hydrazide were to be continued for another 4 months.

DISCUSSION

The clinical diversity of cutaneous tuberculosis depends on the route of acquisition of the infection and on the patient's immune system. The species is usually *Mycobacterium tuberculosis hominis*; although rare, *Mycobacterium bovis* and *Mycobacterium avium* may also be causative agents. It is also known as prosector's wart, verruca necrogenica, anatomic tubercle, lupus verrucosus and butchers' wart.²⁻⁴

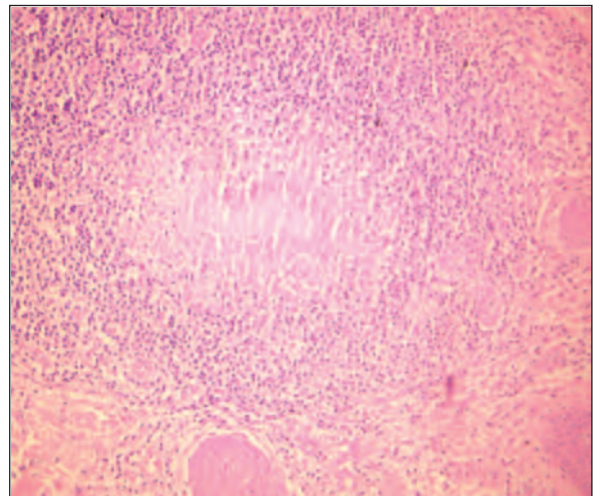
The most common locations for TVC are the dorsum of the hands, especially the fingers, as seen in our case. Those in direct contact with animals may experience inoculation at other sites, such as feet, beltline or chest. The initial lesion is a small, firm, red papule that slowly spreads over weeks and months and is surrounded by erythema. The overlying epidermis is often hyperkeratotic, resembling an inflamed wart.⁵ The chronic nature of TVC is well known. Progression of the lesion is slow, and if left untreated, persists for many years. However, only a few cases of lesions lasting for more than 20 years were reported previously.⁶

Because TVC occurs in patients who are immune to the tubercle bacillus, the Mantoux test is



a

FIGURE 3: a. Epidermal changes marked by hyperkeratosis, acanthosis, papillomatosis and there is an acute inflammatory infiltrate beneath the epidermis, abscess formation in the upper dermis and within the downward extensions of the epidermis. (Haematoxylin and eosin; original magnification X40).



b

b. The histology showed features of an epithelioid cell granulomas with a moderate amount of necrosis, numerous aggregates of histiocytes and lymphocytes, Langhans' type giant cells in the middermis (Haematoxylin and eosin; original magnification X200).

(See for colored form <http://tipbilimleri.turkiyeklinikleri.com/>)

usually positive as in our case. Staining and culture of skin lesions for acid-fast bacilli are usually negative.⁷ Although less than 1% of human tuberculosis is due to *Mycobacterium bovis*, this organism is the agent responsible for tuberculosis in cattle and was the most likely infectious agent in our patient.^{8,9}

TVC is rare in Turkey while scrofuloderma and lupus vulgaris are the most frequent forms of cutaneous tuberculosis.¹⁰ The incidence of TVC varies worldwide, with a higher frequency in Asia.^{11,12} In a 20-year prospective study, TVC corresponded to 6% of all cases of cutaneous tuberculosis.¹³

The optimal diagnosis of cutaneous tuberculosis relies on the demonstration of acid-fast bacilli in skin lesions, although culture provides only a small diagnostic yield in patients with this disease.¹⁴ The diagnosis is typically made presumptively based on the correlation of various criteria including the presence of active tuberculosis elsewhere, histopathologic findings, clinical history and physical signs, and a positive PPD skin test reaction. Therapeutic response to antituberculosis therapy can also be used as a diagnostic parameter.^{15,16} In vitro amplification of specific DNA sequences using polymerase chain reaction (PCR) has become a valuable tool in the diagnosis of various forms of cutaneous tuberculosis.¹⁷ The QuantiFERON(R)-TB Gold In-Tube test (QFN) measures interferon-gamma production in response to *Mycobacterium tuberculosis* antigens.¹⁸ Careful clinical and patho-

logical correlation is essential for the diagnosis of cutaneous tuberculosis.

The differential diagnosis includes other infections such as atypical mycobacteria, blastomycosis, sporotrichosis, chromomycosis, bromoderma, tertiary syphilis, verrucous carcinoma, cutaneous leishmaniasis and verruca, all of which are excluded by serologic, microbiologic and histological findings. Atypical mycobacteriosis (swimming pool granuloma), and deep mycosis (especially chromoblastomycosis) may prove to be more difficult to diagnose and usually require culture of the causative organism. Ordinary warts may show central clearing and peripheral spread after cryotherapy, but they are usually much less inflamed and more warty.⁵

The treatment of cutaneous tuberculosis is the same as pulmonary tuberculosis.¹⁹ Most patients today are treated with multidrug regimens. The usual initial treatment consists of four drugs: isoniazid, rifampicin, pyrazinamide and either ethambutol or streptomycin for 2 months, which is followed by a combination of isoniazid and rifampicine for 4 months. The treatment must last 6 months after complete resolution of the lesions.

In conclusion, TVC should be considered in the differential diagnosis of any chronic and resistant verrucous lesions resembling ordinary warts, in risk groups such as physicians, veterinarians, butchers and farmers.

REFERENCES

1. Beyt BE Jr, Ortbals DW, Santa Cruz DJ, Kobayashi GS, Eisen AZ, Medoff G. Cutaneous mycobacteriosis: analysis of 34 cases with a new classification of the disease. *Medicine (Baltimore)* 1981;60(2):95-109.
2. Tigoulet F, Fournier V, Caumes E. [Clinical forms of the cutaneous tuberculosis]. *Bull Soc Pathol Exot* 2003;96(5):362-7.
3. Sehgal VN, Wagh SA. The history of cutaneous tuberculosis. *Int J Dermatol* 1990;29(9):666-8.
4. Sehgal VN. Cutaneous tuberculosis. *Dermatol Clin* 1994;12(4):645-53.
5. Degitz K. Mycobacterial infections. In: Burgdorf WHC, Plewig G, Wolff HH, Landthaler M, eds. *Braun-Falco's Dermatology*. 3rd ed. Berlin: Springer Verlag; 2009. p.176-96.
6. Masellis P, Gasparini G, Caputo R, Alessi E. Tuberculosis verrucosa cutis which remained undiagnosed for forty-three years. *Dermatology* 1995;191(2):145-8.
7. Rieder HL. Tuberculosis verrucosa cutis: clinical picture and response to short-course chemotherapy. *J Am Acad Dermatol* 1988;18(6):1367-9.
8. Allix-Béguec C, Fauville-Dufaux M, Stoffels K, Ommeslag D, Walravens K, Saegerman C, et al. Importance of identifying *Mycobacterium bovis* as a causative agent of human tuberculosis. *Eur Respir J* 2010;35(3):692-4.
9. Healy E, Rogers S. Tuberculosis verrucosa cutis in association with bovine tuberculosis. *J R Soc Med* 1992;85(11):704-5.
10. Erbagci Z, Tuncel A, Bayram N, Erkilic S, Bayram A. Tuberculosis verrucosa cutis in a patient with long-standing generalized lichen planus: improvement of lichen after antitubercular polychemotherapy. *J Dermatolog Treat* 2006;17(5):314-8.

11. Gawkrödger DJ. Mycobacterial infections. In: Champion RH, Burton JL, Burns DA, Breathnach SM, eds. *Rook Textbook of Dermatology*. 6th ed. Oxford: Blackwell Science; 1998. p.1199-200.
12. Ho CK, Ho MH, Chong LY. Cutaneous tuberculosis in Hong Kong: an update. *Hong Kong Med J* 2006;12(4):272-7.
13. Kumar B, Muralidhar S. Cutaneous tuberculosis: a twenty-year prospective study. *Int J Tuberc Lung Dis* 1999;3(6):494-500.
14. Sehgal VN, Srivastava G, Rhurana VK, Sharman VK, Bhalla P, Beohar PC. An appraisal of epidemiologic, clinical, bacteriologic, histopathologic and immunologic parameters in cutaneous tuberculosis. *Int J Dermatol* 1987; 26(8):521-6.
15. Sehgal VN, Srivastava G, Bajaj P, Sengal R. Re-infection (secondary) inoculation cutaneous tuberculosis. *Int J Dermatol* 2001;40(3): 205-9.
16. Sehgal VN, Sardana K, Bajaj P, Bhattacharya SN. Tuberculosis verrucosa cutis: antitubercular therapy, a well-conceived diagnostic criterion. *Int J Dermatol* 2005;44(3):230-2.
17. Abdalla CM, de Oliveira ZN, Sotto MN, Leite KR, Canavez FC, de Carvalho CM. Polymerase chain reaction compared to other laboratory findings and to clinical evaluation in the diagnosis of cutaneous tuberculosis and atypical mycobacteria skin infection. *Int J Dermatol* 2009;48(1):27-35.
18. Kobashi Y, Shimizu H, Ohue Y, Mouri K, Obase Y, Miyashita N, et al. Comparison of T-cell interferon-gamma release assays for Mycobacterium tuberculosis-specific antigens in patients with active and latent tuberculosis. *Lung* 2010;188(4):283-7.
19. Ramos-e-Silva M, Ribeiro de Castro MC. Mycobacterial infections. In: Bologna JL, Jorizzo JL, Rapin RP, eds. *Dermatology*. Vol 1. 2nd ed. Edinburgh: Mosby; 2003. p.1145-65.