

Eosinophilic Esophagitis Presenting with Dysphagia Due to Food (Garlic) Impaction: Report of a Case with Literature Review

Gıda (Sarımsak) Takılmasına Bağlı Disfaji ile Prezente Olan Eozinofilik Özofajit: Olgu Sunumu ve Literatürün Değerlendirilmesi

Hakan DEMİRCİ,^a
Yusuf Serdar SAKİN,^a
Zülfikar POLAT,^a
Ahmet UYGUN,^a
Sait BAĞCI^a

^aDepartment of Gastroenterology,
Gülhane Military Medical Academy,
Ankara

Geliş Tarihi/Received: 30.01.2013
Kabul Tarihi/Accepted: 31.05.2013

Yazışma Adresi/Correspondence:
Hakan DEMİRCİ
Gülhane Military Medical Academy,
Department of Gastroenterology, Ankara,
TÜRKİYE/TURKEY
hakandemircigata@yahoo.com

ABSTRACT Eosinophilic esophagitis (EoE) is a chronic disease usually presenting with dysphagia and food impaction. Food allergy has been suggested as a causative trigger for some patients. Diagnosis of EoE is based on characteristic endoscopic and histological features. A ringed appearance referred to as “trachealization” is the classical endoscopic finding. Eosinophil-predominant inflammation is typical in histologic examination. The use of topical steroids is an effective and viable therapeutic option in the management of EoE in adults with relatively few side effects. Herein, we report a case of EoE presenting with severe dysphagia due to garlic impaction. Inhaled corticosteroid (budesonide) was prescribed for treatment due to the patient’s history of long-term proton-pump inhibitor use. Dysphagia complaints resolved after the prescribed treatment.

Key Words: Eosinophilic esophagitis; deglutition disorders; garlic

ÖZET Eozinofilik özofajit (EoE), genellikle disfaji ve gıda takılmasıyla prezente olan kronik bir hastalıktır. Gıda alerjisinin bazı hastalarda tetikleyici bir rol oynadığı düşünülmektedir. EoE tanısı, karakteristik endoskopik ve histolojik bulgulara dayanılarak konulmaktadır. Klasik endoskopik bulgusu “trakealizasyon” adı verilen özofagusun halka şeklinde görünümüdür. Tipik histolojik bulgusu eozinofil-predominant inflamasyondur. Topikal steroidlerin kullanımı nispeten az yan etkileri ile birlikte erişkinlerde EoE takibinde etkili ve önemli bir tedavi seçeneği olarak durmaktadır. Bu yazıda sarımsak takılmasına bağlı ciddi disfaji şikayeti ile prezente olan EoE olgusunu sunuyoruz. Hastanın geçmişinde uzun süreli proton pompa inhibitörü kullanımı olduğundan dolayı inhale kortikosteroid (budesonid) tedavisi verildi. Disfaji şikayetleri tedavinin ardından tamamen düzeldi.

Anahtar Kelimeler: Eozinofilik özofajit; yutma bozuklukları; sarımsak

Türkiye Klinikleri J Case Rep 2013;21(3):145-7

Foreign body ingestion and food bolus impaction is not uncommon. In the United States, more than 100,000 cases of foreign body ingestion are reported annually, occurring predominantly in the pediatric population.¹⁻⁴ Fortunately, the majority of ingested foreign bodies reaching the gastrointestinal tract pass spontaneously. Pre-endoscopic series revealed that 80% or more of foreign objects pass without any intervention.^{2,3} Endoscopic removal is needed in only 10% to 20% of cases, and less than 1% require surgical intervention.^{1,5,6} Despite the very low mortality from foreign body ingestion, deaths have been reported.^{5,7,8} Eosinophilic esophagitis (EoE) is a disease characterized by eosinophilic inflammation of the esophagus. The

symptoms of EoE including abdominal pain, vomiting, food impaction, dysphagia, and dyspnea are quite similar to gastroesophageal reflux disease (GERD) symptoms. The clinician should have a high index of suspicion for the diagnosis of EoE particularly in the setting of refractory GERD symptoms. Yet there is a paucity of epidemiological data from our country for the prevalence of EoE, however, studies from United States report the prevalence as being 4,3/100.000 in children and 2,5/100.000 in adults.^{9,10} In a study from our country, out of the 44 patients admitting to the emergency departments with complaints of food impaction, 28 patients were diagnosed with EoE which suggests a close relationship between EoE and food impaction.¹¹ Herein, we report a case of EoE presenting with severe dysphagia due to garlic impaction.

CASE REPORT

A 42-year-old male patient was admitted to our clinic with complaints of food sticking in the throat. He had a history of atopic dermatitis and dysphagia. Without any pathological findings being detected in previous assessments, he was prescribed a proton-pump inhibitor and had been using it for about 1 year to relieve his GERD like symptoms. Gastrointestinal endoscopy revealed garlic impaction in mid-esophagus which was then grasped with a snare and removed (Figure 1). During the

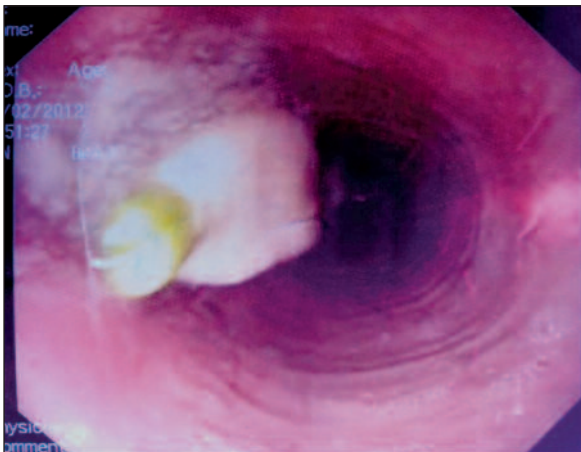


FIGURE 1: Endoscopic image showing garlic impaction at 27 cm of esophagus and multiple thin linear concentric rings.

(See color figure at <http://www.turkiyeklinikleri.com/journal/turkiye-klinikleri-journal-of-case-reports/1300-0284/tr-index.html>)

procedure, red esophageal linings with folds and esophageal rings were observed and multiple biopsies of middle and distal esophagus were performed with a prediagnosis of EoE. Pathological evaluation revealed significantly increased infiltration of eosinophilic leukocytes (>20 eosinophils per high power field). Marked basal cell hyperplasia and elongation of lamina propria papillae was also observed (Figure 2). Gastric biopsies were normal. Histopathological assessment along with detailed evaluation of clinical features and history revealed the diagnosis of EoE. Inhaled corticosteroid (budesonide) was prescribed for treatment due to the patient's history of long-term proton-pump inhibitor use. Inhaler budesonide was used twice daily at a dose of 2 mg per day by directly puffing into the mouth and then dry swallowing without inhaling. The patient was instructed to avoid eating, drinking, or rinsing his mouth for 30 minutes after using the medication. Dysphagia complaints resolved after the prescribed treatment. Repeated esophageal food impaction was not observed. Follow-up endoscopic assessment at 3 months revealed no pathological findings in the esophagus and his dysphagia resolved completely.

DISCUSSION

EoE is a chronic disease usually presenting with dysphagia and food impaction. Food allergy has been

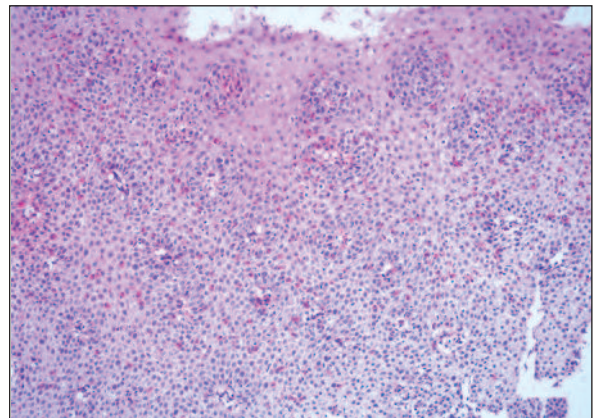


FIGURE 2: Histopathological view (Significantly increased infiltration of eosinophilic leukocytes. Marked basal cell hyperplasia and elongation of lamina propria papillae was also observed).

(See color figure at <http://www.turkiyeklinikleri.com/journal/turkiye-klinikleri-journal-of-case-reports/1300-0284/tr-index.html>)

suggested as a causative trigger for some patients.¹² Diagnosis of EoE is based on characteristic endoscopic and histological features. A ringed appearance referred to as “trachealization” is the classical endoscopic finding. Other findings may include strictures, erosions, longitudinal ridging, erythema, white plaques, and a loss of vascularity.^{13,14} Endoscopic findings may not always be present, however, mucosal biopsies are warranted when EoE is a likely diagnosis.¹⁵ Eosinophil-predominant inflammation is typical in histologic examination.

Differential diagnosis of EoE includes a wide spectrum of diseases accompanied by eosinophilic infiltration in the esophagus, such as GERD, eosinophilic gastroenteritis, parasitic and fungal infections, recurrent vomiting, esophageal leiomyomatosis, inflammatory bowel disorders, hypereosinophilic syndrome, myeloproliferative disorders,

periarteritis, allergic vasculitis, drug injury, scleroderma and carcinomatosis.^{1,3}

EoE comprises a well-established cause of dysphagia. Gastroenterologists should have a high index of suspicion for this relatively rare entity when typical clinical and endoscopic features are present. Biopsies of the proximal and distal esophagus are warranted to confirm histopathological diagnosis. Presence of eosinophil-predominant infiltration is necessary for establishing the diagnosis. Dietary therapy is a widely accepted treatment option in children, however, there exists scant evidence supporting the efficacy of such therapy in adults. The use of topical steroids is an effective and viable therapeutic option in the management of EoE in adults with relatively few side effects.⁶ The long-term prognosis of EoE is yet to be defined; however, data suggest a benign course.⁸

REFERENCES

1. Wyllie R. Foreign bodies in the gastrointestinal tract. *Curr Opin Pediatr* 2006;18(5):563-4.
2. Webb WA. Management of foreign bodies of the upper gastrointestinal tract: update. *Gastrointest Endosc* 1995;41(1):39-51.
3. Waltzman ML, Baskin M, Wypij D, Mooney D, Jones D, Fleisher G. A randomized clinical trial of the management of esophageal coins in children. *Pediatrics* 2005;116(3):614-9.
4. Little DC, Shah SR, St Peter SD, Calkins CM, Morrow SE, Murphy JP, et al. Esophageal foreign bodies in the pediatric population: our first 500 cases. *J Pediatr Surg* 2006;41(5):914-8.
5. Triadafilopoulos G, Roorda A, Akiyama J. Update on foreign bodies in the esophagus: diagnosis and management. *Curr Gastroenterol Rep* 2013;15(4):317.
6. Uyemura MC. Foreign body ingestion in children. *Am Fam Physician* 2005;72(2):287-91.
7. Shivakumar AM, Naik AS, Prashanth KB, Yogesh BS, Hongal GF. Foreign body in upper digestive tract. *Indian J Pediatr* 2004;71(8):689-93.
8. Simic MA, Budakov BM. Fatal upper esophageal hemorrhage caused by a previously ingested chicken bone: case report. *Am J Forensic Med Pathol* 1998;19(2):166-8.
9. Guajardo JR, Plotnick LM, Fende JM, Collins MH, Putnam PE, Rothenberg ME. Eosinophil-associated gastrointestinal disorders: a worldwide-web based registry. *J Pediatr* 2002;141(4):576-81.
10. Noel RJ, Putnam PE, Rothenberg ME. Eosinophilic esophagitis. *New Engl J Med* 2004; 351(9):940-1.
11. Culcu OD, Dogan Y. [Eosinophilic esophagitis: Is it a common cause of food impaction?] *Ulusal Cerrahi Dergisi* 2011;27(2):78-81.
12. Yardeni D, Yardeni H, Coran AG, Golladay ES. Severe esophageal damage due to button battery ingestion: can it be prevented? *Pediatr Surg Int* 2004;20(7):496-501.
13. Spergel JM. Eosinophilic esophagitis in adults and children: evidence of a food allergy component in many patients. *Curr Opin Allergy Clin Immunol* 2007;7(3):274-8.
14. Ireland-Jenkin K, Wu X, Heine RG, Cameron DJ, Catto-Smith AG, Chow CW. Oesophagitis in children: reflux or allergy? *Pathology* 2008;40(2):188-95.
15. Dellon ES, Aderoju A, Woosley JT, Sandler RS, Shaheen NJ. Variability in diagnostic criteria for eosinophilic esophagitis: a systemic review. *Am J Gastroenterol* 2007;102(10):2300-13.