

A Rare Case: A Giant Acrochordon and Skin Ulcer Due to the Traction of Acrochordon

Nadir Bir Olgu: Dev Bir Akrokordon ve Akrokordonun Çekmesine Bağlı Oluşan Deri Ülseri

^{ID} Rafet ÖZBEY^a, ^{ID} Dursun TÜRKMEN^b

^aMalatya Training and Research Hospital, Clinic of Plastic and Reconstructive Surgery, Malatya, TÜRKİYE

^bMalatya Training and Research Hospital, Clinic of Dermatology, Malatya, TÜRKİYE

ABSTRACT Acrochordons are benign skin lesions which are often seen in the neck and armpit. Acrochordons are also known by names such as fibroepithelial polyp, skin tags and soft fibroma. In routine clinical cases, acrochordons are generally smaller than 5 millimeters. Although it is rare, malignancy is observed in acrochordons. Here we present a 84 year old female patient with a giant mass of 17x13x4 cm under the left arm and an about 2x3 cm diameter skin ulcer due to the weight of the mass. We would like to remind that such ulcerations should not be ignored for malignant transformation.

Keywords: Fibroma; skin; skin ulcer; traction

ÖZET Akrokordonlar, sıklıkla boyun ve koltuk altlarında görülen iyi huylu deri lezyonlarıdır. Akrokordonlar, ayrıca fibroepitelyal polip, skin tag, yumuşak fibrom gibi isimlerle de bilinir. Klinik pratikte karşılaşılan akrokordonlar genellikle 5 mm'den daha küçüktür. Nadir de olsa akrokordonlarda malignite görülebilir. Biz burada sol koltuk altında 17x13x4 cm boyutlarında dev bir kitleye ve kitlenin ağırlığından dolayı gelişmiş yaklaşık 2x3 cm çapında deri ülserine sahip olan 84 yaşında bir kadın hastayı sunduk. Malign dönüşüm için bu tür ülserlerin göz ardı edilmemesi gerektiğini hatırlatmak isteriz.

Anahtar Kelimeler: Fibrom; cilt; deri ülseri; traksiyon

Acrochordons are benign skin lesions which are frequently seen, often small and skin colored, and located anywhere on the body surface area despite mostly seen in the axilla and neck. Acrochordons are also known by names such as fibroepithelial polyp, skin tags and soft fibroma. It is one of the most common skin lesions.¹ They are stalked lesions which are often seen in the neck and armpit.² Several studies have revealed an association of acrochordons with conditions such as obesity, diabetes mellitus, atherogenic lipid profile, acromegaly and Crohn's disease.³ Acrochordons are generally more common in overweight individuals. It has been suggested that hyperinsulinemia and increased leptin levels may play a role in the de-

velopment of acrochordon in overweight individuals.⁴ It has been reported that acrochordons are closely associated with conditions leading to hyperinsulinemia such as metabolic syndrome (MetS) and may play a role in the early diagnosis of MetS.^{3,5} Acanthosis nigricans is common in obese and diabetic patients, therefore it is likely to be associated with acrocordon.⁶

In this article, the lesion that we presented draws attention with ulcer development in its origin in the axillary region by undergoing traction as the result of gravity depending on the weight of this mass besides it is a giant acrochordon which is a rare form of such lesions.

Correspondence: Dursun TÜRKMEN
Malatya Training and Research Hospital, Clinic of Dermatology, Malatya, TÜRKİYE
E-mail: dursunturkmen44@gmail.com



Peer review under responsibility of Türkiye Klinikleri Journal of Dermatology.

Received: 21 Feb 2019

Received in revised form: 15 Jul 2019

Accepted: 18 Jul 2019

Available online: 21 Sep 2020

2146-9016 / Copyright © 2020 by Türkiye Klinikleri. This is an open access article under the CC BY-NC-ND license (<http://creativecommons.org/licenses/by-nc-nd/4.0/>).

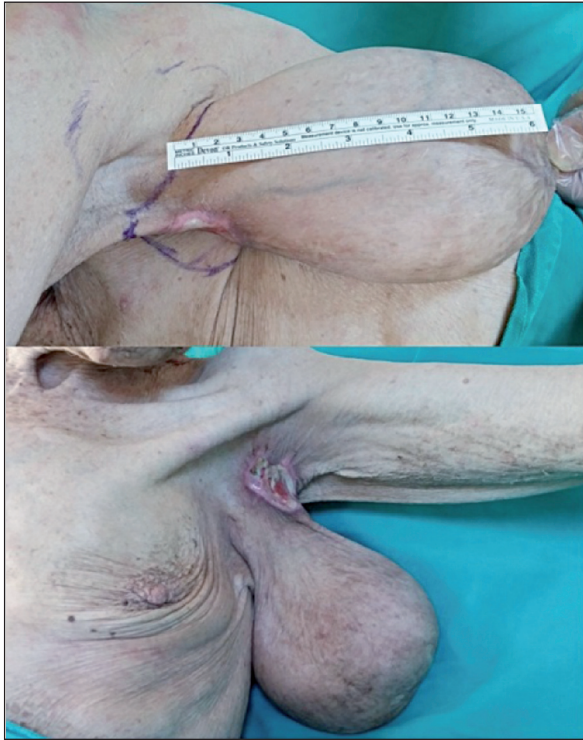


FIGURE 1: A case of giant acrochordon with ulceration in line of traction in the left axilla.

CASE REPORT

A 84-year-old female patient was admitted with complaint of the mass in the left armpit by claiming that it is innate and has grown steadily in recent years. She reported that there has been an unhealed wound on the mass for a few weeks. In the first examination, it was showed that a giant mass has a stalk in the left axilla and oscillates freely, provides a solid image with touch. Ulceration area was observed to be about 2x3 cm in diameter in the origin of mass in the axilla (Figure 1). In the first observation, it was thought that ulcer could have been occurred due to traction by the weight of the mass or malignancy. After the patient had been informed, the mass was excised under local anesthesia. Open wound which formed after excision was closed by primary suture. Histopathological examination of the mass was made; it was histologically diagnosed as fibroepithelial polyp (acrochordon) measuring 17x13x4 cm with an ulceration 2x3 cm in diameter on it. There was no complications in the postoperative period. We received the patient's consent form for publishing all photographic materials.

DISCUSSION

In routine clinical cases, acrochordons are generally smaller than 5 millimeters.⁷ In the literature, it has been reported that the giant acrochordons are to be reached up to 8 cm in diameter and up to 2.5 kilograms in weight.^{8,9} We have determined in our case that the fibroepithelial polyp was measuring 17x13x4 cm. Fibroepithelial polyps are known to be placed much more in lower extremities.¹⁷ The articles draw attention to report a giant acrochordon on major labia.¹⁰ A giant acrochordon located in the scrotum was also reported in 2015.¹¹ In our case, it is seen that the mass was located in the left axilla region.

Although it is rare, malignancy is observed in fibroepithelial polyp. In general, the malignancy rate of skin tag is reported to be 0.37%.⁸ Agir et al.¹ reported that a case developed squamous cell carcinoma on fibroepithelial polyp in knee region. Such cases should be examined carefully because malignant tumor can develop in fibroepithelial polyps which are exposed to chronic irritation and inflammation. All fibroepithelial polyps which have these risks, especially giant fibroepithelial polyps should be excised and histopathological examination of these specimens must be done. In the literature, the authors seem to be unanimous about that fibroepithelial polyp can be malignant as a result of chronic inflammation and irritation.¹² We saw in our case that it was ulcerated by the effect of gravity as a result of the weight of the mass without the irritation. In our histopathological examination, there was no evidence for malignancy. However, we would like to remind that such ulcerations should not be ignored for malignant transformation.

Source of Finance

During this study, no financial or spiritual support was received neither from any pharmaceutical company that has a direct connection with the research subject, nor from a company that provides or produces medical instruments and materials which may negatively affect the evaluation process of this study.

Conflict of Interest

No conflicts of interest between the authors and/or family members of the scientific and medical committee members or members of the potential conflicts of interest, counseling, expertise, working conditions, share holding and similar situations in any firm.

Authorship Contributions

Idea/Concept: Rafet Özbey, Dursun Türkmen; **Design:** Rafet Özbey; **Control/Supervision:** Rafet Özbey, Dursun Türkmen; **Data Collection and/or Processing:** Rafet Özbey; **Analysis**

and/or Interpretation: Rafet Özbey, Dursun Türkmen; **Literature Review:** Rafet Özbey; **Writing the Article:** Rafet Özbey, Dursun Türkmen; **Critical Review:** Dursun Türkmen; **References and Fundings:** Rafet Özbey; **Materials:** Rafet Özbey.

REFERENCES

1. Agir H, Sen C, Cek D. Squamous cell carcinoma arising from a fibroepithelial polyp. *Ann Plast Surg.* 2005;55(6):687-8. [[Crossref](#)] [[PubMed](#)]
2. Banik R, Lubach D. Skin tags: localization and frequencies according to sex and age. *Dermatologica.* 1987;174(4):180-3. [[Crossref](#)] [[PubMed](#)]
3. Wali V, Wali VV. Assessment of various biochemical parameters and bmi in patients with skin tags. *J Clin Diagn Res.* 2016;10(1):BC09-11.
4. Tahtacı M, Ersoy R, Ersoy O. [The relation of perianal acrochordons with insulin resistance]. *Ankara Med J.* 2018;(3):322-7.
5. Shah R, Jindal A, Patel N. Acrochordons as a cutaneous sign of metabolic syndrome: a case-control study. *Ann Med Health Sci Res.* 2014;4(2):202-5. [[Crossref](#)] [[PubMed](#)] [[PMC](#)]
6. Asokan N, Binesh VG. Cutaneous problems in elderly diabetics: a population-based comparative cross-sectional survey. *Indian J Dermatol Venereol Leprol.* 2017;83(2):205-11. [[Crossref](#)] [[PubMed](#)]
7. Fetsch JF, Davis CJ Jr, Hallman JR, Chung LS, Lupton GP, Sesterhenn IA. Lymphedematous fibroepithelial polyps of the glans penis and prepuce: a clinicopathologic study of 7 cases demonstrating a strong association with chronic condom catheter use. *Hum Pathol.* 2004;35(2):190-5. [[Crossref](#)] [[PubMed](#)]
8. Eads TJ, Chuang TY, Fabr  VC, Farmer ER, Hood AF. The utility of submitting fibroepithelial polyps for histological examination. *Arch Dermatol.* 1996;132(12):1459-62. [[Crossref](#)]
9. Choudhary ST. Treatment of unusually large acrochordon by shave excision and electrodesiccation. *J Cutan Aesthet Surg.* 2008;1(1):21-2. [[Crossref](#)] [[PubMed](#)] [[PMC](#)]
10. Doe PT, Grattan CE. Guess what! Skin tag (acrochordon) on the labium majus. *Eur J Dermatol.* 1998;8(8):587-8.
11. Sancaktutar AA, Bozkurt Y, Tepeler A, Penbeg  N, Atar M. An unusual mass on the skin of scrotum: acrochordon. *Journal of Clinical and Analytical Medicine.* 2015;6(1):112-3. [[Crossref](#)]
12. Aksoy B, Aksoy HM, Civaş E,  st n H. Giant skin tags located in the lower half of the body: report of two cases. *Turkiye Klinikleri J Med Sci.* 2009;29(6):1770-2.