

# Isolated Torsion of the Fallopian Tube in a Reproductive-Aged Woman: Case Report

## Reproduktif Çağdaki Bir Kadında İzole Tubal Torsiyon

Engin KORKMAZER,<sup>a</sup>  
Muzaffer TEMUR,<sup>a</sup>  
Tayfur ÇİFT,<sup>a</sup>  
Elif ŞAHİN<sup>a</sup>

<sup>a</sup>Clinic of Gynecology and Obstetrics,  
Bursa Yüksek İhtisas Training and  
Research Hospital,  
Bursa

Geliş Tarihi/Received: 29.12.2016  
Kabul Tarihi/Accepted: 02.03.2017

Yazışma Adresi/Correspondence:  
Engin KORKMAZER  
Bursa Yüksek İhtisas Training and  
Research Hospital,  
Clinic of Gynecology and Obstetrics, Bursa,  
TURKEY/TÜRKİYE  
ekorkmazer@yahoo.com

**ABSTRACT** Adnexal cystic lesions are often found in reproductive age women, most of them origins from ovary. Nearly all are functional cysts, and only few of them require aggressive management. However, isolated torsion of the fallopian tube is rare and this clinical entity mimics the torsion of the ovary. It's hard to diagnose because of the rarity. Prior tubal surgery, tubal-paratubal cystic masses, pelvic inflammatory disease, hydrosalpinx, congenital anomalies and trauma are the main risk factors. Laparoscopic intervention is the gold standard method for diagnose and treatment. In this case, we report the isolated torsion of the fallopian tube and its management in a reproductive-aged woman, in the light of the literature.

**Keywords:** Fallopian tubes; torsion, mechanical; adnexa uteri

**ÖZET** Adneksiyal yerleşimli kistik lezyonlar genellikle reproduktif çağdaki kadınları etkiler ve genelde over kaynaklıdır. Genellikle çoğu fonksiyonel kistler olup çok azı agresif tedavi gerektirir. İzole tubal torsiyon oldukça nadir görülen bir klinik tablo olmakla birlikte genellikle over torsiyonunu taklit eder. Nadir görülen bir klinik tablo olması nedeniyle tanısı zordur. Geçirilmiş tubal cerrahi, tubal-paratubal kistik lezyonlar, pelvik inflamatuvar hastalık, hidrosalpink, konjenital anomaliler ve travma temel risk faktörleridir. Tanı ve tedavide laparoskopik girişim altın standart metoddur. Bu vaka sunumumuzda, reproduktif çağda bir kadında izole fallop tüpü torsiyonu ve onun tanı ile tedavisini literatür eşliğinde paylaştık.

**Anahtar Kelimeler:** Fallop tüpleri; torsiyon, mekanik; uterus ekleri

Isolated torsion of the fallopian tube (ITFT) without an ovarian abnormality is an uncommon clinical entity. Incidence of ITFT is approximately 1 in 1,500,000 females.<sup>1</sup> ITFT mostly occurs in reproductive-aged women. It's extremely rare in pre-pubertal and postmenopausal ages. Prior tubal surgery, tubal-paratubal cystic masses, pelvic inflammatory disease and trauma are the main risk factors for ITFT.<sup>2</sup> Clinical presentation of ITFT is similar with ovarian torsion such as lower abdominal pain, nausea, vomiting and peritoneal irritation signs. In this report, we presented surgical management of an ITFT case in the light of the literature.

### CASE REPORT

A 38-year-old woman, gravida 2, para 2, presented with a 2-day history of acute lower abdominal pain, nausea and vomiting. Her medical and family

histories were normal. She was not taking any medications. Her pulse rate was 74/minute, respiratory rate 14/minute, blood pressure 120/70 mm Hg, and temperature 36.5°C. Pelvic examination revealed mild cervical lifting pain, left adnexal tenderness, and mild rebound pain. Laboratory results were white cell count 8700 cells/mm<sup>3</sup>, hemoglobin 11.5 g/dl, platelets 167,000 cells/mm<sup>3</sup>, C-reactive protein 18 mg/l (normal < 5 mg/l), and erythrocyte sedimentation rate 25 mm/hour (normal <20 mm/hr). Remaining laboratory results including blood pregnancy test and tumor markers were negative.

On transvaginal ultrasound, an unilocular hypoechoic cystic mass and a small amount of ascites in the pouch of Douglas were observed in the left adnexa measuring 4.3×5.6 cm with encoded stream. After the evaluation of the patient an urgent laparoscopy was performed based on physical examination and ultrasound. Informed consent form obtained from patient. During laparoscopy, her left fallopian tube was noted to be dark red, dilated, and twisted several times (Figure 1). Her left fimbria was necrotic-appearing and could not be preserved. Therefore, a laparoscopic left salpingectomy was performed. A histologic examination revealed ischemic changes with congestion of her left fallopian tube, which was consistent with tubal torsion. She had an uncomplicated post-operative course.

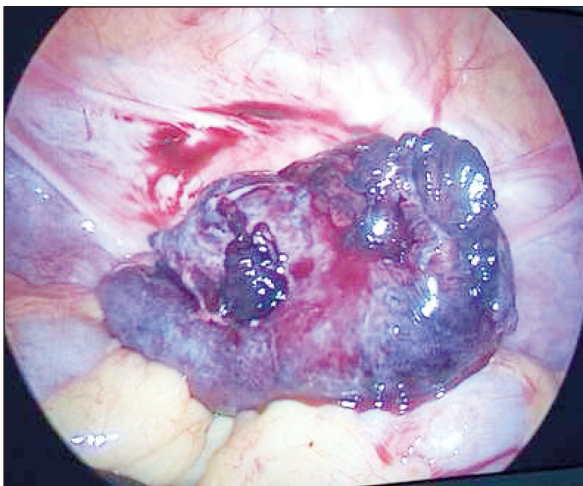


FIGURE 1: Necrotic appearance of left tuba.

## DISCUSSION

Isolated fallopian tube torsion is a rare cause of lower quadrant abdominal/pelvic pain. This condition primarily affects ovulating women and is infrequently seen in postmenopausal and adolescent women.

In most cases, the isolated tubal torsion is associated with other conditions that have in some way altered the normal pelvic anatomy. Youssef et al. classified factors that influenced tubal torsion into either internal or external causes and described a mechanism of torsion, which included mechanical disturbance, venous obstruction, lymphatic congestion, diffuse edema, and tubal enlargement all resulting in torsion.<sup>3</sup> In our patient, the most probable cause of ITFT was a para-tubal cyst. Tubal torsion more commonly affects the right side, possibly because of partial immobilization of the left tube by its proximity to the sigmoid mesentery and because right lower quadrant pain is more often surgically explored because of the concern for appendicitis.<sup>4</sup>

Diagnosis of tubal torsion remains difficult because of its rarity and non-specific symptoms. The disorder can be completely asymptomatic, it can mimic acute pelvic inflammatory disease, and it can be an unrecognized cause of pelvic pain in some women after tubal sterilization.<sup>4</sup> The most common symptom of ITFT is convulsive pain at lower abdomen and pelvis, projecting to the side of the torsion. Presenting signs and symptoms also include nausea and vomiting, peritoneal signs, and a discrete adnexal mass. Clinically, differential diagnostic considerations include ovarian torsion, rupture of the ovarian follicle or cyst, appendicitis, ectopic pregnancy, pelvic inflammatory disease, intestinal obstruction or perforation, urolithiasis, and cystitis. Ovarian torsion associated with tubal torsion is far more common than ITFT.

Ultrasound and other imaging modalities (CT, MRI) have limited affect on diagnosis.<sup>4</sup> Laparoscopy is currently the most specific diagnostic tool for evaluating torsion. The definitive diagnosis is most often made retrospectively, usually after diagnostic laparoscopy.

Laparoscopic intervention is the main treatment method of ITFT.

Laparoscopic detorsion of the tube is the primary treatment option for the ITFT, but in cases of necrosis, salpingectomy should be considered.<sup>5</sup>

ITFT is an uncommon cause of acute abdominal pain in women. Because of the absence of pathognomonic clinical symptoms or findings on imaging or laboratory studies, a high index of suspicion is required. Early laparoscopy is necessary in case of suspicion because of fertility issues.

### **Conflict of Interest**

*Authors declared no conflict of interest or financial support.*

### **Authorship Contributions**

**Idea/Concept:** Engin Korkmazer; **Design:** Engin Korkmazer, Muzaffer Temur; **Control/Supervision:** Muzaffer Temur, Tayfur Çift; **Data Collection and/or Processing:** There is no data collection; **Analysis and/or Interpretation:** Elif Şahin; **Literature Review:** Engin Korkmazer, Elif Şahin; **Writing the Article:** Engin Korkmazer, Muzaffer Temur; **Critical Review:** Tayfur Çift, Engin Korkmazer; **References and Fundings:** There is no financial support; **Materials:** Engin Korkmazer, Muzaffer Temur, Tayfur Çift, Elif Şahin.

## REFERENCES

1. Hansen OH. Isolated torsion of the Fallopian tube. *Acta Obstetrica et Gynecologica Scandinavica* 1970;49(1):3-6.
2. Comerci G, Colombo FM, Stefanetti M, Grazia G. Isolated fallopian tube torsion: a rare but important event for women of reproductive age. *Fertil Steril* 2008;90(4):1198.e23-5.
3. Youseff AF, Fayad MM, Shafeek MA. Torsion of the fallopian tube. A clinico-pathological study. *Acta Obstet Gynecol Scand* 1962; 41(1):292-309.
4. Harmon JC, Binkovitz LA, Binkovitz LE. Isolated fallopian tube torsion: sonographic and CT features. *Pediatr Radiol* 2008;38(2):175-9.
5. Krissi H, Shalev J, Bar-Hava I, Langer R, Herman A, Kaplan B. Fallopian tube torsion: laparoscopic evaluation and treatment of a rare gynecological entity. *J Am Board Fam Pract* 2001;14(4):274-7.