

# Successful Spinal Anesthesia in a Case of Ankylosing Spondylitis

## ANKILOZAN SPONDİLİT OLGUSUNDA BAŞARILI SPİNAL ANESTEZİ

Necati ÇANAKÇI\*, Meltem ÜNSAL\*\*, Aynur AYDEMİR\*\*, Yeşim ATEŞ\*

\* Assoc.Prof., Dept. of Anaesthesiology & Reanimation, Ankara University Medical Faculty,

\*\* Resident, Dept of Anaesthesiology & Reanimation, Ankara University Medical Faculty, Ankara, TURKEY

### Summary

**Objective:** Although the difficulty of performing successful neuraxial blockade in ankylosing spondylitis is generally accepted, some reports have suggested regional anaesthesia in selected cases in which difficult airway is anticipated. We are reporting a case of ankylosing spondylitis with a previous history of difficult intubation, successfully managed by spinal anaesthesia.

**Case report:** A 45-year-old man with a history of 20 years of ankylosing spondylitis was scheduled for elective left inguinal hernia repair. Previous history revealed unsuccessful attempt of endotracheal intubation 9 years before, for the repair of right inguinal hernia. Therefore general anaesthesia was not considered in the first place and successful spinal anaesthesia was achieved with heavy bupivacaine %0.5.

**Conclusion:** Patients with ankylosing spondylitis are challenging to the anaesthetists however neuraxial techniques should not be regarded as unachievable even in the complex cases.

**Key Words:** Ankylosing spondylitis, Spinal anaesthesia

T Klin J Med Sci 2001, 21:307-310

### Özet

**Amaç:** Ankilozan spondilitte başarılı rejjonal anestezi uygulamasının güçlükleri genel olarak kabul edilmekle birlikte, bazı araştırmacılar zor havayolu beklentisi bulunan seçilmiş olgularda rejjonal anestezi uygulanmasını önermektedirler. Bu olgu sunusunda zor entübasyon anamnezi bulunan ankilozan spondilitli bir erkek hastada başarılı spinal anestezi uygulaması bildirilmektedir.

**Olgu sunusu:** 20 yıllık ankilozan spondilit anamnezi olan 45 yaşındaki erkek hastada elektif şartlarda sol inguinal herni onarımı planlandı. Hastanın daha önceki anestezi uygulamasına konusundaki anamnezinden 9 yıl önce sağ inguinal herni onarımı operasyonunda endotrakeal entübasyonun denendiği ancak başarılı olunamadığı öğrenildi. Bu nedenle ilk planda genel anestezi uygulanmadı ve vücuttaki tüm eklemelerinde ileri derecede hareket kısıtlılığı bulunan bu hastada %0.5'lik hiperbarik bupivakain ile spinal anestezi uygulandı.

**Sonuç:** Ankilozan spondilitli olgular anestezi yaklaşım açısından çoğu zaman sorunlu hastalardır ancak hastalığın ileri döneminde de nöraksial teknikler imkansız olarak kabul edilmemeli, gereken hastalarda denenmelidir.

**Anahtar Kelimeler:** Ankilozan spondilit, Spinal anestezi

T Klin Tıp Bilimleri 2001, 21:307-310

Ankylosing spondylitis is one of the group of seronegative spondyloarthropathies with unknown causes other members of this group include psoriatic arthritis Reiter's syndrome and enteropathic arthritis (1). It is also defined as an inflammatory arthropathy of insidious onset (1-4). The primary sites of involvement are the sacroiliac joint and the spine, although %50 of cases has extra spinal joint involvement at some time. It is a systemic disorder and a proportion of the patients will develop non-articular manifestations of the inflammatory process (4).

**Geliş Tarihi:** 29.11.2000

**Yazışma Adresi:** Dr.Yeşim ATEŞ  
Ankara Üniversitesi Tıp Fakültesi  
Anesteziyoloji ve Reanimasyon AD, ANKARA

T Klin J Med Sci 2001, 21

Patients with ankylosing spondylitis may present for any type of surgery. A small proportion of cases with long-standing disease may require surgery directed towards the complications of the disease process itself. Repair of inguinal hernia, hip surgery, lumbar or cervical osteotomy, temporomandibular, cardiac and vocal cord surgery have all been reported (4-7).

Ankylosing spondylitis patients present specific challenges to the anaesthetist. Both airway management and neuraxial access may prove to be difficult (6). Ossification of interspinous ligaments and formation of bony bridges (syndesmophytes) between the vertebrae, resulting in a classic "bamboo spine" appearance, make the placement of a spinal or epidural needle difficult or impossible (4, 8).

Here, we present a case of ankylosing spondylitis with multiple extra-spinal joint involvements and a previous his-

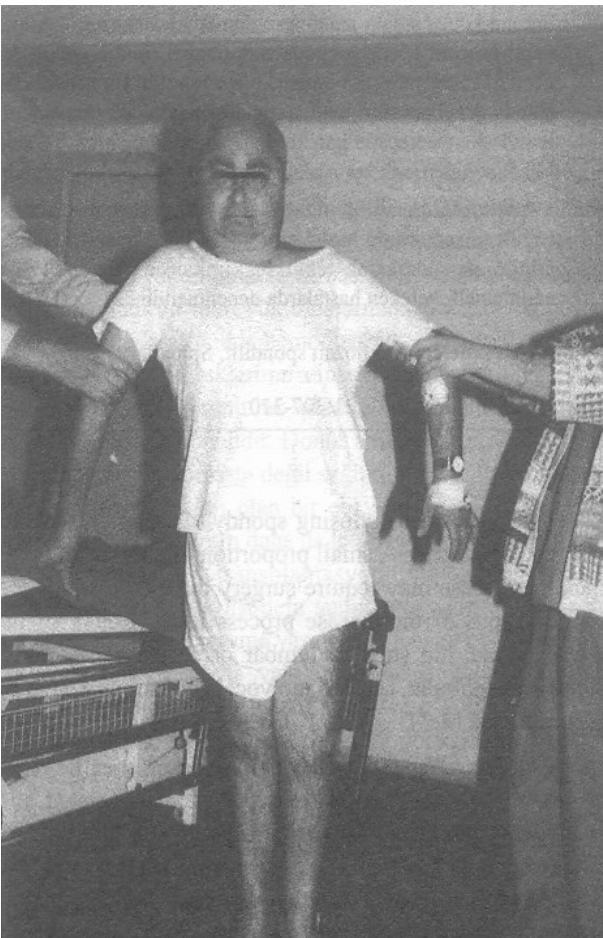
tory of unsuccessful endotracheal intubation, managed successfully with spinal anaesthesia.

### Case Report

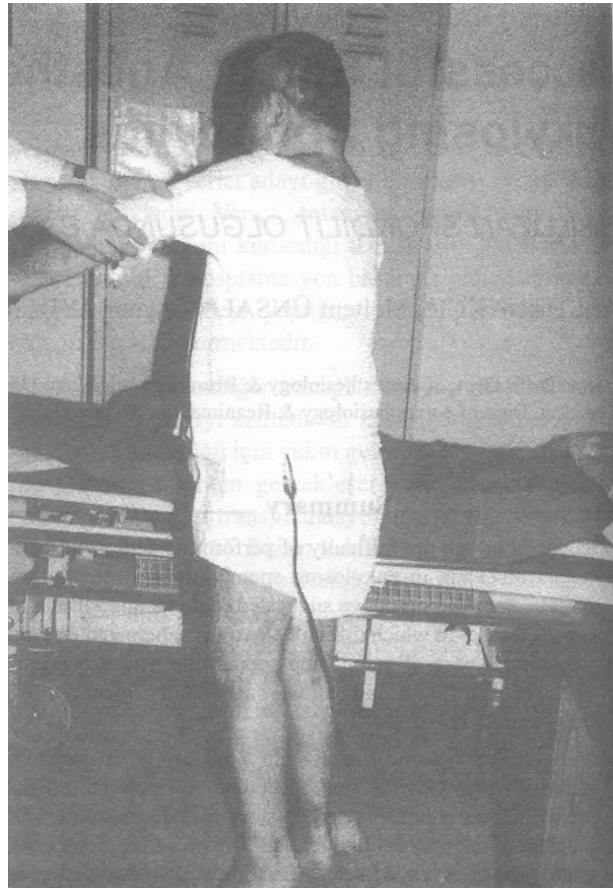
A 45-year-old man who had an 18 month-history of left inguinal mass and pain was admitted for left inguinal hernia repair. He had a 20-year history of ankylosing spondylitis. He was treated intermittently according to his symptoms with nonsteroidal anti-inflammatory drugs and steroids for 15 years. He was receiving steroids until eight months before hospital admission.

Nine years before he had a right inguinal hernia repair first attempted under general anaesthesia, but was postponed due to unsuccessful endotracheal intubation, later performed with regional anaesthesia by peripheral nerve block.

The patient complained of experiencing pain during his first operation therefore he did not consent his operation to be performed under local anaesthesia. Considering his previous history of unsuccessful intubation, spinal anaesthesia was chosen as the anaesthetic technique. He had a 5-years history of peptic ulcer.



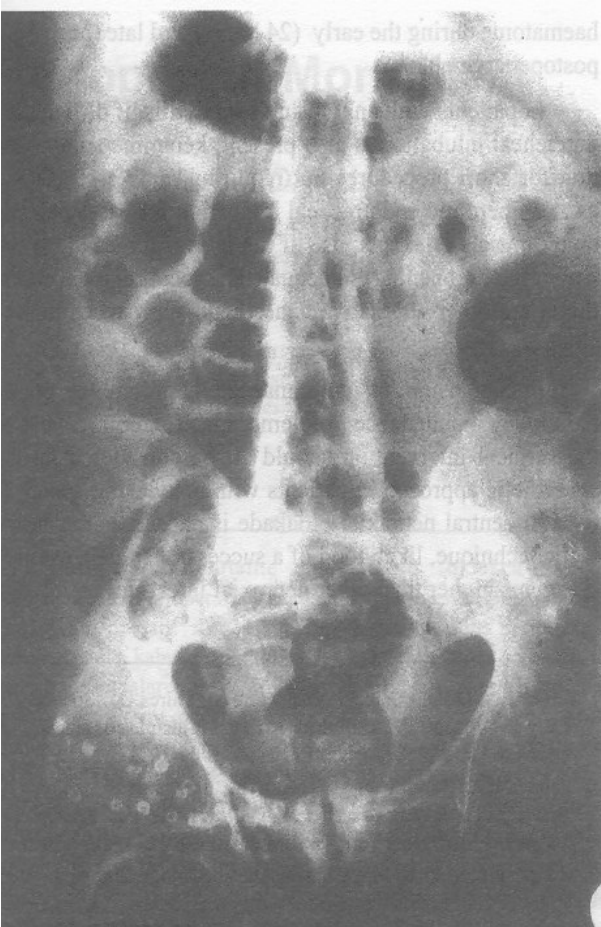
**Figure 1.** Cushingoid appearance of the patient with ankylosing spondylitis.



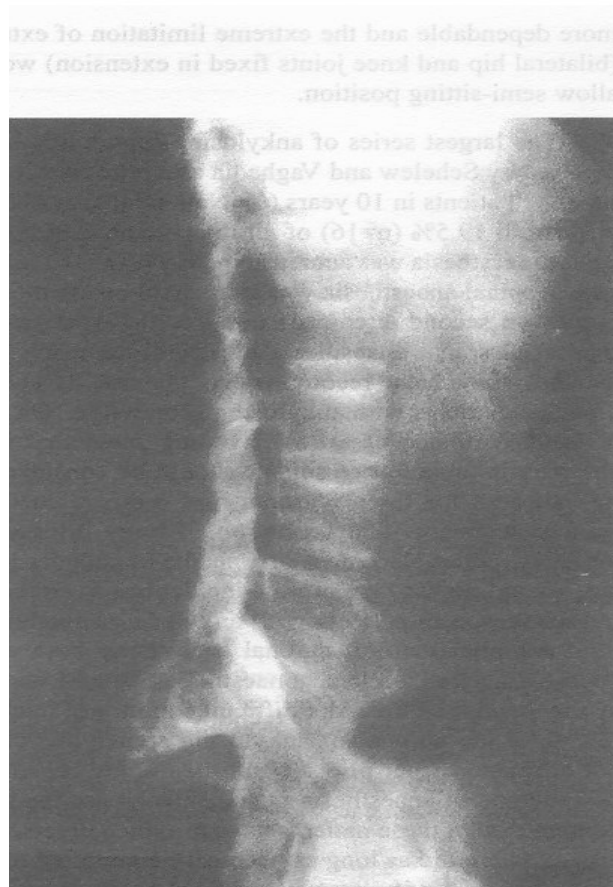
**Figure 2.** Physical appearance of the patient from profile, note that he can only stand up with support on his toes.

The patient weighed 60 kg and his height was 155 cm. He had a cushingoid appearance (Fig 1 and 2). All vertebral joints (cervical, thoracic, lumbar) lacked motion, bilateral hip and knee joints were fixed in extension, and bilateral ankle joints were fixed in plantar flexion. Bilateral shoulder motion was limited to scapular motion, elbow flexion-extension was limited to 20° and wrist joints were fixed in neutral. He could open his mouth only 4 cm, his physical examination revealed a Grade IV Mallampati score. He was able to stand with support on his toes and balanced his body by his arms. Otherwise he could not stand up or walk alone.

Anteroposterior and lateral radiographs of the lumbar spines reveal extensive ossification and ankylosis (Fig 3, 4). Preoperative laboratory data including his within normal limits. The coagulation profile was; prothrombin time (PT) 13 seconds, activated partial thromboplastin time (aPTT) 28 seconds and INR value 0.9. The patient was premedicated with atropine 0.5 mg and pethidine HCl 25 mg im. 30 minutes before the planned operation. In the operation room ECG, non-invasive blood pressure and peripheral oxygen saturation were monitored and an intravenous infusion of Lactated Ringer solution was started. Intrathecal anaesthesia was planned, but since the patient was a candidate for difficult endotracheal intubation and airway man-



**Figure 3.** Anteroposterior radiograph of the lumbar spines show extensive ossification and ankylosis.



**Figure 4.** Lateral radiograph of the lumbar spines.

agement devices for emergent use including fiberoptic bronchoscope system and a percutaneous tracheostomy set were kept ready. With the patient in the left lateral position, 22 gauge Quincke-Babcock spinal needle was inserted between lumbar 3-4 intervertebral space by median technique. The first attempt was unsuccessful, the needle was repositioned and free flow of cerebrospinal fluid was obtained by the median technique at the same level on the second attempt. 2.5 mL of heavy bupivacaine 0.5% was administered and the patient was kept in the left lateral position for 10 min. When the sensorial level of blockade reached T-10, he was placed supine and the operation table was brought to a 30° head up tilt. He was sedated with midazolam 2 mg and fentanyl 50µg iv. Total duration of the operation was 90 min. and the patient recovered without any complication. He was visited on postoperative day one and afterwards controlled through telephone contact, at both interviews no additional complication was noted.

### Discussion

Ankylosing spondylitis is an often self-limiting disease with unknown aetiology. The disease prevalence varies

with the presence of HLA-B27 affecting predominantly young males, usually beginning between 14 and 35 years of age (3-5).

Most cases have a restrictive ventilatory defect which is progressive, caused by fusion and loss of movement at intervertebral and vertebrocostal joints. Eventually ventilation becomes totally dependent on diaphragmatic function. This may result in increased intraabdominal pressure and inguinal hernia occurs more commonly (5). In the presented case first right inguinal hernia and 8 years afterwards left inguinal hernia has occurred.

In this patient cervical spine was fixed resulting in an unsuccessful endotracheal intubation attempt. In the patients with a fixed cervical spine it has been reported that it is usually not possible to see any part of the laryngeal inlet, emphasizing the intubation problem (5). This is the most significant lesion for the anaesthetist concerned with the management of the airway. A small group of patients with advanced disease and complete ankylosis have an increased risk of sustaining a cervical fracture (4, 5).

In this patient heavy bupivacaine was preferred to isobaric bupivacaine since the control of spinal block level is

more dependable and the extreme limitation of extremities (bilateral hip and knee joints fixed in extension) would not allow semi-sitting position.

The largest series of ankylosing spondylitis has been reported by Schelew and Vaghadia as a retrospective analysis of 82 patients in 10 years (6). Neuraxial anaesthesia was planned in 19.5% (n=16) of all the patients and successful spinal anaesthesia was achieved in 76.2% (n=10) (6). In this patient spinal anaesthesia was successful by the median approach on second attempt. Kumar et al (7) have reported successful spinal anaesthesia by lateral approach in three patients; they have recommended the use of lateral approach in patients with ankylosing spondylitis. On the other hand Wittmann et al (5) have suggested that regional anaesthesia (epidural or spinal) should be considered contra-indicated for three reasons, first ossification of interspinous ligaments and formation of bony bridges would probably render placement of a needle or catheter impossible, second higher than normal incidence of vertebral fracture incidence in patients with ankylosing spondylitis and third complications of regional anaesthesia such as intravenous injection of local anaesthetics should necessitate airway manipulation under difficult conditions. In our opinion, since the number of ankylosing spondylitis cases are not adequate to perform a controlled study regarding the best method of anaesthesia management, case reports concerning care of these patients have provided diverse experiences. Therefore as long as necessary equipment for emergent airway management is provided and regional anaesthetic techniques are used with enough care and attention to prevent complications type of the operation and patient willingness are the determining factors for regional anaesthesia in patients with ankylosing spondylitis.

In our review of current literature we have not encountered any reports on successful lumbar or thoracic epidural anaesthesia. Only caudal approach for epidural anaesthesia has been reported in a limited number of patients with ankylosing spondylitis (5). Ankylosing spondylitis has been identified as a risk factor for spinal haematoma formation (9), therefore the patient was followed up for signs and symptoms of a developing spinal

haematoma during the early (24 hours) and late (one week) postoperative phase.

In patients with ankylosing spondylitis, if difficult endotracheal intubation is also present, ketamine administration for short procedures not requiring muscle relaxation, awake fiberoptic endotracheal intubation for cases necessitating muscle relaxants, use of the laryngeal mask (10) airway if mouth opening is adequate and local regional anaesthesia are other alternative anaesthetic approaches to suitable cases.

In conclusion, patient's anaesthetic preference, potential airway maintenance problems, specific requirements of the surgical intervention should all be considered for the anaesthetic approach in patients with ankylosing spondylitis. If a central neuraxial blockade is chosen as the anaesthetic technique, likelihood of a successful spinal anaesthesia seems higher than other neuraxial interventions.

#### REFERENCES

1. Rosier RN, Orthopaedics. In: Schwartz SI, Shires GT, Spencer FC, Daly JM, Fischer JE, Galloway AC eds. Principles of surgery, 7th ed. New York, McGraw Hill Ltd 1999; 1909-2022.
2. Peimer CA, Surgery of the hand. In: Schwartz SI, Shires GT, Spencer FC, Daly JM, Fischer JE, Galloway AC eds. Principles of surgery, 7th ed. New York, McGraw Hill Ltd 1999; 2023-2090.
3. Morgan GE, Mikhail MS, Clinical Anesthesiology, 2nd ed. London, Prentice Hall International Limited, 1996:313-314.
4. Sinclair JR, Mason RA, Ankylosing spondylitis: The case for awake intubation, *Anaesthesia*, 1984;39:3-11.
5. Wittman FW, Ring PA, Anaesthesia for hip replacement in ankylosing spondylitis, *Journal of the Royal Society of Medicine*, 1986;79:457-459.
6. Schelew BL, Vaghadia H, Ankylosing spondylitis and neuraxial anaesthesia: A 10 year review. *Can J Anaesth*, 1996;43:65-68.
7. Kumar CM, Mehta M, Ankylosing spondylitis: lateral approach to spinal anaesthesia for lower limb surgery. *Can J Anaesth*, 1995;42:73-76.
8. Deboard JW, Ghia JN, Guilford WB, Caudal anesthesia in a patient with ankylosing spondylitis for hip surgery, *Anesthesiology*, 1981;54:164-166.
9. Hinnerk W, Epidural anaesthesia and spinal haematoma, *Can J Anaesth*, 1996;43:1260-1271.
10. Defalque RJ, Hyder ML. Laryngeal mask airway in severe cervical ankylosis. *Can J Anaesth* 1997;44:305-7.