

## CASE REPORT

DOI: 10.5336/caserep.2020-78056

# Delayed Diagnosis of Spontaneous Intraperitoneal Rupture of Hydatid Cyst of the Liver

<sup>1</sup>Saliha KARAGÖZ EREN<sup>a</sup>, <sup>2</sup>Baki TAŞTAN<sup>a</sup>, <sup>3</sup>Ömer TOPUZ<sup>a</sup>, <sup>4</sup>Tamer ERTAN<sup>a</sup>

<sup>a</sup>Clinic of General Surgery, Kayseri City Training and Research Hospital, Kayseri, TURKEY

**ABSTRACT** Intra-biliary rupture is the most common complication of liver hydatid cysts, intraperitoneal rupture is rarely seen, but it can be life-threatening. A 57-year-old female patient complained of abdominal pain and a hydatid cyst was found in the left liver lobe, as well as an intra-abdominal cystic mass due to intraperitoneal rupture. The patient's medical history showed that she was admitted to the emergency department with complaints of abdominal pain two months earlier, the liver hydatid cyst and intra-abdominal fluid were detected. However, there were no acute abdominal findings, so no emergency intervention was done. She was operated on electively. Surgical exploration showed a ruptured hydatid cyst of the left liver lobe, with a cystic mass that limited itself perfectly in the peritoneal cavity. Especially in endemic regions, primary care and emergency physicians should consider ruptured disease for patients with abdominal pain and liver hydatid cyst. The aim of this article, in light of the literature, is to emphasize that the rupture of hydatid cysts may not represent catastrophic clinical signs.

**Keywords:** Hydatid cyst; hepatic; spontaneous rupture; delayed diagnosis

Human hydatid cyst disease presents most frequently with *Echinococcus granulosus*, and less frequently with *Echinococcus multilocularis*. The worldwide incidence rate falls between 1 and 200 cases within a population of 100,000. Endemic regions are Mediterranean coastal areas (Turkey, Greece, Cyprus, Spain, Russia, China, and Australia).<sup>1</sup> The liver is the most commonly affected organ in 65-70% (right hepatic lobe is affected in 80% of cases and the left lobe in 20%). The lungs (15%), spleen, peritoneum, kidneys, and brain are less often affected.<sup>2</sup>

Hydatid cyst disease tends to be asymptomatic, and many are found incidentally with clinical or radiological findings. However, most symptomatic hydatid cysts are complicated by rupture or secondary bacterial contamination. Sometimes they cause right upper abdominal pain, bloating, and discomfort due to their large dimensions.<sup>3</sup>

Hepatic hydatid cysts rupture most often in the biliary tract, but they can also rupture in blood vessels, bronchi, or the peritoneal cavity. A spontaneous intraperitoneal rupture of the hydatid cyst is a rarely seen condition, which is accompanied by serious morbidity and mortality.<sup>4</sup> Patients with a hydatid cyst rupture in the peritoneal cavity usually visit emergency services with acute abdominal signs. Diagnosis is made by ultrasonography (US) and computerized tomography (CT).

In this article, we aimed to present a patient who was evaluated in an emergency outpatient clinic with the complaint of abdominal pain and diagnosed with spontaneous intraperitoneal rupture of a liver hydatid cyst two months later.

## CASE REPORT

Our 57-year-old female patient had abdominal pain, epigastric fullness, and a minimal tenderness in the

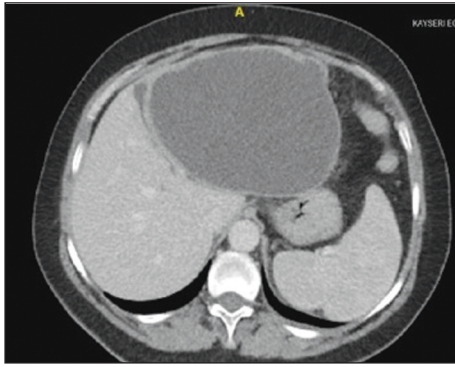
**Correspondence:** Saliha KARAGÖZ EREN  
Clinic of General Surgery, Kayseri City Training And Research Hospital, Kayseri, TURKEY  
**E-mail:** salihakaragozeren@hotmail.com



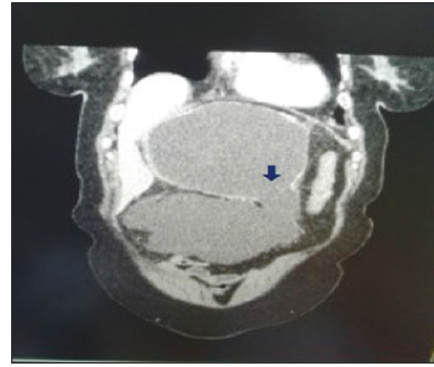
Peer review under responsibility of Türkiye Klinikleri Journal of Case Reports.

**Received:** 12 Jul 2020 **Accepted:** 20 Aug 2020 **Available online:** 31 Dec 2020

2147-9291 / Copyright © 2021 by Türkiye Klinikleri. This is an open access article under the CC BY-NC-ND license (<http://creativecommons.org/licenses/by-nc-nd/4.0/>).



**FIGURE 1:** Abdominal computerized tomography scan shows a cystic mass that replaced the entire left lobe of the liver.



**FIGURE 2:** The perforated cystic lesion in the liver relates to intra-abdominal locule liquid; blue arrow shows loss of integrity of the capsules.

right upper quadrant, which was revealed at the Kayseri Training and Research Hospital. Informed consent was obtained from the patient. The patient's medical history showed that she was admitted to the emergency department with complaints of abdominal pain two months earlier; a cyst of the liver was found, so general surgery was recommended to control her. The abdominal US revealed a type 3 hydatid cyst that included a large number of daughter vesicles in the left lobe and measured 16 cm. In addition, the intraabdominal cystic mass was observed extended from the left lobe to the umbilical region with a total size of 200x105 cm. It had condensed content, and a semisolid appearance was observed. CT revealed a cystic mass with a size of 16x14 x12 cm in the lower section of the left lobe (Figure 1), and the cystic mass showed a loss of integrity of approximately 32 mm of capsules (suspected ruptured hydatid liver cyst). CT also detected localized abdominal fluid collection along with a size of 2 x10 cm and continuity within the cystic mass (Figure 2). WBC: 7.58/mm<sup>3</sup>, Hb: 10.7 g/dL, PLT: 186,000 mm<sup>3</sup>, albumin was less than normal (2.9 g/dL) while other routine biochemical parameters were normal.

A retrospective assessment of the patient's emergency visit two months earlier showed no trauma, prior surgery, or systemic disease in medical history. Blood pressure, heart rate, and body temperature were 120/70 mmHg, 85 beats/min and 37.2 °C, respectively. Laboratory findings revealed the following White blood cell (WBC): 8.62/mm<sup>3</sup>, hemoglobin (Hb): 14.1g/dL, and platelet (PLT): 118,000 mm<sup>3</sup>, glucose (GLU): 156 mg/dL, and alkaline phosphatase

(ALP): 190U/L were slightly higher, while other biochemical parameters were normal. Abdominal USG revealed a cystic lesion measuring approximately 14 cm in the left lobe of the liver, a stone of 18 mm in the gallbladder, a stone of 10 mm in the right kidney, as well as liquid in the perihepatic and pelvic area. The patient did not have acute abdominal symptoms on examination, and laboratory parameters were normal; because the patient's complaints were not considered to be associated with the cyst, medical treatment was given to the patient, as general surgery and urology outpatient clinic control were recommended.

Albendazole treatment was started (10 mg/kg/day) and endoscopic retrograde cholangiopancreatography (ERCP) was performed before the operation because of slightly elevated ALP level and considering the cysts could be close to the bile ducts due to large size. ERCP detected a communication between the cyst and the biliary tract, and sphincterotomy was performed, and 8.5 F plastic stent was placed in the common bile duct.

The patient underwent elective surgery, and exploration was made with a midline incision. With greater exploration, we observed an approximately 14 cm thick-walled cystic mass replaced the entire left lobe of the liver with about a 20x15 cm cystic mass (due to hydatid cyst rupture pushing the transverse mesocolon downwards). Cystotomy was performed after packing the surrounding area with hypertonic saline-soaked sponges, and the cyst content was aspirated with a closed system aspirator, which was found to be infected and bilious. As such, 3% saline solution was used in the cyst, and the two

cysts were observed to be related to each other. Partial cystectomy was done for the hydatid cyst and total cystectomy for the secondary cyst. Cholecystectomy was performed for a gallbladder stone; in addition, the distal part of the common bile duct was closed and the isotonic saline was given from the cystic duct. We observed two bile ducts in the cyst, which were closed with non-absorbable suture. The patient was discharged on the fourth postoperative day without any complications and had albendazole treatment for three months. There was no recurrence or any pathological signs seen in the CT controls performed at 6 and 12 months.

## DISCUSSION

Hydatid cysts of the liver can stay silent for years and are frequently detected incidentally on the US performed for other reasons. Symptoms are usually caused by pressure and complications arisen by cyst growth.<sup>4,5</sup> Liver hydatid cyst complications occur rarely, and have two main categories; they tend to rupture with secondary bacterial infection.<sup>6</sup> Intrahepatic rupture is the most common complication of a hydatid cyst of the liver (5-25%), and intraperitoneal rupture of a cyst is seen in 3.2-16% of the cases.<sup>6,7</sup> The intraperitoneal rupture rate in our country is reported as 7.8%.<sup>8</sup> Rupture of the hydatid cyst in the abdominal cavity is a rare complication and can cause anaphylaxis and life-threatening complications; this should be considered in the diagnosis of acute abdominal symptoms in endemic regions.<sup>9</sup> A separated membrane and intra-abdominal fluid are seen in US, although a CT scan can help with the diagnosis. Specific treatment in patients with peritoneal perforation has not been adequately evaluated, as there is not a clear guide on this subject.

Hydatid cyst rupture requires emergency surgery; however, the best approach is not precisely defined.<sup>10</sup> Surgical methods (percystectomy, hepatic resection) and conservative techniques (unroofing associated with various procedures for the management of the residual cavity process) are treatments for hydatid cysts. All of the cyst's content must be removed, as the cyst and peritoneal space are cleaned with scolicidal agents.

Intraperitoneal perforation may not have been considered with the first emergency admission as the patient's vital signs were stable, without acute abdominal findings, laboratory parameters were normal, and there was no identification of cyst perforation via the US. The patient had not gone to any hospital during two months period and had no other complaints other than minimal epigastric pain. On the other hand, it was seen that the patient had hydatid cyst rupture with both radiological and operative findings, and limited itself perfectly.

Most frequently, the rupture of a hydatid cyst into the peritoneal cavity is symptomatic. In a case report by Bari et al., they presented a patient who has a trauma history three years ago, with peritoneal echinococcosis presenting as massive abdominal distention, acid, and respiratory distress.<sup>11</sup> Majbar et al. reported a case who presented with pain and mass in the abdomen for four months, and US and CT examinations showed a multilocular liver cyst and multiple unilocular cysts in the abdomen.<sup>12</sup> Surgical treatment was performed after 4 weeks from CT scanning. As in our case, the patient's examination and laboratory results were not considered as perforation.

Spontaneous rupture may be associated with a cyst diameter approaching 15 cm in the patient without a history of trauma. Although there are both intrahepatic rupture and spontaneous intraperitoneal rupture, the clinical findings of the patient are vague (without allergy, cholangitis, peritonitis, etc.). This condition may be associated with a very good limitation of the bile hydatid content leaking into the peritoneal cavity. As shown in our case, results may not always be satisfactory. The right diagnosis in surgical practice starts with thinking about the diagnosis. In particular, patients with intra-abdominal fluid with liver hydatid cyst should be subjected to more rigorous evaluation. Early intervention will reduce peritoneal contamination and the likelihood of recurrence.

### Source of Finance

*During this study, no financial or spiritual support was received neither from any pharmaceutical company that has a direct connection with the research subject, nor from a company that provides or produces medical instruments and materials which may negatively affect the evaluation process of this study.*

**Conflict of Interest**

No conflicts of interest between the authors and / or family members of the scientific and medical committee members or members of the potential conflicts of interest, counseling, expertise, working conditions, share holding and similar situations in any firm.

**Authorship Contributions**

**Idea/Concept:** Baki Taştan; **Design:** Baki Taştan, Saliha Karagöz Eren; **Control/Supervision:** Tamer Ertan, Ömer Topuz; **Literature Review:** Baki Taştan; **Writing the Article:** Saliha Karagöz Eren, Baki Taştan; **Critical Review:** Tamer Ertan, Ömer Topuz.

**REFERENCES**

1. Nunnari G, Pinzone MR, Gruttadauria S, Cellesia BM, Madeddu G, Malaguamera G, et al. Hepatic echinococcosis: clinical and therapeutic aspects. *World J Gastroenterol.* 2012;7;18(13):1448-58. [[Crossref](#)] [[PubMed](#)] [[PMC](#)]
2. Beggs I. The radiology of hydatid disease. *AJR Am J Roentgenol.* 1985;145(3):639-48. [[Crossref](#)] [[PubMed](#)]
3. Alexiou K, Mitsos S, Fotopoulos A, Karanikas I, Tavernarakis K, Konstantinidis F, et al. Complications of hydatid cysts of the liver: spiral computed tomography findings. *Gastroenterology Res.* 2012;5(4):139-43. [[PubMed](#)] [[PMC](#)]
4. Arikanoglu Z, Taskesen F, Aliosmanoğlu İ, Gul M, Cetincakmak MG, Onder A, et al. Spontaneous intraperitoneal rupture of a hepatic hydatid cyst. *Int Surg.* 2012;97(3):245-8. [[Crossref](#)] [[PubMed](#)] [[PMC](#)]
5. Karakaya K. Spontaneous rupture of a hepatic hydatid cyst into the peritoneum causing only mild abdominal pain: a case report. *World J Gastroenterol.* 2007;7;13(5):806-8. [[Crossref](#)] [[PubMed](#)] [[PMC](#)]
6. Ray S, Das K. Spontaneous intraperitoneal rupture of hepatic hydatid cyst with biliary peritonitis: a case report. *Cases J.* 2009;11;2: 6511. [[Crossref](#)] [[PubMed](#)] [[PMC](#)]
7. Gulalp B, Koseoglu Z, Toprak N, Satar S, Sebe A, Gokel Y, et al. Ruptured hydatid cyst following minimal trauma and few signs on presentation. *Neth J Med.* 2007;65(3):117-8. [[PubMed](#)]
8. Akcan A, Akyildiz H, Artis T, Ozturk A, Deneme MA, Ok E, et al. Peritoneal perforation of liver hydatid cysts: clinical presentation, predisposing factors, and surgical outcome. *World J Surg.* 2007;31(6):1284-91. [[Crossref](#)] [[PubMed](#)]
9. Mouaqit O, Hibatallah A, Oussaden A, Maazaz K, Taleb KA. Acute intraperitoneal rupture of hydatid cysts: a surgical experience with 14 cases. *World J Emerg Surg.* 2013;26;8:28. [[Crossref](#)] [[PubMed](#)] [[PMC](#)]
10. Dziri C, Haouet K, Fingerhut A. Treatment of hydatid cyst of the liver: where is the evidence? *World J Surg.* 2004;28(8):731-6. [[Crossref](#)] [[PubMed](#)]
11. Bari S, Malik AA, Parray FQ, Samoon H, Munfat M, Bakshi IH, et al. Delayed diagnosis of traumatic rupture of hydatid cyst of the liver--a case report. *Int J Surg.* 2008;6(6):e18-9. [[Crossref](#)] [[PubMed](#)]
12. Majbar AM, Aalala M, Elalaoui M, Sabbah F, Raiss M, Hrora A, et al. Asymptomatic intraperitoneal rupture of hydatid cyst of the liver: case report. *BMC Res Notes.* 2014;26;7:114. [[Crossref](#)] [[PubMed](#)] [[PMC](#)]