

Osteosarcoma of the Clavicle and Scapula Secondary To the Radiotherapy for Servical Metastases of the Differentiated Thyroid Cancer: Case Report

Diferansiye Tiroid Kanserinin Servikal Metastazına Radyoterapi Uygulamasına Sekonder Gelişen Klavikula ve Skapula Osteosarkomu

Savaş KARYAĞAR, MD,^a
Mehmet MULAZIMOĞLU, MD,^a
Sevda SAĞLAMPINAR KARYAĞAR, MD,^a
Ercan UYANIK, MD,^a
Tevfik ÖZPAÇACI, MD^a

^aDepartment of Nuclear Medicine,
Okmeydanı Training and Research Hos-
pital, İstanbul

Geliş Tarihi/Received: 23.06.2008
Kabul Tarihi/Accepted: 02.09.2008

Yazışma Adresi/Correspondence:
Savaş KARYAĞAR, MD
Okmeydanı Training and
Research Hospital, Department
of Nuclear Medicine, İstanbul,
TÜRKİYE/TURKEY
skaryagar@yahoo.com

ABSTRACT A 67-year-old woman previously diagnosed with differentiated thyroid cancer (DTC) was transferred to our clinic with complaints of swelling, pain, stiffness of the left supraclavicular region and left shoulder. She had undergone radiotherapy for DTC servical lymph node metastases fourteen years ago. Diagnostic I-131 whole body scan showed increased uptake in thyroid region without any uptake compatible with metastases. Three phase bone scan showed intense uptake within the expansive mass in the region of the left clavicle and left shoulder in all three phases. Histopathological revealed osteosarcoma of the left clavicle. Osteosarcoma of the clavicle and scapula following radiotherapy for DTC is rare condition. Diagnostic I-131 whole body scan and three phase bone scan are useful for diagnosis of radiation induced osteosarcoma in DTC patients.

Key Words: Thyroid neoplasms; osteosarcoma; radiotherapy

ÖZET Diferansiye tiroid kanseri tanılı 67 yaşındaki bayan hasta sol supraklaviküler bölgede ve omuzda şişlik, ağrı ve hareket kısıtlılığı şikayetleri ile kliniğimize başvurdu. Hastaya 14 yıl önce DTC servikal lenf nodu metastazı nedeniyle radyoterapi uygulanmış idi. I-131 tüm vücut sintigrafisinde tiroid lojunda artmış tutulum izlendi. Üç fazlı kemik sintigrafisinde sol klavikula ve omuzda yoğun aktivite tutulumu izlendi. Sol klavikuladan yapılan histopatolojik analizde osteosarkom saptandı. DTK hastalarında radyoterapiye sekonder osteosarkom gelişimi nadir bir durumdur. I-131 tüm vücut tarama sintigrafisi ve üç fazlı kemik sintigrafisi DTK hastalarında radyoterapiye bağlı gelişen osteosarkom tanısında faydalı metodlardır.

Anahtar Kelimeler: Tiroid neoplazileri; osteosarkom; radyoterapi

Türkiye Klinikleri J Med Sci 2010;30(1):413-5

The role of radiotherapy (RT) for the differentiated thyroid cancer (DTC) still remains controversial although it has been used in patients with DTC in case of postoperative residual disease, local recurrence, or when cancer is refractory to radioiodine treatment.¹⁻⁶ Approximately 5 % of sarcomas develop after therapeutic or accidental irradiation.⁷ In osteosarcomas, three-phase bone scintigraphy is often used to evaluate the primary lesion and to search for bone metastases. In this paper, we present a radiation induced osteosarcoma of the clavicle and scapula in a DTC patient in whom three-phase bone scan and I-131 radioiodine scan are used for diagnosis.

CASE REPORT

A 67-year-old woman previously diagnosed as DTC was transferred to our clinic with swelling, pain, and stiffness of left supraclavicular region and

left shoulder. Fourteen years ago, she underwent thyroidectomy and left modified neck dissection. After surgery, she had radioiodine treatment with 150 mCi I-131. She was administered RT to thyroid region and left servical area (5000 cGy on 25 fraction) due to extrathyroidal soft tissue invasion of the DTC and lymph node metastases with capsular invasion in the left inferior jugular chain. Patient was lost from follow up and did not use thyroid hormone pills properly. The serum TSH level was 56 uIU/mL (normal range 0,34-5,6 uIU/mL), thyroglobulin 229 ng/mL (normal range 1,15-35 ng/mL) and antithyroglobulin <20 IU/mL (normal range 2,2-4,9 IU/mL). The PA chest X-ray revealed an increase in density with expansion, lysis and sclerosis in the left clavicle and medial region of the left scapula (Figure 1). Three phase bone scan was performed after the administration of 20 mCi Tc-99m methylene diphosphonate (MDP). In the planar anterior imaging, the early arterial flow phase revealed increased perfusion and blood pool phase revealed intense radiopharmaceutical uptake in the left clavicle, upper edge of the left scapula, left supraclavicular region and left shoulder (Figure 2). Anterior and posterior whole-body bone imaging showed intense radiopharmaceutical uptake within the expansive mass in the region of the left clavicle, upper edge of the left scapula and left shoulder (Figure 3). Anterior I-131 whole body im-

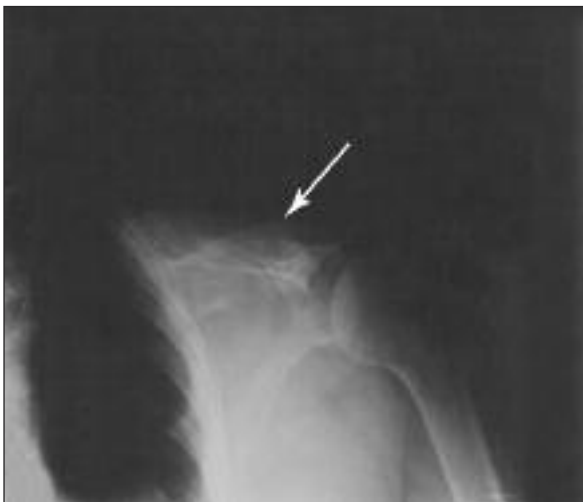

FIGURE 1: The PA chest x-ray revealed an increase in density with expansion, lysis and sclerosis in the left clavicle and medial region of the left scapula.

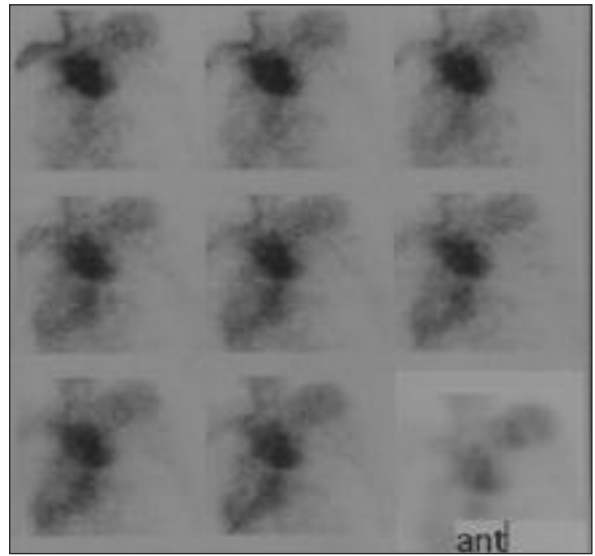


FIGURE 2: Early arterial flow phase and blood pool phase of the three phase bone scan. In the planar anterior imaging, the early arterial flow phase revealed increased perfusion and blood pool phase revealed intense radiopharmaceutical uptake in the left clavicle, upper edge of the left scapula, left supraclavicular region and left shoulder.

aging three days after the administration 10 mCi I-131 showed increased uptake in thyroid region without any uptake compatible with metastases (Figure 4). Histopathology of the left clavicle revealed osteosarcoma.

DISCUSSION

The role of RT in the treatment of DTC is controversial. RT is indicated in DTC following initial thyroidectomy when the surgical specimen demonstrates a positive margin, invasion of normal tissues, a metastatic lymph node > 2 cm, or nodal metastases with extensive extracapsular tumor extension.³ Several series also noted that older patients (> 40 years of age) with multiple positive lymph nodes or extrathyroidal extension had better locoregional control when radiotherapy was added to treatment regimen.^{1,4,5}

Bone scan in osteosarcoma is useful for delineating the extent of the primary lesion and for early detection of local recurrence and metastatic disease. Bone scan in patients with osteosarcoma typically reveals a well defined region of intense radiopharmaceutical uptake.

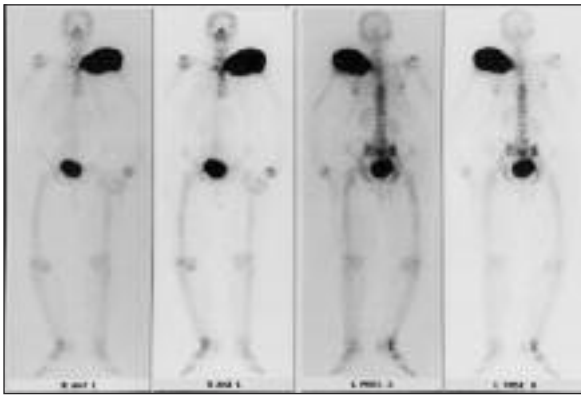


FIGURE 3: Delayed phase of the three phase bone scan. In the anterior and posterior whole body imaging, the delayed phase showed intense radiopharmaceutical uptake within the expansive mass in the region of the left clavicle, upper edge of the left scapula and left shoulder.

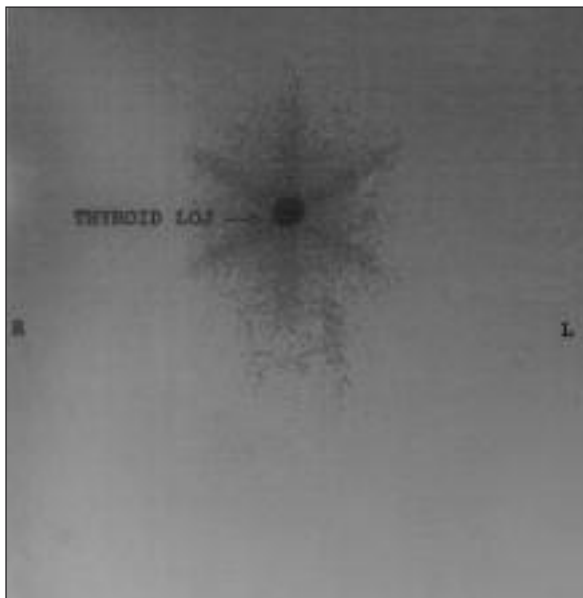


FIGURE 4: Anterior I-131 whole body imaging three days after the administration 10 mCi I-131 showed increased uptake in thyroid region without any uptake compatible with metastases.

Radiation-induced sarcomas are uncommon, occurring in approximately 0.035 % of all patients receiving radiotherapy.⁸ A relationship was found between I-131 administration and occurrence of bone and soft tissue, colorectal, and salivary gland cancers.⁹

As for osteosarcomas, Huvos et al estimated that approximately 5 % of sarcomas developed after therapeutic or accidental irradiation.⁷ Cahan et al defined the criteria for post-radiation bone sarcoma as follows: (a) histological or radiological proof that there was no previous tumour in the involved bone; (b) development of sarcoma in an irradiated area; (c) a sufficiently long interval between irradiation and the development of sarcoma; and (d) histological proof of sarcoma.¹⁰ These criteria were modified by Arlen et al for post-irradiation sarcoma of the bone, “the tumours developed in bone not known to have a primary malignant osteoblastic lesion when the radiotherapy was given”.¹¹ Our case fulfills these criteria. The majority of these tumors have been found in the skull, scapula, sternum, ribs, and pelvis.¹² This distribution reflects the frequency of use of radiotherapy for retinoblastoma, nasopharyngeal carcinoma, Hodgkin lymphoma, and for breast, uterine, and cervical carcinoma.¹³

In our knowledge, osteosarcoma is rare condition in patient that undergone RT for DTC metastases. Three phase bone scintigraphy is beneficial for determination of bone lesions while I-131 is beneficial for distinguishing between the bone metastases of DTC and a primary bone lesion.

REFERENCES

- Lin JD, Tsang NM, Huang MJ, Weng HF. Results of external beam radiotherapy in patients with well differentiated thyroid carcinoma. *Jpn J Clin Oncol* 1997;27(4):244-7.
- Chung CT, Sagerman RH, Ryoo MC, King GA, Yu WS, Dalal PS, et al. External irradiation for malignant thyroid tumors. *Radiology* 1980;136(3):753-6.
- Chow SM, Yau S, Kwan CK, Poon PC, Law SC. Local and regional control in patients with papillary thyroid carcinoma: specific indications of external radiotherapy and radioactive iodine according to T and N categories in AJCC 6th ed. *Endocr Relat Cancer* 2006;13(4):1159-72.
- Keum KC, Suh YG, Koom WS, Cho JH, Shim SJ, Lee CG, et al. The role of postoperative external-beam radiotherapy in the management of patients with papillary thyroid cancer invading the trachea. *Int J Radiat Oncol Biol Phys* 2006;65(2):474-80.
- Tsang RW, Brieler JD, Simpson WJ, Panzarella T, Gospodarowicz MK, Sutcliffe SB. The effects of surgery, radioiodine, and external radiation therapy on the clinical outcome of patients with differentiated thyroid carcinoma. *Cancer* 1998;82(2):375-88.
- Altınbaş M, Barışta İ, Alkış N. [The distribution of the thyroid cancers- Ankara Oncology Hospital results]. *Turkiye Klinikleri J Med Sci* 1997;17(2):120-4.
- Huvos AG, Woodward HQ. Postirradiation sarcomas of bone. *Health Phys* 1988;55(4):631-6.
- Tountas AA, Fornasier VL, Harwood AR, Leung PM. Postirradiation sarcoma of bone: a perspective. *Cancer* 1979;43(1):182-7.
- Rubino C, de Vathaire F, Dottorini ME, Hall P, Schwartz C, Couette JE, et al. Second primary malignancies in thyroid cancer patients. *Br J Cancer* 2003;89(9):1638-44.
- Cahan WG, Woodard HQ, Higinbotham NL, Stewart FW, Coley BL. Sarcoma arising in irradiated bone: report of eleven cases. 1948. *Cancer* 1998;82(1):8-34.
- Arlen M, Higinbotham NL, Huvos AG, Marcove RC, Miller T, Shah IC. Radiation-induced sarcoma of bone. *Cancer* 1971;28(5):1087-99.
- Wasylewski AH, Lohmann J, Fischer M, Müller RP, Edel G. The rare occurrence of a radiation-induced osteosarcoma in the clavicle after treatment of thyroid cancer. *Pathol Res Pract* 1984;178(5):441-5.
- Tonakie A, Shulkin BL, Sisson JC, Yanik GA, Hutchinson RJ. Radiation-induced osteosarcoma and papillary carcinoma of the thyroid. *Clin Nucl Med* 2006;31(1):5-8.