

Pulmonary Synchronous and Gastric Metachronous Carcinoma: Case Report

PULMONER SENKRON, GASTRİK METAKRON KANSER: OLGU SUNUMU

Arif Osman TOKAT*, Ulaş KUMBASAR**, Hakan AKBULUT***, Adem GÜNGÖR****

* Op.Dr., Sağlık Bakanlığı Ankara Eğitim ve Araştırma Hastanesi,
** Dr., Ankara Üniversitesi Tıp Fakültesi Göğüs Cerrahisi AD,
*** Doç.Dr., Ankara Üniversitesi Tıp Fakültesi Medikal Onkoloji BD,
****Prof.Dr., Ankara Üniversitesi Tıp Fakültesi Göğüs Cerrahisi AD, ANKARA

Summary

Introduction: Synchronous tumor is defined as presenting two different tumors at the same time in the same organ. When the second tumor occurs after some time the term metachronous is used.

Case: A 63 year old man admitted to our clinic with a two week history of dyspnea and chest pain. Computerized tomography revealed two masses in the left upper and lower lobes. By the result of the flow cytometric examination, the patient was operated with the diagnosis of pulmonary synchronous carcinoma. 21 months after the therapy, the patient admitted again to the hospital with metachronous gastric adenocarcinoma.

Discussion: It is important to remember in the cases T1-2, N0; the mass which is accepted as pulmonary metastases may be a synchronous tumor.

Key Words: Synchronous carcinoma,
Metachronous carcinoma, Multipl tumor,
Lung cancer

T Klin J Med Sci 2003, 23:407-411

Özet

Amaç: Aynı organda aynı anda iki farklı tümör saptanması senkron tümör olarak adlandırılır. İkinci tümör belli bir zaman sonra ortaya çıkarsa metakron tümör adını alır.

Olgu: Altmış üç yaşındaki erkek olgu 2 haftalık nefes darlığı ve göğüs ağrısı şikayeti ile başvurdu. Tomografik incelemelerinde sol üst ve alt loblarda iki kitle tespit edildi. Kitlelerin flow sitometrik incelemelerine göre olgu senkron akciğer kanseri tanısı ile opere edildi. Olguda 21 ay sonra metakron gastrik adenokarsinom saptandı.

Tartışma: Özellikle T1-2, N0 olgularda pulmoner metastazlar değerlendirilirken senkron tümör olasılığı akılda tutulmalıdır.

Anahtar Kelimeler: Senkron kanser, Metakron kanser,
Multipl tümör, Akciğer Kanseri

T Klin Tıp Bilimleri 2003, 23:407-411

Synchronous tumor is defined as presenting two different tumors at the same time in the same organ. Pulmonary tumors that exist in different lobes of the lung or in different sides at the same time defines pulmonary synchronous tumor (1). If the second tumor occurs after some time the term metachronous is used (2,3).

Synchronous and metachronous tumors are seen very rarely. Although the incidence of synchronous and metachronous lung cancers is not known exactly. Synchronous tumor rate was reported as 0.8–14.5% at many series (4-7). Metachronous cancer is seen 0.5 % of all cancer cases (7,8).

T Klin J Med Sci 2003, 23

Case

The patient was male and 63 years old. He admitted to the clinic with the complaints of dyspnea and chest pain. The patient had a smoking history of one package per day for 30 years. In physical examination, the harshness of the respiration sounds was detected and there were clubbings in the upper extremities. There were two dark shadows in the left lung at the posteroanterior chest-X ray (Figure 1).

In the CT scans two masses were detected with lobulated contours; one in the left upper lobe which was 4x4x5 cm, and the other in the left lower lobe which was 2x2x2 cm dimensions (Figure 2,3).

407

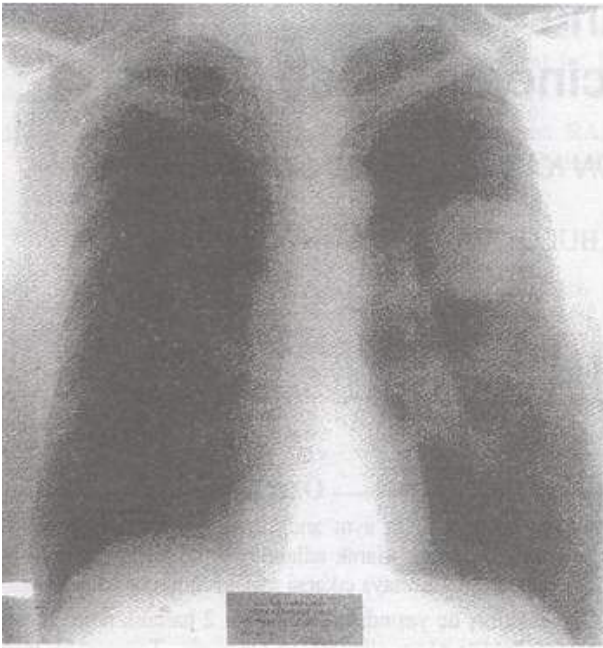


Figure 1. Posteroanterior chest-X ray.

No pathologic LAP was found in the mediastinum. But because of the risk of pulmonary synchronous tumor further diagnostic evaluations were performed. In the respiratory function tests it was found as: FVC: 2.74 L (%65), FEV1: 1.99 L (%61), arterial blood gases examination revealed as: pO_2 : 69.2mmHg, pCO_2 : 37.3mmHg, O_2 saturation was 95.1%. There were two endobronchial masses, one in the left lower basal lobe and the

other in the left upper anterior segment at bronchoscopy. Biopsies were taken from each lesions. The histopathologic examination of these biopsies was reported as squamous cell carcinoma. But because of the clinic and radiologic features further examination were needed. Although each tumor had similar ploidy features, the proliferation index (S phase + G2-M phase) of the left lower lobe material was higher than the other tumor at the flow cytometric examination (Figure 4,5).

No metastasis were found on cranium-abdomen tomography and bone scan examinations. With the diagnosis of pulmonary synchronous tumor left posterolateral incision was performed. At exploration there was a 4x4x5 cm mass in the upper lobe anteriorly which reaches to main bronchi and a second 3x3x3 cm mass located peribronchially in the lower lobe apicoposterior segment. Pneumonectomy and mediastinal lymph node dissection were performed to the case.

In term following pathology the upper lobe mass was reported as adenosquamous carcinoma and the lower lobe mass was reported moderately differentiated squamous cell carcinoma. In addition no tumor cells were found in the surgical borders and 4, 5, 6, 7, 8, 9 and 10 station lymph nodes.

Each tumor was evaluated as in stage I. The upper tumor was T2, N0, M0 and the lower tumor was T1, N0, M0.

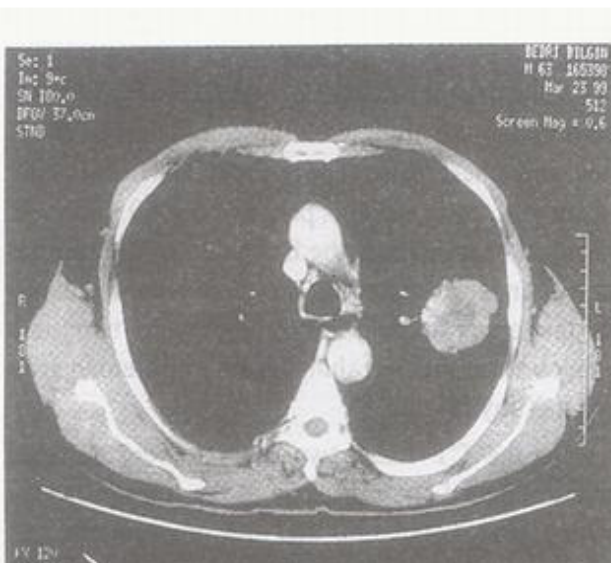


Figure 2. CT of the upper lobe tumor.

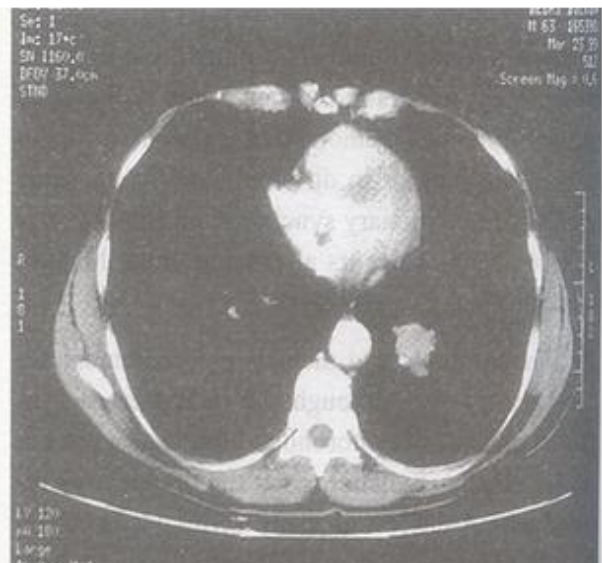


Figure 3. CT of the lower lobe tumor.

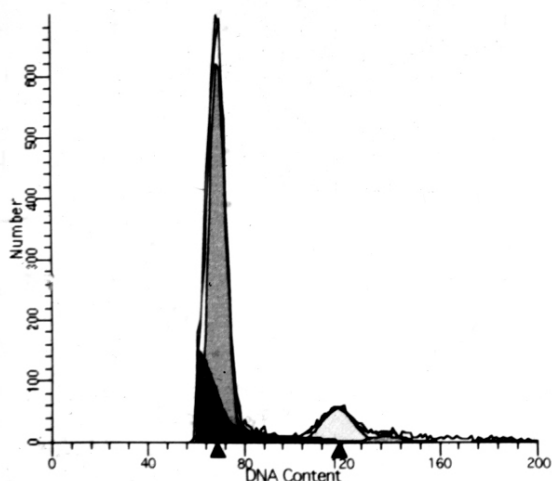


Figure 4. Result of the first tumor's flow cytometric study.

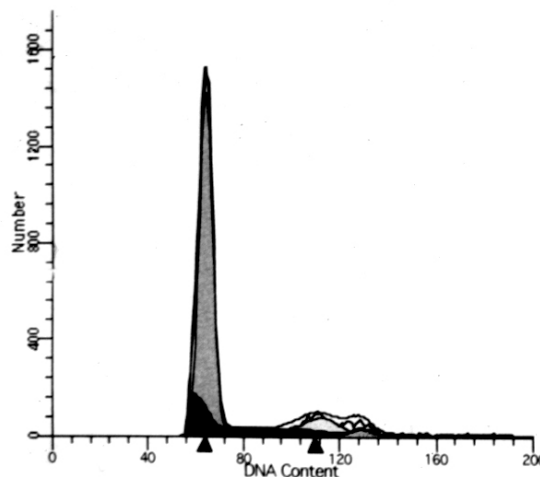


Figure 5. Result of the second tumor's flow cytometric study.

In the postoperative period the patient was taken to the control by intervals of 3 months for the first year and 6 months for the rest. In the follow up, all control CT's were normal until 21th month the control abdominal CT hypodens lesion in the right liver, bilaterally surrenal hyperplasia and multiple paraaortic lymphadenopathies were detected. Biopsy of the lesion was reported as metastasis of adenocarcinoma, and it was thought as a primary tumor originated from stomach. Furthermore primary gastric tumor was seen on endoscopy. Because of the unoperability criteria as liver and surrenal metastases chemotherapy was administered to the patient. After thoracotomy at 28th month without any lung problem the patient died because of the complications of gastric carcinoma.

Discussion

With the help of developing technologies, new horizons appeared in fighting with diseases in all over the world. Like the other causes of the death also the lung cancers as being the cause is investigated. The lung cancer deaths are in the first lines among the cancer deaths in the countries those statistical analyzes are reliable (1,2).

The most important cause is near or distant organ metastasis which increases the grade of case and decrease overall survival time. If there is metastasis, case is accepted as stage IV and it loses

surgery chance with great probabily. However, when a synchronous tumor is the case, there might be tumor occurence in the same lung, in the other lung or another organ. This situation shows that there are two different stage I-II tumors. If this point is missed, there will be no chance of performing surgery for that patient and then the patient should take medical treatment (1,2,9).

If a patient admits to the hospital with more than one mass lesion and if there is enough evidence that the second mass is not a metastatic lesion then we should think the possibility of synchronous tumor. This gives the patient a chance for effective therapy. In such cases, biopsies should be taken from both of the lesions in order to prove that they are synchronous tumors and if there is a necessity, the nature of the lesions should be revealed with the help of flow cytometric methods (10,11). When it is impossible to reach to the lesion with bronchoscopy, evaluation of transthoracically excised tissue might confirm the diagnosis.

Most authors suggested that after the diagnosis the two tumors should be staged separately and for the tumors having larger stages than stage II, surgery should not be performed (4,7,12,13).

In cases that the tumors are localized bilaterally, wedge resection and segmentectomy are the preferred methods while in ipsilaterally lung tu-

mors more radical surgical methods such as pneumonectomy have been performed in many studies (4-6,14).

Overall survival in patient with synchronous lung tumors having complete resection has a wide range in different studies. Five year survival was 6% in Carey (14)'s study while this ratio was 44% in Rosengart (7)'s. However, all cases in every stage were evaluated. In Pompier (6)'s series, stage I and II cases were evaluated and 5 year survival was 38% after complete resection. In this study, 5 year survival was 33% in the tumors with same histologic types while it was 17% in the tumors with different histologic types (6).

The cases in which more than one tumor is detected radiologically, the possibility of a synchronous tumor as well as being metastasis of the primary tumor should always be kept in mind and histopathologic diagnosis should be done in both tumors (15). Complete resection should be done if possible. In the synchronous tumors with lower grade, especially in epidermoid carcinoma cases, early surgical treatment may give survival as long as solitary lung cancer cases (16).

In large series metachronous tumors are seen approximately two times than synchronous tumors (6,9). The risk of developing metachronous tumor increases approximately in the 46th month and later after the first tumor was diagnosed (7,8,17-19).

In our case second tumor was found at 21th month and the histologic features were different from the previous lung tumors. Although the bronchoscopic biopsy results of each tumor were the same, long term pathology prove that each tumor had a different histology. At 21th month control there was no problem about the operation and we thought that surgical treatment was effective.

Genetic investigations especially in recent years showed that it is known that environmental conditions have an influence in the developing of cancer (20). Besides the role of smoking and exposure to environmental hazardous material like asbestosis for cancer development is certain. In this

case in persons who have the same genetic and the same environment, there is a possibility of developing tumor in multiple foci.

With the help of developments in treatment of cancer in the cases with long overall survival time or had cure with the treatment of first cancer, the possibility of finding a second tumor (metachronous tumor) increases. To find out synchronous and metachronous tumors, like larynx and bladder tumor, which are related to tobacco, with the lung cancer is possible. Therefore it is evaluated especially as T and N factor, it is important to remember in the cases T1-2, N0, the mass which is accepted as pulmonary metastases may be a synchronous tumor.

REFERENCES

1. Samuel A. Adebajo, Dennis M. Mortiz and Christopher A. Danby. The results of Modern Surgical Therapy for Multiple Primary Lung Cancers. *Chest* 1997; 112: 693-701.
2. Pairolero PC, Williams DE, Bergstrahl EJ, et al. Postsurgical early I bronchogenic carcinoma: morbid implications of recurrent disease. *Ann Thorac Surg* 1984;38:331.
3. Deschamps C, Pairolero PC, Trastek VF, et al. Multiple primary lung cancers. *J Thorac Cardiovasc Surg* 1990; 99:769.
4. Martini N, Melamed MR. Multiple primary lung cancers. *J Thorac Cardiovasc Surg* 1975; 70:606-12.
5. Adebajo SA, Moritz DM, Danby CA. The results of modern surgical therapy for multiple primary lung cancers. *Chest* 1997; 112: 693-701.
6. Pompier RF, Vetto JT, Lee JT, Johnston KM. Synchronous non-small cell lung cancers. *Am J Surg* 1996; 171: 521-4.
7. Rosengart TK, Martini N, Ghosn P, Burt M. Multiple primary lung carcinomas: prognosis and treatment. *Ann Thorac Surg* 1991; 52: 773-9.
8. Aydiner A, Karadeniz A, Uygun K, Taş Ş, Taş F, Disci R, Topuz E. Multiple primary neoplasms at single institution. *Am J Clin Oncol* 2000; 23(4): 364-70.
9. Kitamura K, Mitsudomi T, Ishida T, Kaneko S, Sugimachi K. Adenocarcinoma and squamous cell carcinoma in the same lobe of the lung. *Respiration* 1991; 58: 226-8.
10. Deschamps C, Pairolero PC, Trastek VF, Payne WS. Multiple primary lung cancer. *J Thorac Cardiovasc Surg* 1990; 99: 769-78.
11. Hida T, Ariyoshi Y, Sugiura T, Suyama M, Takahashi T, Ueda R. Synchronous lung cancer presenting with small cell carcinoma and adenocarcinoma. *Chest* 1993; 104(5): 1602-4.

12. Ferguson MK. Synchrononous primary lung cancers. Chest 1993 103(4 Suppl): 398-400.
 13. Ferguson MK, DeMeester TR, DesLauriers J, Little AG, Piraux M, Golomb H. Diagnosis and management of Synchrononous lung cancers. J Thorac Cardiovasc Surg 1985; 89 (3): 378-85.
 14. Carey FA, Donnely SC, Walker WS, Cameron EWJ, Lamb D. Synchrononous primary lung cancers: Prevalance in surgical material and clinical implications. Thorax 1993; 48: 344-6.
 15. Pierard P, Vermynen P, Bosschaerts T, Roufosse C, Bergmans T, Sculier JP, Ninane V. Synchrononous roentgenographically occult lung carcinoma in patients with resectabl primary lung cancer. Chest 2000; 117: 779-85.
 16. Colomer EJ, Molina JC, Aguilar X, Magarolas M, Mayayo E, Richard C. Synchrononous multiple primary cancer of the lung: A rare association of small cell carcinoma as the main tumor plus epidermoid carcinoma. Arch Bronconeumol 1999; 35(5): 245-7.
 17. Heikkila H, Harjula A, Suolmalainen RJ, Mattila S. Surgical treatment of metachronous primary lung carcinomas. Ann Chir Gynaecol 1985; 74(6): 251-5.
 18. Yoneyama T. Metachoronous bilateral pulmonary resection for primary bronchogenic carcinoma. Nippon Geka Gakkai Zasshi 1984 85(9): 948-51.
 19. Wassmer FA, Racloz Y, Megevand R. Multipl metachoronous lung tumors. Metastases or second primary tumor. Ann Chir 1991; 45(2): 163-6.
 20. Hiroshima K, Toyozaki T, Kohno H, Ohwada H, Fujisawa T. Synchrononous and metachronous lung carcinomas: molecular evidence for multicentricity. Pathol Int 1998; 48(11): 869-76.
-
- Geliş Tarihi:** 15.11.2002
- Yazışma Adresi:** Dr.Arif Osman TOKAT
Sağlık Bakanlığı Ankara Eğitim ve
Araştırma Hastanesi ANKARA
ademgungor@goguscerrahi.com